Biology 1120 and 1220

Anatomy and Physiology Laboratory Manual

Gordon McIntyre

6th Edition

Biology 1120 and 1220

Anatomy and Physiology Laboratory Manual

with additional appendices

Gordon McIntyre

Vancouver Community College

Broadway Campus

6th Edition. Copyright June 2021

Table of Contents

Table of Contents i

List of Figures vii

List of Tables viii

Introduction ix

Biology 1120 Laboratory Exercises

Laboratory Exercise 1: Anatomical Orientation and Terminology 1

Laboratory Exercise 2: Microscopy 7
Basics of Microscope Use and Care: 7

Laboratory Exercise 3: Cell Structure 18
Oil Immersion 18
Microscopic Material 18
Slides 19

Laboratory Exercise 4: Mitosis 28

Laboratory Exercise 5: Histology 30

Laboratory Exercise 6: Brain Dissection 37
General notes on dissections 37
Surface Anatomy of the Brain 38
Examination of Cranial Nerves 38
Dissection for Internal Brain Anatomy 40

Laboratory Exercise 7: Reactions and Reflexes 43
Part I: Reflexes.....43
Part II: Measuring reaction times with a reaction ruler 45
Notes regarding the laboratory report 47

Laboratory Exercise 8: Eye Dissection 49

Laboratory Exercise 9: Special and General Senses 55
Visual Acuity 55
Astigmatism 56
Eye Dominance 56
Visual Mapping.....57
Peripheral Vision 58
Lens Accommodation 59
Proprioception.....59
Touch Sensitivity 60
Taste Sensitivity and Smell.....61
Olfaction, Taste and Trigeminal Involvement 61

Laboratory Exercise 10: Hearing and Balance..... 62
A. Balance.....62
B. Hearing 63
Notes regarding the laboratory report 66

Laboratory Exercise 11: Rat Dissection 68
General notes on dissection 68
Surface Anatomy of the Rat.....69
Endocrine System 69
Reproductive System 70

Laboratory Exercise 12: Embryology..... 75

Biology 1220 Laboratory Exercises

Laboratory Exercise 1: Skeletal Anatomy and Terminology..... 79
Part I: Terminology.....79
Part II: Becoming familiar with the major bones.....80
Part III: Joints.....86
Part IV: Building a Body 88

Laboratory Exercise 2: Muscle Anatomy and Terminology 89
Part I: Naming and Terminology 89
Part II: Becoming familiar with the major muscle groups.....92
Part III: Applications.....97

Laboratory Exercise 3: Respiratory Physiology..... 99
A. Determining Resting Respiratory Rate 101
B. Determining Peak Flow Rate 102
C. Determining Respiratory Volumes.....102

Laboratory Exercise 4: Respiratory Chemistry 109
Preparing and Using the Apparatus 109

Laboratory Exercise 5: Cardiovascular Anatomy 111
A. Blood Vessel Anatomy 111
B. Major Blood Vessels of the Human Body 112
C. Blood Cell Anatomy and Physiology.....113
D. Anatomy of the Heart.....117

Laboratory Exercise 6: Exercise Physiology..... 121
Safety Procedures.....121
Techniques 121
Experimental Procedures 125
A. Sitting.....125
B. Reclining 125
C. Standing.....126
D. Exercise.....127
Notes regarding the laboratory report 130

Laboratory Exercise 7: Haematology 133
Safety Procedures.....133
Experimental Procedures 134
A. Red Blood Cell Count.....134
B. White Blood Cell Count.....139
C. Haematocrit Measurement 143
D. The Differential White Cell Count.....145
Notes for the Haematology Lab Report 148

Laboratory Exercise 8: Blood Typing..... 150
Safety Procedures.....151
Experimental Procedures 151

Laboratory Exercise 9: Digestion..... 154
Tests for Fats.....154
A. The Emulsifying Properties of Bile Salts.....154
B. Digestion of Milk Fats by Pancreatic Lipase 155
C. Testing the Nutrient Contents of Unknown Food Stuffs.....157
Grease Test for Lipids.....157
Test for Starch.....157
Tests for Sugars.....158
Test for Proteins.....160

Laboratory Exercise 10: Kidney Dissection..... 161

Laboratory Exercise 11: Urinalysis 164
Specimen Collection 164
Basic Observations.....165
Chemical testing.....166
Specimen Preparation and Microscopic Examination 168

Laboratory Exercise 12: Foetal Pig Dissection 173
General notes on dissection 173
Surface Anatomy of the Pig.....174
Internal Anatomy of the Pig.....175

Appendices **182**

Biology 1120: Drug Effects Research Essay **183**
Marking Guide for Drug Effects Research Essay 185

Biology 1220: Pathology Research Essay **186**
Marking Guide for Pathology Research Essay 188

Writing A Scientific Report **189**
1. Cover Page: 189
2. Abstract: 189
3. Introduction: 189
4. Materials and Methods: 190
5. Results: 190
6. Discussion: 191
7. Reference List: 191

How to Cite Literature and List References **193**

Biology 1120 Learning Objectives – Chemistry, Cytology, Histology, Orientation **199**

Biology 1120 Learning Objectives – Nervous System and Senses **201**

Biology 1120 Learning Objectives – Endocrine System, Reproduction and Development **203**

Biology 1220 Learning Objectives – Integumentary, Muscular and Skeletal Systems **205**

Biology 1220 Learning Objectives – Respiratory, Cardiovascular and Lymphatic Systems, Immunity **207**

Biology 1220 Learning Objectives – Digestion, Nutrition, Metabolism, Excretion and Homeostasis **209**

Laboratory Safety: Guidelines and Procedures 211
General Principles:.....211
The lab is a busy space which is often crowded. Anything that causes distraction, impairs movement or can spill or fall can produce a dangerous situation. We all need to work to minimise these dangers. 211
Safety Equipment:.....211
Safety Procedures for Human Tissues (Blood, Urine or Epithelial Cells) 212
Do's and Don'ts for the Lab.....213

List of Figures

Figure 1..Three major anatomical planes of reference. 3
Figure 2. The four quadrants of the abdominal region 4
Figure 3. The nine regions of the abdomen 4
Figure 4. Parts of a Compound Light Microscope..... 8
Figure 5. Parts of a Dissecting Microscope. 17
Figure 6. Photomicrograph showing smooth endoplasmic reticulum 20
Figure 7. Photomicrograph showing the Golgi apparatus. 21
Figure 8. Photomicrograph showing stained mitochondria. 22
Figure 9. Photomicrograph showing Kupffer cells from a liver section..... 23
Figure 10. Photomicrograph showing a cross-section of the intestinal epithelium. 24
Figure 11. Fish Blastula with cells in mitosis 26
Figure 12. Ascaris cells showing centrioles..... 27
Figure 13. Example photomicrograph showing plant root mitotic cells..... 29
Figure 14. Cross-sectional anatomy of the trachea, showing different tissues 34
Figure 15. Ventral view of the human brain showing some of the cranial nerves 39
Figure 16. Midsagittal view of the human brain showing anatomical features 41
Figure 17. The muscles of the eye in a laterally viewed sagittal section..... 50
Figure 18. The anatomy of the human eye, in a sagittal section..... 51
Figure 19. Detailed view of the attachments of the lens..... 53
Figure 20. Male reproductive structures of a rat..... 71
Figure 21. Female reproductive structures of a rat. 72
Figure 22. Female reproductive structures of a pregnant rat. 73
Figure 23. Whole mount of a chick embryo at a development age of 16 hours 76
Figure 24. Whole mount of a chick embryo at a development age of 33 hours 76
Figure 25. Whole mount of a chick embryo at a development age of 48 hours 77
Figure 26. Whole mount of a chick embryo at a development age of 72 hours 78
Figure 27. The external anatomy of the heart 118
Figure 28. Some features of the internal anatomy of a sheep heart 119
Figure 29. A Nebauer Haemocytometer showing major components 135
Figure 30. Erythrocyte Diluting Pipettes 136
Figure 31. A Nebauer Haemocytometer 137
Figure 32. The leukocytes, erythrocytes and platelets in human blood smear 140
Figure 34. Procedures for making a blood smear slide..... 146
Figure 35. Diagram showing pattern for a differential white blood cell count..... 147
Figure 36. Illustration of Blood Type Reactions 155
Figure 37. A bisected kidney showing gross anatomical structures 162
Figure 38. Examples of casts in urine..... 170
Figure 39. Some crystals that can be found in urine sediments..... 171
Figure 40. The incisions for dissection of a foetal pig..... 176

List of Tables

Table 1. Size of one unit on an ocular micrometer scale for a Zeiss microscope..... 13
Table 2. List of Additional Histology Slides for the Histology Lab..... 35
Table 3. Ability to Focus on Near Objects as an Approximate Analog to Age..... 59
Table 4. Resting Respiratory Rates from Class Activity 101
Table 5. Peak Flow Rates from Class Activity 102
Table 6. Correction Factors for Spirometer Volumes to Body Temperature. 103
Table 7. Tidal Volumes from Class Activity 104
Table 8. Resting Respiratory Minute Volumes from Class Activity 105
Table 9. Expiratory Reserve Volumes from Class Activity 105
Table 10. Inspiratory Reserve Volumes from Class Activity 106
Table 11. Vital Capacities calculated from Class Activity 107
Table 12. Age Adjustment Factors for Estimating Residual and Total Lung Volumes 118
Table 13. Cardiovascular and Respiratory Measurements from Postural Activities. 126
Table 14. Cardiovascular and Respiratory Measurements from Differing Exercise 112
Table 15. Red Blood Cell counts using a haemocytometer 139
Table 16. White blood cell counts obtained using a haemocytometer 143
Table 17. Haematocrit and buffy coat of sheep blood. 144
Table 18. Differential white blood cell counts on normal and pathological blood..... 147
Table 19. Agglutination patterns of the common human blood types 153
Table 20. Effects of Bile Salts on Miscibility of Oil and Water..... 155
Table 21. Materials required for Fat Digestion Tests 155
Table 22. Colours Produced by Universal Indicator Solution at Differing pH Levels.. 156
Table 23. Colour observations from digestion tests of milk fat by pancreatic lipase.... 156
Table 24. Summary of results of milk fat digestion tests 156
Table 25. Results from Grease Testing for Lipids 157
Table 26. Results from Iodine Testing for Starch..... 158
Table 27. Results from Benedict's Testing for Reducing Sugars 159
Table 28. Results from Seliwanoff's Testing of Foodstuffs for Ketose Sugars 160
Table 29. Results from Biuret Testing of Foodstuffs for Protein 160
Table 30. Results from Chemical Testing of Urine Samples..... 166
Table 31. Results from Microscopic Examination of Urine Samples. 172

Introduction

Welcome to Biology 1120 and 1220, which comprise a first year University level course in Anatomy and Physiology. This laboratory manual is very much an ongoing work. I wrote this manual for the curriculum I teach, so your instructor may not use all of the material in this book or may add different material. New information and new laboratory exercises are still being developed, so there may be handouts or other changes to the material in this guide.

There are a wide variety of materials in this manual, including some classic anatomy and a number of physiological investigations. None of the labs involve live animals (except of course you and your fellow students). We decided to minimize some of the more unpleasant components that anatomy and physiology courses traditionally included. There will still be dissections required, but only of prepared specimens.

Pay close attention to the information on writing up laboratory reports and citing sources of information. Your instructor will have additional information for you on assignment formats, but you should assume that any laboratory reports will require all of the sections described in the reports section of this manual. In addition to that information, the individual labs include notes about specific information needed for some of the sections of the lab reports. Don't assume that if there aren't specific notes about a section of a lab write-up that those sections don't need to be written. Each lab will have all of the sections of a typical lab report.

Above all, enjoy the course while you learn the material.

Gordon McIntyre

Biology 1120

Laboratory Exercise 1: Anatomical Orientation and Terminology

Work in groups of about 3 or 4, using the human models, skeletons and text diagrams to answer the following questions. Ask each other (including other groups) for help in locating any of the structures that you are unfamiliar with or can't locate.

Orientation terminology, like much of the vocabulary in anatomy and physiology, has originated around the world and from multiple fields of study. In particular, human medicine and zoology have both contributed to the terms commonly used to describe the body. This can cause problems, as many zoological terms were developed to describe animals that aren't bipedal (upright stance) like humans. The result is that the same term can mean different things in different situations. For instance, in zoology, anterior refers to a direction or position towards the front or head end of an animal, while in human anatomy it only refers to the front side of the body. Cranial and caudal mean towards the head or tail, respectively, in both sets of terminology. Superior and inferior refer to higher and lower in both formats. Supine and prone can be confusing as well. Supine typically refers to lying on one's back, while prone is lying belly side down. When referring to the arms, however, the problem is determining which way the arms should be turned. The anatomical position was developed to solve this problem. In this position, the palms of the hands should point to the anterior surface of the body, so that the palmar surface is forward. In the foot, supination has come to describe a complex outward rolling of the foot during walking. It is comprised of multiple changes in orientation. Instead, it is most common to describe foot orientation and bending by dorsiflexion (moving the toes in a superior directions) or plantarflexion (pointing the toes downward).

Use the terms you are learning about to answer the following questions:

A. Assume the anatomical position and describe to your fellow group members how it is defined.

B. Use each of the directional terms once to complete these statements.

Directional terms to use: medial, lateral, distal, proximal, cranial, caudal, contralateral, ipsilateral, superficial, deep, dorsal, ventral.

1. The lungs are _____ to the heart.
2. The knee is _____ to the hip.
3. The thumb is _____ to the little finger (5th digit) when the hand is in pronation.
4. The pancreas (upper left quadrant) is _____ to the left arm.
5. The skin is _____ to the muscles.
6. The nose is _____ to the ears.
7. The brachium (upper arm) is _____ to the elbow.
8. The appendix (lower right quadrant) is _____ to the stomach (upper left quadrant).
9. The kidneys are _____ to the intestines.
10. The stomach is _____ to the anus.
11. The heart is _____ compared to the ribs.
12. The crus (leg) is _____ to the buttocks.

C. Some of the following statements are correct, but others don't quite make the grade. Place an X beside the statements that contain errors.

___ The armpit is medial to the breast.

___ The eyes are lateral to the nose.

___ The gallbladder and the ascending colon are ipsilateral.

___ The ascending and descending colons are contralateral.

___ The brain is deep to the skull.

___ The lungs are superficial to the ribs.

___ The wrist is proximal to the hand.

___ The ankle is distal to the foot.

___ The ovaries are posterior to the intestines.

___ The breasts are on the ventral surface of the thorax.

___ The thorax is superior to the abdomen.

___ The diaphragm is inferior to the abdomen.

D. On the following diagram, label the 3 most frequently used planes.



Figure 1. Three major anatomical planes of reference (Saladin, 2007).

E. Label the 4 abdominal quadrants and 9 abdominal regions on these diagrams. Ignore the blank label lines as they are remnants from the textbook images.

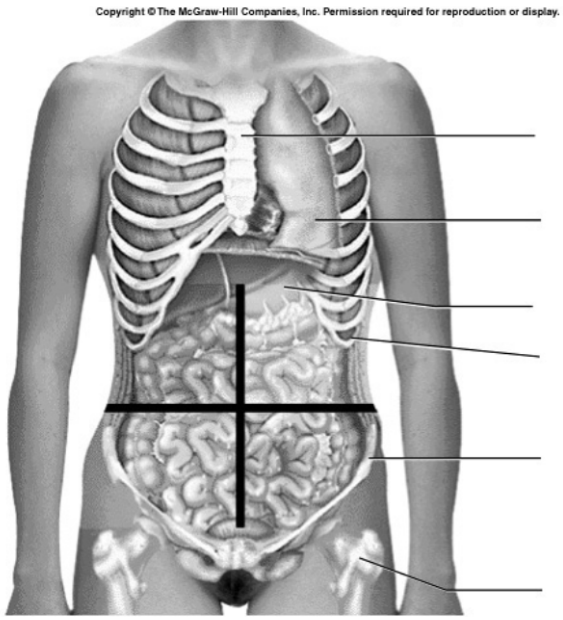

Figure 2. The four quadrants of the abdominal region (Saladin, 2004).

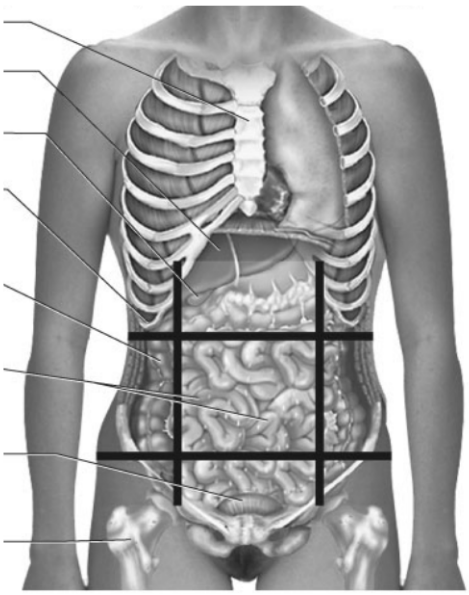

Figure 3. The nine regions of the abdomen (Saladin, 2004).

F. Identify the quadrant(s) and region(s) in which you are most likely to find the following structures. Simply identifying the area in which the majority of the structure is located is good enough.

	Quadrant(s)	Region(s)
Stomach	_____	_____
Appendix	_____	_____
Left kidney	_____	_____
Right ovary	_____	_____
Ascending colon	_____	_____
Urinary bladder	_____	_____
Hiatus	_____	_____
Gallbladder	_____	_____

G. Identify the body cavity (dorsal - cranial and vertebral, ventral - thoracic, abdominal and pelvic) in which you would find the following structures. Try to locate the structures themselves on the human models or on diagrams in your texts.

Small intestine _____

Oesophagus _____

Rectum _____

Caecum _____

Lung _____

Hypothalamus _____

Trachea _____

Urethra _____

Spinal cord _____

H. Dental Orientation Terminology

You have learned that terminology from medicine and zoology have differences, primarily due to the differences between quadrupeds (four-footed animals) that are the source of many of the zoological terms such as cranial versus caudal and bipeds (upright animals such as humans) that are the source for medical terminology such as superior versus inferior. Dorsal and ventral and anterior and posterior also have differences in zoological and medical terminology.

Similarly, dental terminology has arisen with its own specifics that may be different from either of the first two sources of orientation terms. Some examples include distal and mesial. In normal anatomical terminology, distal is the opposing term to proximal and means further from the origin of an appendage. In dental terminology, distal and mesial refer to distance from the centre front of the teeth. The wisdom teeth (third molars) are the most distal teeth and the central incisors are the most mesial. Normally, the apex is the highest point of an object, but in dental terms, apical means closer to the bottom tips of the tooth roots and contrasts with coronal, where here coronal means towards the crown or top of the tooth.

Other orientation terms include buccal, which means the surfaces of teeth and other structures facing the cheek, as compared to lingual or palatal which refers to surfaces facing inwards to the tongue (bottom jaw – mandible) and palate (upper jaw – maxilla). Similarly, labial can be used for the forward-facing surfaces, pointing towards the lips. Incisal means towards the biting edge of anterior teeth such as incisors, while occlusal is used similarly for the posterior teeth such as molars. Gingival refers to movements towards the gum line.

Use the terms above to describe the following dental objects:

The anterior side of a bottom right molar _____

The left-hand side of an upper left bicuspid (premolar) _____

The gums and jaw surfaces on the bottom left facing the tongue _____

The gums and jaw surfaces on the upper left facing the tongue _____

A cavity on the biting surface of the upper left second molar _____

The location of a premolar compared to a canine tooth _____

The location of an incisor compared to a canine tooth _____

A chip out of the top edge of a bottom left incisor _____

The bottom of a molar root _____

Biology 1120

Laboratory Exercise 2: Microscopy

Work in groups of 2 to 4, using the Zeiss compound microscopes. Read the handout on microscope care that you are given. The scopes are delicate and expensive.

Basics of Microscope Use and Care:

- Always carry the scopes with two hands: one on the arm and one on the base. They are heavy and expensive.
- Make sure the low power objective lens is in place (facing the stage) before you start. Larger lenses could hit the stage and cause damage.
- Rotate the objective lenses by the bezel ring only, never by the lens itself. Grabbing the lens could damage its seating and destroy the focus of the scope permanently.
- When you rotate the objective lenses, watch from the side to ensure they will not hit the slide or the stage.
- Do not wipe microscope surfaces with anything except a Kimwipe or lens paper. Other materials can scratch the fragile optical coating.
- Keep both eyes open and relaxed. Anything else will produce headaches. If the view from one of your eyes seems blurry, use the diopter adjustments to correct the focus for the microscope. The default setting should have the diopter set to the white dot. Adjust the width between eyepieces to a comfortable width.
- When you replace the microscopes in the cupboard, loosely coil the power cords and attach them using the Velcro strips.
- Cover the microscope with its dust cover before you put it back in the cupboard, ensuring that the low power objective lens is facing the stage.
- Do not place the scopes too close to the edge of the desk and do not let power cords dangle over walkways
- Try to place the microscope at a comfortable ergonomic height. We have phone books in the front cupboard that you can use to adjust the heights.

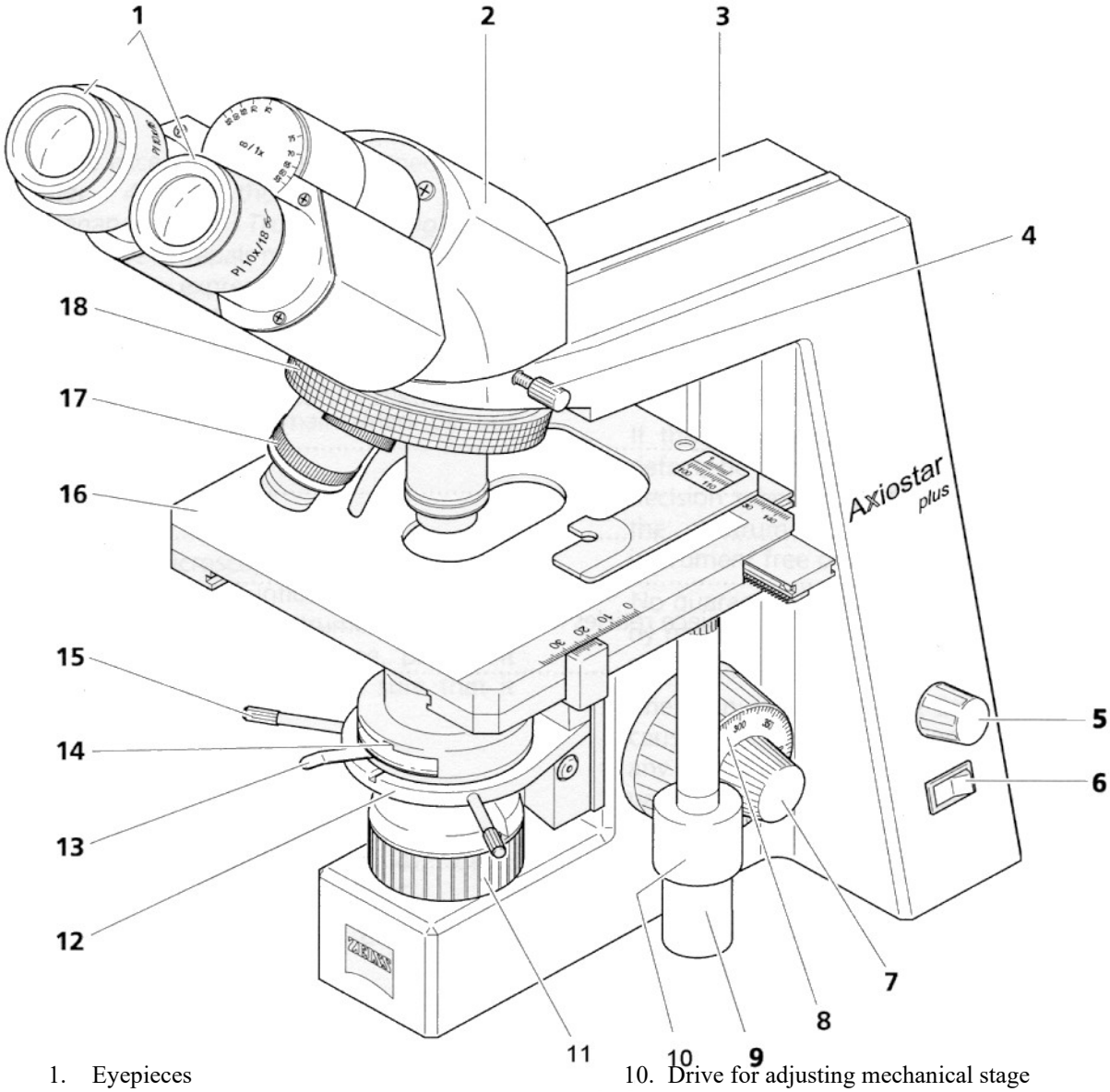

1. Eyepieces
2. Binocular tube
3. Microscope stand or arm
4. Knurled screw for tube locking
5. Brightness control
6. On/off switch with integrated signal lamp
7. Fine focusing drive (two-way)
8. Coarse focusing drive (two-way)
9. Drive for adjusting mechanical stage slide clip in X direction
10. Drive for adjusting mechanical stage slide clip in y direction
11. Luminous field diaphragm
12. Condenser carrier
13. Lever for adjusting iris diaphragm
14. Condenser
15. Centering screw for condenser (two-way)
16. Mechanical stage with specimen holder (slide clip)
17. Objective
18. 4-positions nosepiece

Figure 4. Parts of a Compound Light Microscope. This picture is of the Zeiss Axiostar plus model, but the parts will be similar for many common brands.

A. Preparing a wet mount slide.

Use a small piece of algae (one cell thick is the best - you should be able to see through it with your naked eye) or other specimen as provided in class. Add one drop of water directly onto the specimen. Lower a cover slip gently onto the slide from one side. Bring the cover slip into contact with the water, then gradually ease the slip onto the specimen to reduce air bubbles. If water escapes from the cover slip use a small bit of paper to wick up the excess. Ensure that the bottom side of the cover slip is dry before placing the slide onto the microscope stage.

B. Initial set up and focus for a compound microscope.

Place your slide on the stage using the stage clips. Use the stage guides to place the specimen directly over the light source. Ensure that the low power objective lens is in position over the slide. Bring your specimen into focus with the coarse and then fine focussing knobs. The best way to do this is to raise the stage as close as possible to the specimen watching the objective lens all the time (and NOT looking into the oculars) to make sure that the lens does not run into the slide. Then rotate the focus knob to lower the stage while looking through the oculars to bring the specimen into focus (details are as sharp as they can be). If you are having difficulty with focussing, it can sometimes help to use the edge of the cover slip as an item to obtain a rough focus.

Keep the light fairly low for best viewing (about 30% of maximum is usually best). Once the slide is in focus at low power, you shouldn't need to use the coarse focus again, as all other objective lenses should also be in focus.

1. Which magnification has the largest field of view (visible area)?

2. Which magnification has the smallest depth of view (vertical region in focus at one time)?

3. Which magnification is best for locating objects on the slide? An efficient way to locate objects is to use the stage guides. Begin in one corner of the cover slip. Scroll across to the opposite side, then scroll up or down by one field of view. Scroll back across the cover slip to the opposite side. Continue this scrolling until you have viewed the entire cover slip.

C. Setting up a compound microscope for Köhler illumination

In order to get the best image possible from a compound light microscope, the light path needs to be set up properly. The procedure is called Köhler illumination after August Köhler, the man who invented it. Essentially, this involves adjusting the diaphragms and condensers to improve the focussing of light onto the stage. Proper Köhler illumination should provide an evenly lit bright image without glare and minimise heating of specimens. Ensure that <u>everyone</u> in your group can set up Köhler illumination. If your group does not have a Zeiss microscope, merge with one that does for part C.

To set up Köhler illumination:

1. Switch on the light. Place your specimen on the stage and use the low power objective lens to bring the slide into focus.

2. Rotate the medium power objective carefully into place and adjust the focus as necessary. Close the diaphragm on the base of the microscope as far as possible. This diaphragm adjusts the size of the illuminated field of view. At this point you want to see a sharply focussed hexagonal or octagonal shape in the centre of the field of view that has a purple or blue edge to it. The field around this shape should be evenly dark. If this is not the case you will need to adjust the condenser.

   a) If the octagon is blurred: Raise the condenser as far as you safely can by using the condenser focus knob underneath the stage. While looking through the ocular lenses, slowly lower the condenser. When the field of view (aperture) is at its smallest, the edges of the octagon should also be sharpest. Adjust the condenser focus to make the edges as sharp as possible. As well, the edges should be blue or purple tinged instead of orange or yellow (this colour around the opening is scattered light which needs to be minimised).

   b) If the octagon is not centred: When this happens, the condenser has been jarred from its central position. Ask one of the instructors to help with this adjustment as a mistake could damage the condenser.

   c) If the area around the octagon is not evenly dark: To reduce this glare, close down the diaphragm in the condenser (note that this is a second diaphragm, not the one you had previously closed) until all of the dark area outside of the silhouette is evenly dark.

3) Open up the field diaphragm on the base of the microscope until the edge of the diaphragm silhouette is outside the field of view.

4) Switch to the high-power objective lens and make any further refinements to the focus of the condenser.

D. Drawing objects under the microscope.

Biological illustration has a long history. A number of conventions have arisen to ensure scientific accuracy.

1. Shading is either left out, so that only outlines of objects are shown, or if included, are done only by stippling (individual dots) to keep the drawings clear.

2. Labels are printed and kept at a uniform size. Lines from a part of the drawing to that object should not cross and should be parallel to each other whenever possible.

3. Whenever possible, use a soft lead pencil for drawing.

4. Make your drawing large enough to include as much detail as you can see, typically at least a quarter or third of a page.

5. Unless otherwise instructed, draw only what you actually see, not what an illustration in a text or other source shows.

6. Keep your drawing to the left-hand side of the page to allow space on the right-hand side for labels.

7. Provide a caption for your drawing beneath your sketch.

8. Showing the magnification of the drawing or indicating the true size of the specimen is an essential component of the caption. We will calculate these items in the next section.

9. Objects viewed under a microscope are often drawn in a circle that represents the edges of the field of view, but this is not essential.

Draw and label what you see under your microscope as accurately as possible.



E. Calculating sizes and magnifications for specimens.

Calculations of this sort are usually best estimates unless some fairly expensive tools such as micrometers or haemocytometers are used. The most common way to calculate microscopic object sizes is to compare a specimen to an item of known size such as the field of view of the microscope. We can measure the field of view of the microscope with a ruler or a slide holding a metric scale.

The size of an object under the microscope is simply:

$$\text{Size of object} = \frac{\text{diameter of field of view (in } \mu\text{m)}}{\text{number of times object fits across field of view}}$$

Unless you are otherwise instructed, base your size estimates of objects on the longest measurement of the object.

The size of the field of view can be measured directly with a ruler or micrometer slide for low or medium power. For high power, the size of the field of view can be calculated based on the size at lower magnifications. As magnification increases, the field of view decreases. This is a simple linear relationship. If magnification increases tenfold, then the field of view shrinks tenfold. Thus, if we know the size of the field of view at any magnification, we can calculate it for others.

Some of the microscopes have ocular rulers or micrometers built into the eyepieces. These rulers have lines etched into the glass, but do not provide an absolute scale, since the objective lens can vary. While the use of a scale on the stage is still the most accurate means of measurement, the ocular scale can be useful. The following table provides approximate sizes of the scale for differing magnifications. Note that in this table 1 unit of the ocular scale is the distance from one number to the next on the scale (the scale goes from 0 to 10). There are also smaller subdivisions visible on the ruler, but the table provides the sizes for each major unit.

Table 1. Size of one unit on an ocular micrometer scale at various objective lens magnifications for a Zeiss microscope.

Objective lens magnification	Size of one unit (in □m).
5X	200
10X	100
40X	25
100X	10

Once we know the actual size of an object, we can calculate the magnification of a drawing of that same object. Measure the size of your drawing and convert the measurement into micrometers (□m). Divide the size of your drawing by the actual size of the object and you have the magnification of your drawing. For instance, if a drawing is 20 cm across, it is 200,000 □m. If the actual specimen was 50 □m in length, then the magnification of the drawing is 200,000 divided by 50, a magnification of 4000 times.

$$\text{Magnification of drawing} = \frac{\text{size of drawing (in } \mu\text{m)}}{\text{actual size of object (in } \mu\text{m)}}$$

Calculate the size of your drawing and include this measurement in the caption for your drawing.

Try the following problems in microscopic calculation. Note that the values in the questions may not be the same as for the microscopes you have used:

1. If the magnification of the objective lens is 40X and the ocular lens is 10X, what is the total magnification of the microscope image?

2. If the ocular lens is 10X and the objective lens is 100X (oil immersion), what is the total magnification?

3. The field of view at low power (50X magnification) is 3.6 cm by measurement. What is the size of the field of view in micrometers? What would be the size of the field of view at medium power (100X)?

4. The field of view at medium power (100X) is 1.75 cm by measurement. What would be the size of the field of view at high power (400X)? How big would the field of view be using the oil immersion lens (1000X)?

5. The field of view at medium power is 1.75 cm. You estimate that 7 objects can fit across the field of view. How big is the object?

6. The field of view at medium power is 1.75 cm. At high power, you estimate that 12 objects will fit across the field of view. How big is the object?

7. You estimate the size of an object as 150 micrometers. You produce a drawing that is 10 cm across. What is the magnification of your drawing?

8. You estimate the field of view as 3.6 cm at low power (50X). At high power (objective lens only = 40X) you estimate that 5 objects will span the field of view. You produce a drawing that is 27 cm across. What is the magnification of your drawing?

F. Staining specimens.

There are many ways of staining specimens to improve visibility of details. Some stains can be used with live specimens, while others work only with dead objects. Many stains are noxious chemicals that require special care to prevent damage. A few (such as picric acid) are even explosive if not used properly.

Some of the common stains are:

Crystal Violet - used for bacterial staining, plant chromatin and animal nerve tissue

Eosin - for showing blood cells and some cell components

Giemsa - for showing different types of white blood cells

Hematoxylin - for nucleus components

Methylene Blue - for bacteria, mitochondria and nerve cell components

Sudan Black - for fatty structures, golgi bodies, chromosomes and leukocyte grains

Wright Stain - for blood components.

Prepare a wet mount slide of your cheek cells by lightly rubbing the inside of your cheek with a toothpick. Smear the sample on a clean slide and place one drop of crystal violet or methylene blue onto the smear. Use a cover slip as usual. If there is too much stain, wick away the excess by holding a small scrap of absorbent paper to the edge of the cover slip. Draw what you see under the microscope.

G. Using a Dissecting Microscope.

The compound microscopes that we have been using so far are the best for viewing small, thin specimens such as we can mount on a microscope slide. In many instances, however, we will need to provide magnification of very large specimens such as dissected body parts or other specimens such as plants or animals. For these large, thick objects, a dissecting microscope (also known as a stereomicroscope) is the best bet. These are just variations on a standard compound light microscope. They have lower magnification levels but can accommodate large objects for viewing. Our dissecting microscopes are also from Zeiss.

Use of this microscope is fairly simple. Place an object on the insert plate. Since the stands for these microscopes are plastic and easily scratched, never place a metal dissecting tray on this stand. Only use a plastic tray.

Switch the light on by pressing the illumination control. You can determine how your object is lit by repeatedly pressing this control. It cycles through reflected light only (light comes from the source above the object), transmitted light only (light comes from below the object), both reflected and transmitted light, and no light (other than from the general surroundings). Choose whichever light mode works best for you. The plus and minus buttons will increase and decrease the intensity of the light sources.

Look through the eyepieces and adjust their separation to ensure you see a single image. With the magnification adjustment at the lowest power (8X), focus on the object using the focussing knob. Increase the magnification as required. The highest magnification is 32X.

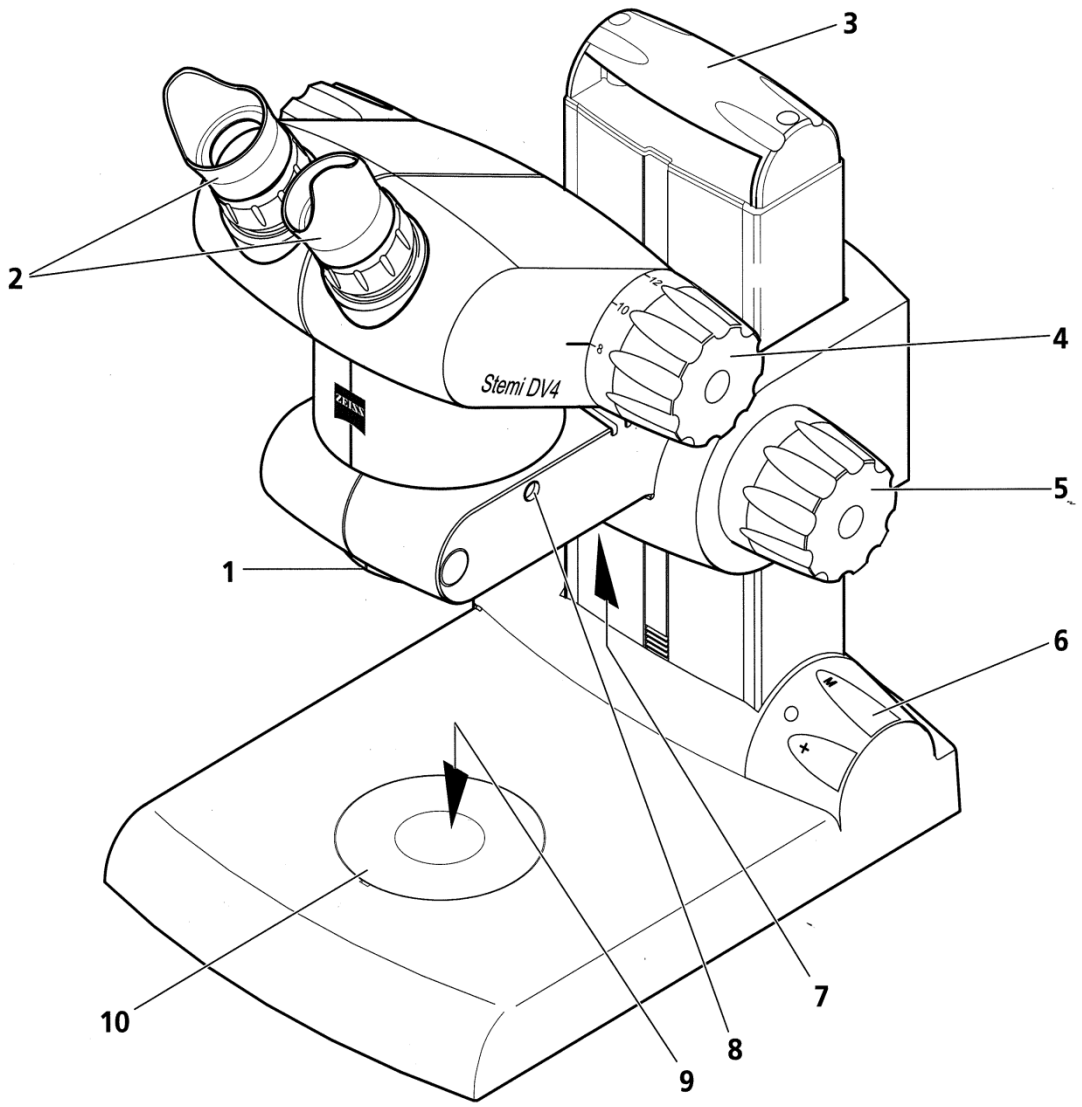

1. Connector for accessories
2. Eyepieces with folding eyecups
3. Carrier handle
4. Magnification adjustment
5. Focus knob
6. Illumination control
7. Reflected light illuminator
8. Clamping screw (anchors the head to the stand)
9. Transmitted light illuminator
10. Insert plate for object mounting

Figure 5. Parts of a Dissecting Microscope. The microscope in this diagram is a Zeiss model.

Biology 1120

Laboratory Exercise 3: Cell Structure

Work in groups of 3 or 4, using the Zeiss compound microscopes. There are only limited copies of most of the slides you will use today, so please do not monopolise them all. You do not have to work through the slides in the exact order that they are described in this lab.

Oil Immersion

Some of the material today may require the use of oil immersion lenses for best viewing. The procedures are very similar to what you experienced last week with the microscopy lab. If your microscope does not already have an oil immersion (100 power) lens attached, get one from the side of the room. Remove the cap covering the blank spot on the objective lens ring and screw the oil immersion lens into this spot. Focus and view a slide as before, but when you are ready for viewing with the oil immersion lens, rotate the lens out of perpendicular, then place a SMALL drop of immersion oil on the slide directly below the spot where the lens will sit. The lens must contact the oil to allow proper focusing. Examine the slide material as before, but make sure that no other lens contacts the oil. When you are done with the slide, remove it from the stage and clean it with a piece of lens paper to wipe up the excess oil. Use a small amount of alcohol to remove any remaining oil. Use this same procedure to clean off the oil immersion lens.

Microscopic Material

The material you will be examining today is meant to show you the diversity of cells and cell structures. You will see more evidence of cellular diversity when you carry out the histology lab in the near future. Unless otherwise noted, you will get the best detail using 400 power for viewing these slides. There are only a few instances when you will need oil immersion to gain the higher resolution to pick out fine structure. Sketch examples of each of the structures you can find. Label your sketches, including as many cell components as you can identify. Calculate the magnification of your drawings and include that value in the caption beneath each sketch.

Slides

Numbers after the slide descriptions are the serial numbers for the specific microscope slide. Each slide is prepared using a variety of staining techniques to highlight one or more specific cell component, such as a cell organelle. These structures are in bold type in the following descriptions. Some components on the slides are very easily detected but a few are more challenging. Read the descriptions for each slide to get some hints that will help you identify the various structures.

1. Generalised Animal Cell (93 W 2200)

This is a typical slide of an animal cell and will allow you to see the sort of structure that is typically visible, including the **cell membrane**, **nucleus** and **cytoplasm** and not much else.

2. Spinal Cord (93 W 2230)

This slide has been prepared to allow you to easily see the **nucleus**, **nucleolus** and **nuclear membrane**. The **cytoplasm** will contain a set of lines marked with dark dots. These are **ribosomes** attached to the **rough endoplasmic reticulum**. The rough E.R. will carry out the process of protein synthesis.

3. Adrenal Gland (93 W 4305)

There are a number of different cell types visible on this slide. The ones of interest today, are located in the adrenal cortex, the area near the outer surface of the sample. The outer surface will be the edge that appears intact. In this region of the gland, you should be able to see cells containing clear, hollowed out ellipses and circles in the cytoplasm. The structures you are seeing are the **smooth endoplasmic reticulum**. It is used to manufacture steroids in these cells.

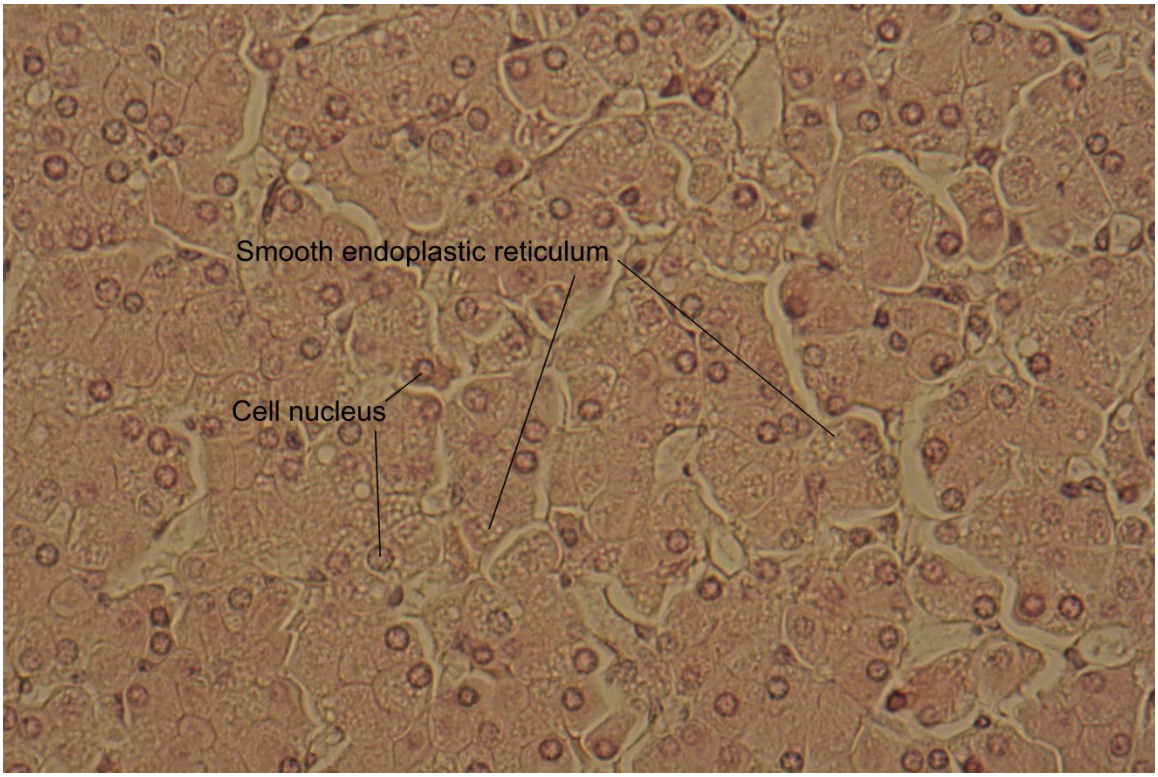

Figure 6. Photomicrograph of an adrenal gland showing the transparent –looking smooth endoplasmic reticulum in several cells and the darker cell nuclei.

4. Dorsal Root Ganglion (93 W 2221)

This slide is treated with silver stain that turns structures black. Again, there are a number of different cell types present. Look for the large, circular to cuboidal cells near the edge. There will be a hollowed-out appearance to these structures. When you find these cells, you will see black circles and ellipses in the cytoplasm near the nucleus. This is the **Golgi apparatus** that processes proteins for export from the cell. The proteins in this case may be neurotransmitters or other proteins.

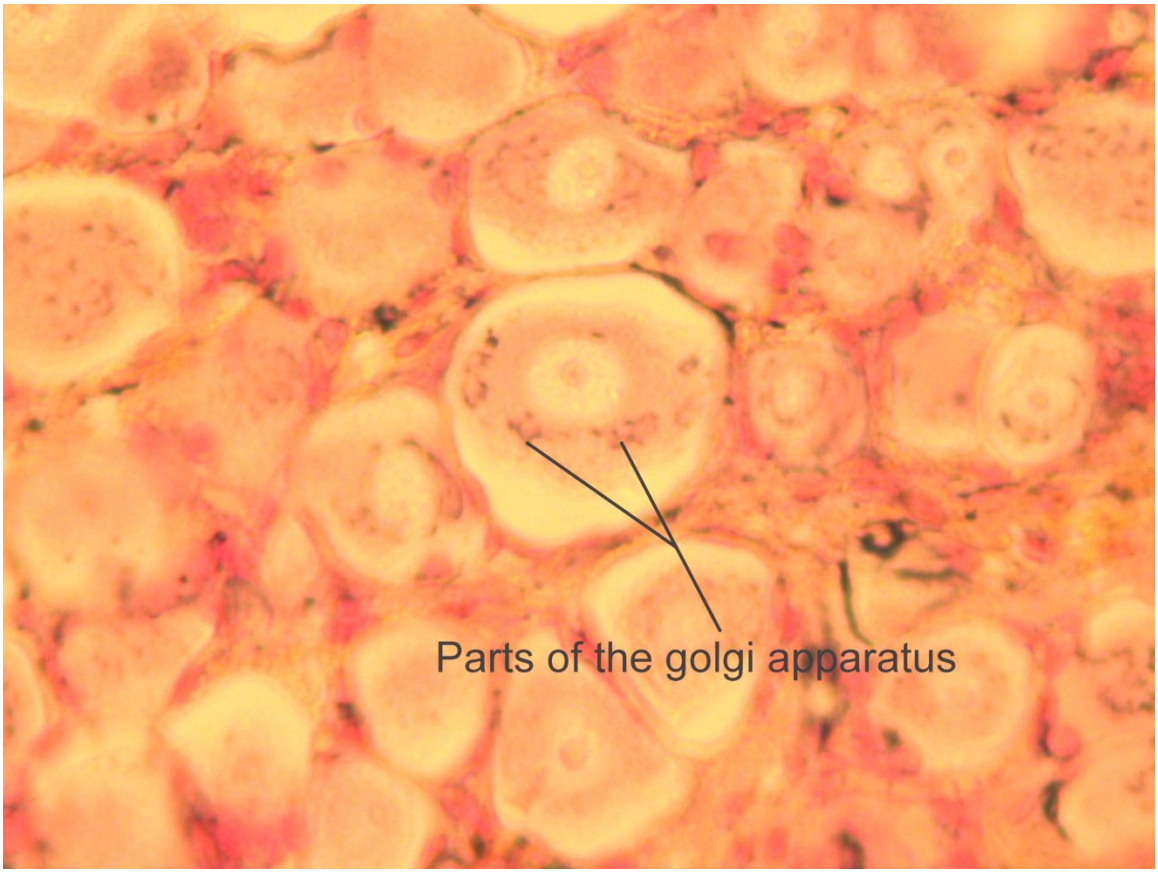

Figure 7. Photomicrograph of a sectioned dorsal root ganglion showing the Golgi apparatus near the nucleus of a cell.

5. Amphiuma liver (93 W 2215)

This cell shows the **mitochondria** very clearly. They will appear as dark blue, large organelles throughout the tissue although they seem to be more common at the periphery. Inside the mitochondria you should be able to see the **cristae** or membrane folds that are important in the chemical reactions that allow mitochondria to generate energy for the cell through cellular respiration.

6. Mammal liver (93 W 4562)

Look near the canaliculi or small channels in the tissue. The cells surrounding these channels will often contain dark purple circular organelles just smaller than the cell nuclei. The dark purple organelles are **lysosomes**, vesicles containing strong degradation enzymes that are used for digestion of materials.

7. Pancreas (93 W 4600)

Look at the large, purplish cells throughout the sample. In these cells you should see a nucleus as usual. You should also see large, clear circles of about the same size as the nucleus. These vesicles will most likely be lying just under the cell membrane. These are **exocytotic vesicles** containing pancreatic enzymes. Depending on the quality of your slide you may need oil to see these vesicles, as they are fairly small.

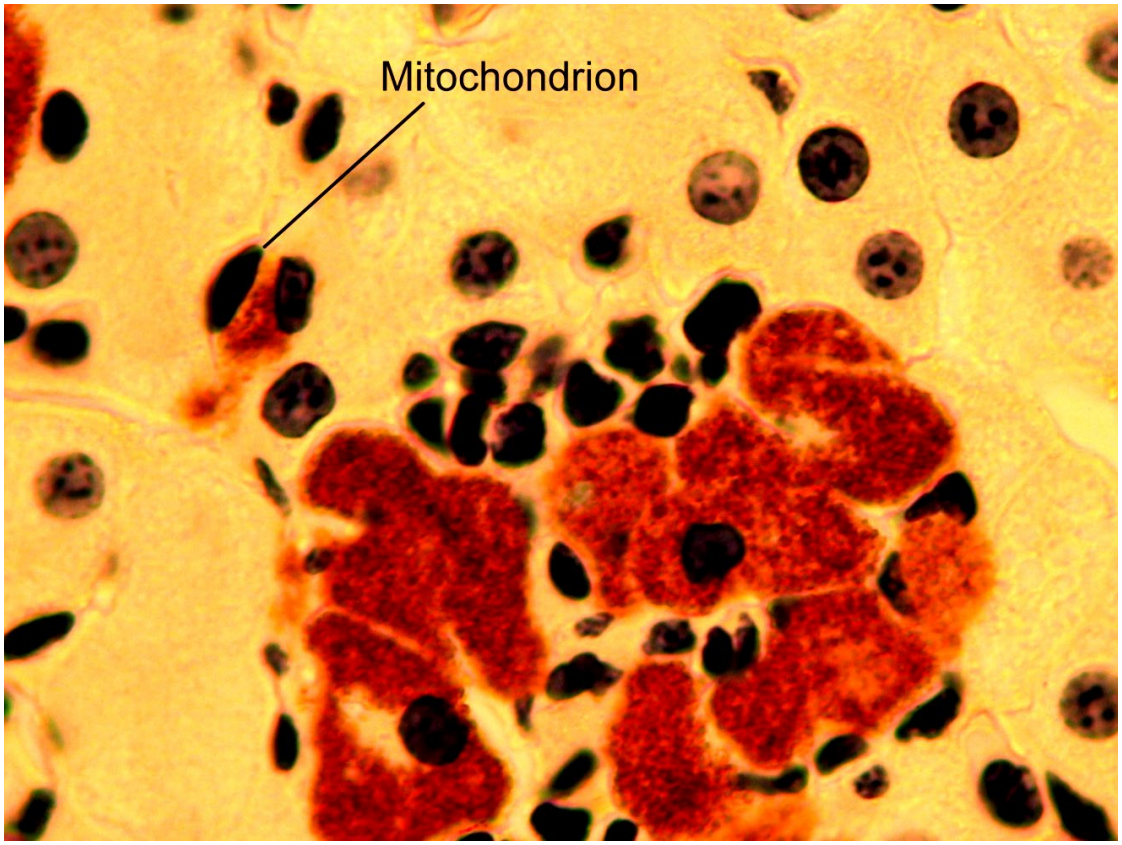

Figure 8. Photomicrograph of <u>Amphiuma</u> liver showing stained mitochondria.

8. Liver Macrophage (93 W 2238)

The structures that we are looking for in this slide are fairly hard to pick out. Look in areas known as the spaces of Disse: spaces or fissures between the typical hepatocytes (liver cells) that make up most of this tissue sample. In these breaks in the tissue, you will find a special type of immune cell known as a Kupffer cell. These cells will appear as large irregular cells with a clear to purple colour. They are a type of white blood cell known as a macrophage and their role is to engulf and destroy old and damaged erythrocytes or red blood cells. The engulfed erythrocytes are what we are looking for as this slide is demonstrating **endocytosis** and **endocytotic vesicles**. You are likely to need oil immersion to see this set of vesicles.

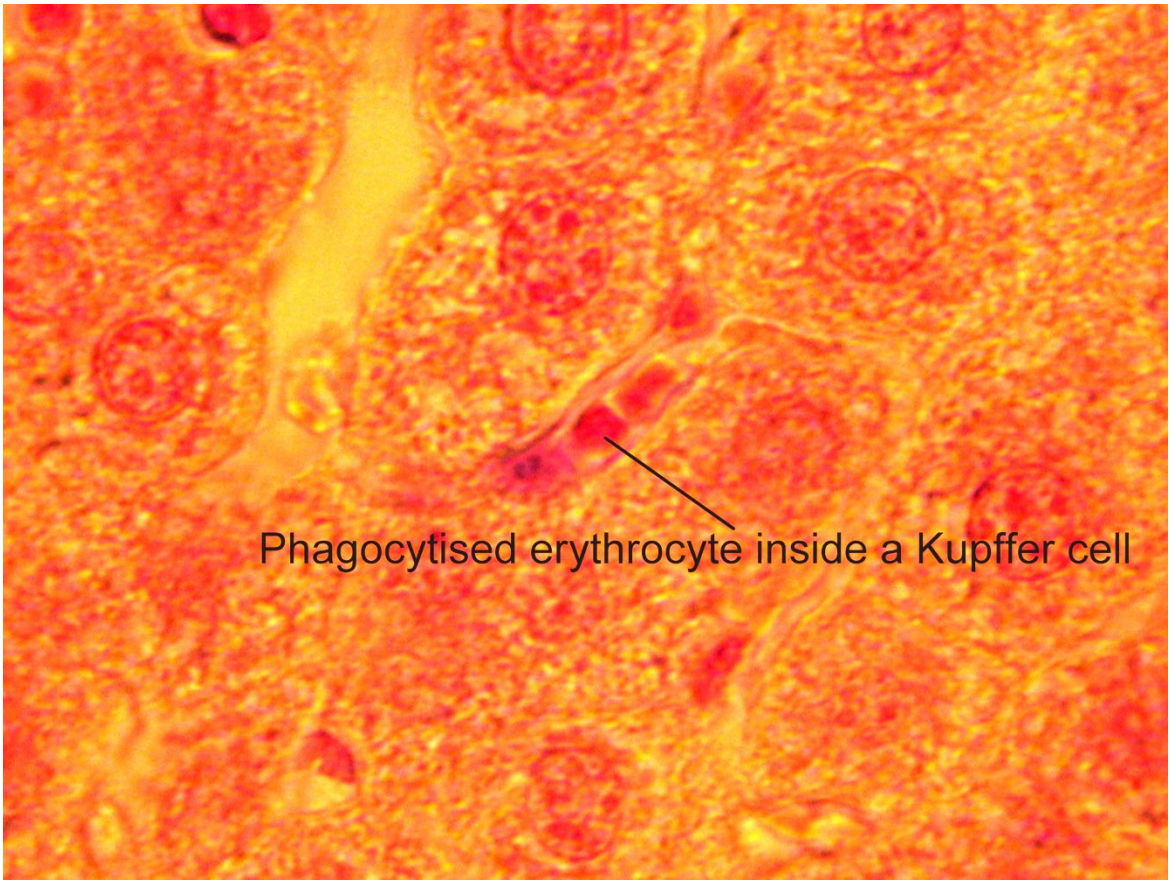

Figure 9. Photomicrograph showing Kupffer cells from a liver section.

9. Liver section with glycogen (93 W 2371)

The title of this slide describes what you are looking for. The **glycogen** will appear as bright pink inclusions in the hepatocytes that make up most of this tissue.

10. Ileum with Peyer's Patches (93 W 4534)

This slide shows a cross section through a portion of the small intestine. Look at the finger shaped projections that make up the inner surface of the intestinal tract. Note the plasma or **cell membrane**, and the **brush border** that is the inner edge of the tissue. It will appear as a thin line made of tiny columnar cells. These are the **microvilli** of the intestine. The microvilli greatly increase the surface area of the intestine, but they may appear only as a slight distortion of the edge of the cells. Interspersed with the normal epithelial cells lining the intestine, you will see some hollow looking cells. These are **goblet cells** that secrete materials necessary for digestive processes. At low power, you can see the Peyer's patches. They aren't terribly relevant to the lab today, but are important portions of the immune system. They are circular lymph nodules lying under the intestinal lining. They are one of the key sites for maturation of B lymphocytes. Of more relevance are the **desmosomes**. You will likely need oil immersion to see these structures. They will appear as dark patches joining two adjacent cells of the intestinal lining. They are a specialised form of cell junction that anchors cells strongly together.

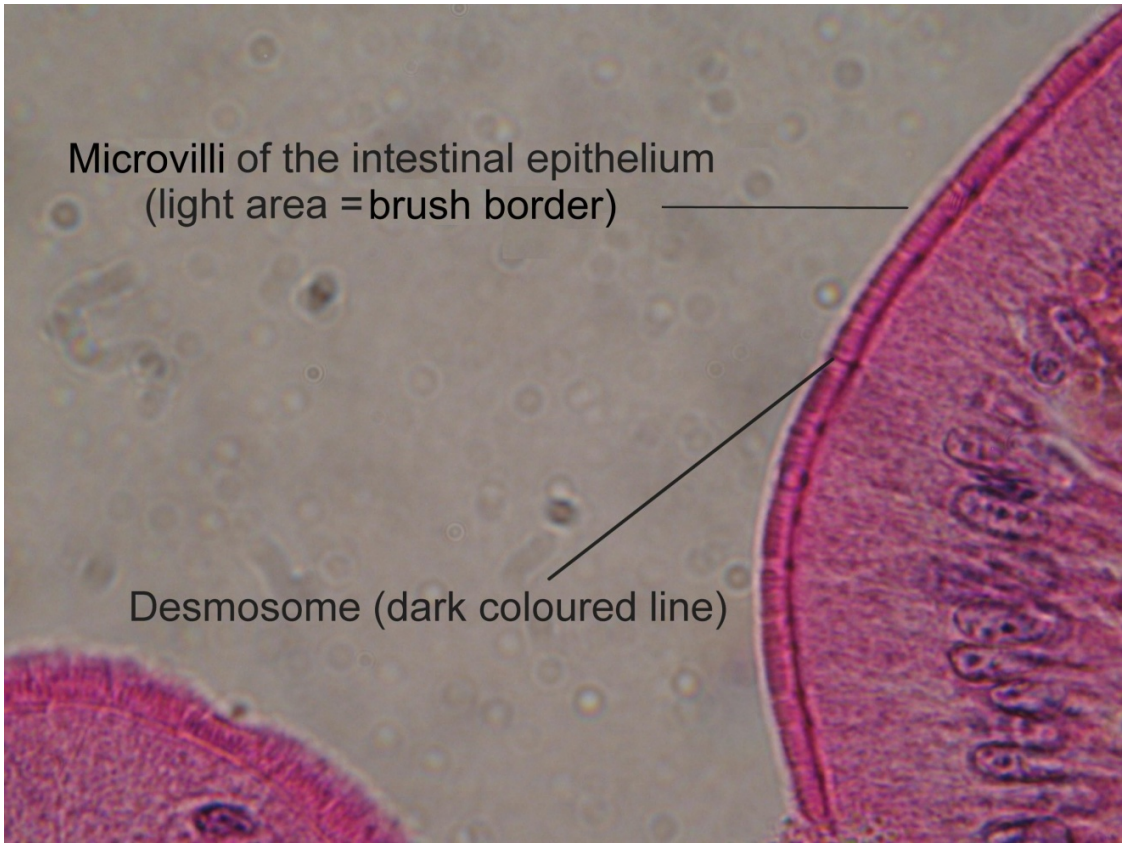

Figure 10. Photomicrograph showing a cross-section of the intestinal epithelium.

11. Pseudostratified ciliated columnar epithelium (93 W 3033)

In this slide, look for the columnar epithelial cells that will look very similar to the same type of cells in the intestinal slide above. These epithelial cells line the tracheal passage and are covered with **cilia** on the exposed ends. These are microscopic hair-like structures. The cilia here are more discretely apparent than the microvilli were in the intestine. Their function is to move debris for expulsion from the airways.

12. Heart (93 W 3530)

This slide is of cardiac muscle. The strands of muscle cells will show dark ragged lines between the cells. These are **intercalated discs**. These cell junctions consist of **desmosomes** and close or **gap junctions**. Gap junctions are a specialised means of joining cells that allow material to pass directly from one cell to the next, since they contain pores that allow transit. In the cardiac muscle they are important for the transmission of the electrical signals that provide a coordinated heart beat. You may need oil immersion for some of these slides.

13. Mammal kidney (93 W 5236)

This slide shows various components of the kidney. Look for circular structures that have cellular inclusions in the centre. These are glomeruli and surrounding tissues such as the Bowman's capsule. The epithelial cells that form these capsules have a bright pink layer lining the capsule. This **basement membrane** is an **extracellular matrix** produced by the overlying epithelial cells. These matrices are usually made of structural molecules such as carbohydrates and proteins.

14. Cerebellum anti-neurofilament (93 W 3743)

This slide shows the unipolar neurons quite clearly. There are strong brown filamentous inclusions that are components of **cytoskeleton**.

15. Frog sperm (93 W 8803)

This smear of frog sperm shows many spermatozoons. Most are broken but the flagella used to propel them are obvious. A few are still attached to the heads of the sperm. **Flagella** are produced from the **cytoskeleton** and protrude out through the cell membrane. Their anchors are internal. The energy to move them is provided by mitochondria.

16. Fish blastula (93 W 2240)

The blastula is an early developmental stage consisting of a hollow ball of cells. It is the developing embryo of a fish egg. This slide is showing a portion of a blastula. The cells are actively dividing during this developmental process, so the structures necessary for cell division are apparent. In some of the dividing cells, you can see the **mitotic spindle**, a **cytoskeletal** structure used to direct movement of the chromosomes during division. The slides we will see in the mitosis lab will also show these structures. Some of those slides will have better detail than the slides today. For the best chance to see the spindle fibres, look for cells in metaphase, a midpoint of cell division when all the chromosomes are lined up at the equator and the spindle extends clearly from the poles of the cell to the equator. The fibres of the mitotic spindle will appear as curved lines extending from each end of the cell and spreading out in the middle (much like the segment lines you can see on a pumpkin).

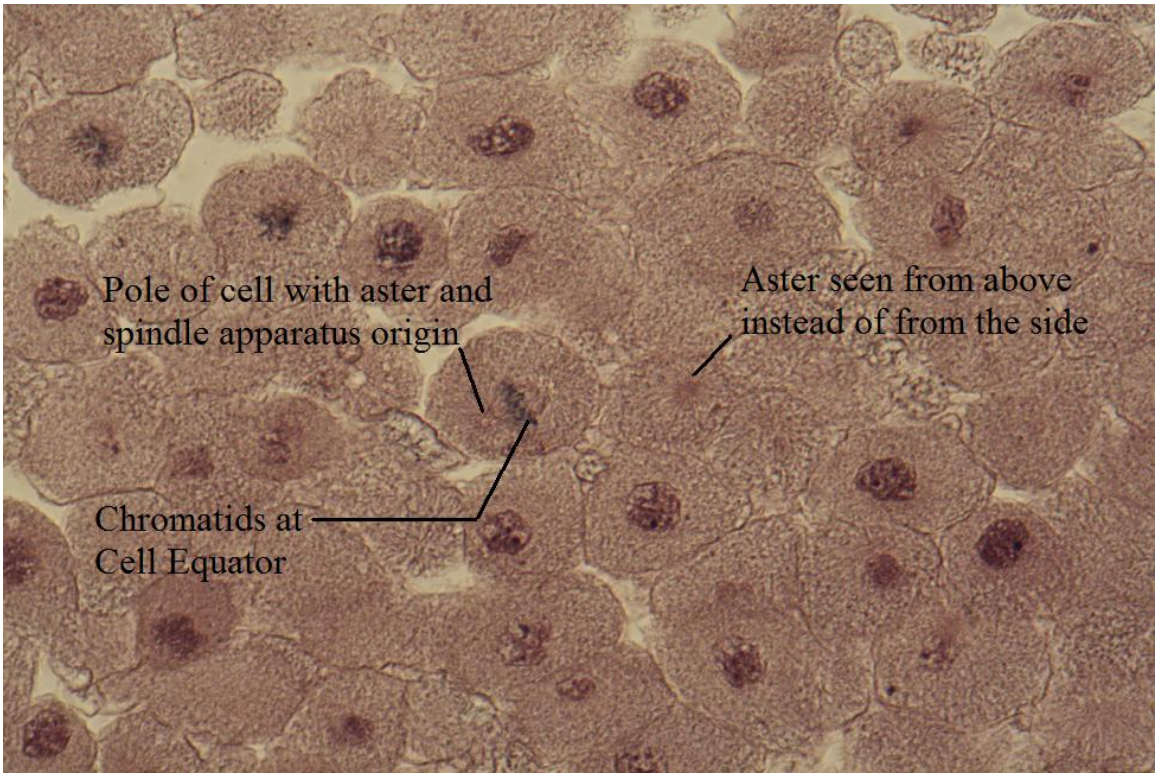

Figure 11. Fish Blastula with cells in mitosis. Labelled structures include a view of an aster from the pole down and one from the side. The side view has the aster protruding to the left and the main spindle fibres to the right.

17. Ascaris (93 W 2210)

This slide of actively dividing cells in a roundworm provides a glimpse of the **centrioles**. These structures help to control and regulate activity of the cytoskeleton. They can be somewhat difficult to view. Look for star-shaped structures near the poles of the cells. These are **asters**, which are extensions of the spindle fibres of the **mitotic spindle**. The centrioles will be at the centres of these asters. Oil immersion may help in locating these structures.

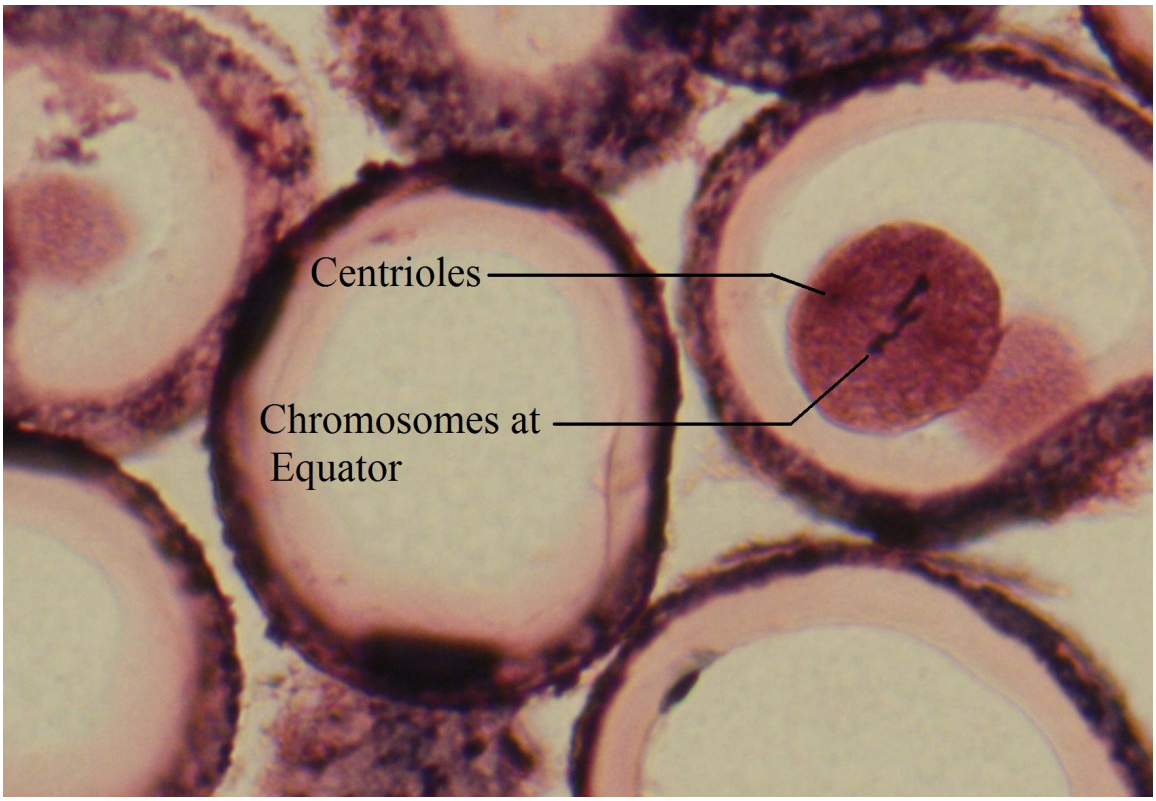

Figure 12. Ascaris cells showing centrioles (small dark structures at poles of cell) with spindle apparatus spanning the cell and chromatids lined up at the equator. Asters are also present but poorly visible.

Biology 1120

Laboratory Exercise 4: Mitosis

Work in groups of about 4, using the Zeiss compound microscopes.

Examine the slides of plant roots and whitefish blastula. Since these specimens were taken from rapidly growing material, a large proportion of the cells will be undergoing mitotic division. In the root sections, the areas around the perimeter and near the root tip are sites where mitotic cells will be tightly clustered. The blastula (an early embryonic developmental stage) will have mitotic cells in most regions. There will be minor differences between mitosis in the plant and animal cells. Animal cells will have asters (and centrioles, although these are unlikely to be visible in these specimens). Plant cells in cytokinesis (the actual division of the cell after mitosis) will have cell plates forming new cell wall at the equator, while animal cells will have cleavage furrows pinching off the equator of the cell.

Use the prepared slides to try to locate cells in each of the 4 mitotic stages, as well as cytokinesis. Compare the microscope specimens to the diagrams in your textbook to help identify the mitotic phases. Prophase cells will be characterised by condensed chromosomes scattered randomly through the central region of the cell. Nuclear membranes may or may not confine the chromosomes. Metaphase cells will have the chromosomes lined up at the equator. During anaphase, the chromosomes will have split, with the chromatids moving to opposite poles. Telophase, which tends to be more difficult to locate, has cells with chromatids clustered at opposite poles of the cell. Nuclear membranes may have reappeared. Finally, cells in cytokinesis will have strongly defined cleavage furrows in the whitefish, and cell plates along the equator in the plant roots.

Sketch examples of each of the stages you can find.

In addition to identifying the stages of cell division, contrast dividing cells with interphase cells. What differences do you see?

Label your sketches, including as many cell components as you can identify. Calculate the magnification of your drawings and include that value in the caption beneath each sketch.

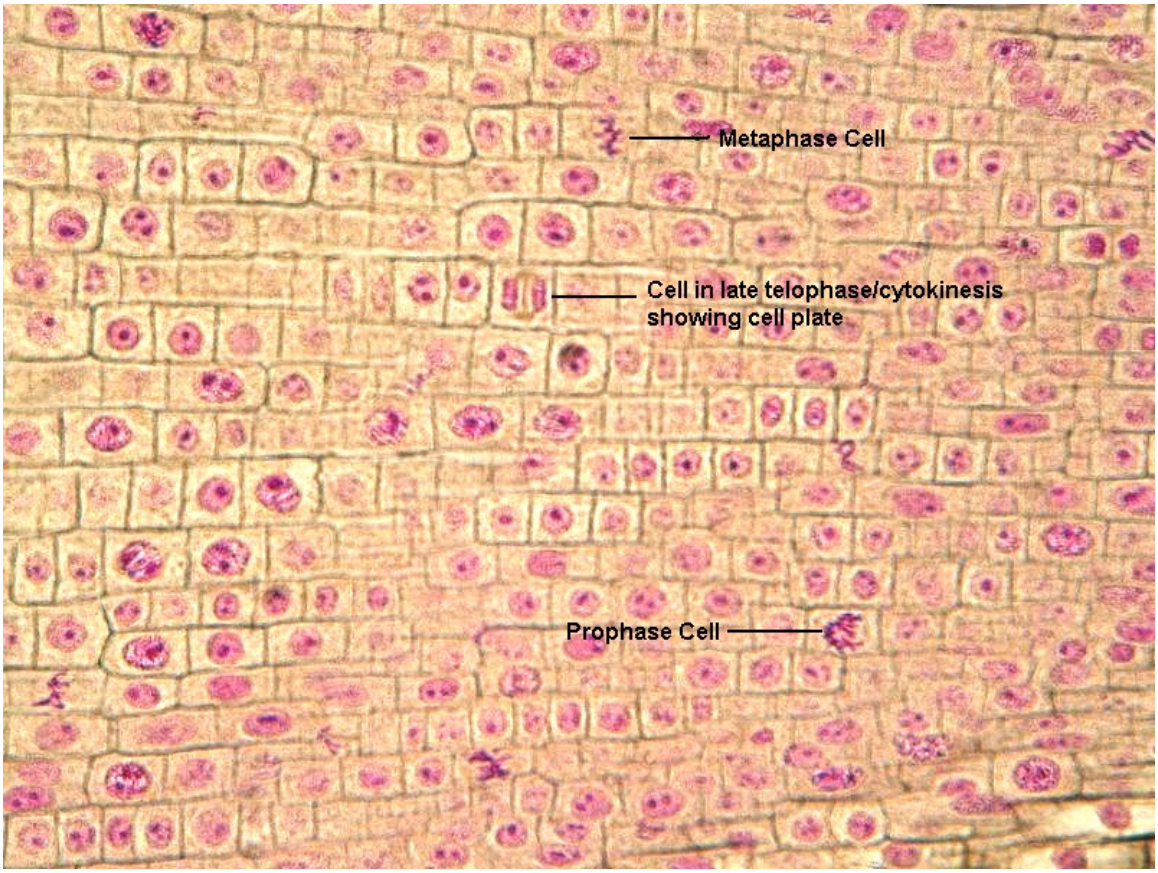

Figure 13. Example photomicrograph showing one field of view of cells from a plant root. Several mitotic cells are labelled, but various other cells in the image are also undergoing mitosis.

Biology 1120

Laboratory Exercise 5: Histology

Work in groups of about 4, using the Zeiss compound microscopes. Other resources will include your textbook (Chapter 5 in particular) and colouring book, as well as several atlases of histology which may be available in the room, or can be obtained from the VCC library.

Examine the prepared slides of animal tissues. Use these slides to try to locate examples of the differing tissue types and sub-types. Each group will be provided with a set of histology slides. The quality of prepared microslides has been a challenge lately, so if your slides seem poor, check with your instructors or other groups.

In addition to the set of prepared slides, there are a number of other slides available if your instructor wants to provide you with additional information. Note that on these additional trays of slides, a number of the slides will contain more than one tissue type. Ensure that you can distinguish the differences among these types. You should also note that a number of trays will contain slides that are not relevant to today's exercise. Use Table 2 to identify specific additional slides to look for, especially watching for slides with coloured stickers on them. We obtain new slides each year, though, so the table is not a complete list of slides of interest. The list in the table can provide some extra slides that may help you learn the characteristics of the tissues.

The following list shows some of the major groupings of tissues in the body. It does not include all sub-types but includes the important groups for you to know. Some of these tissues will be examined in more detail (blood, muscle and nervous tissue for instance) when we deal with the organ systems of the body.

Tissue types:	**Descriptions and example tissues in body:**
1) Epithelial tissue.	Covers and lines body structures
a) Squamous	flattened cells, few cells cover large areas

i)	Simple	blood vessel linings (endothelia), capillaries, serous membranes of digestive tract, lung alveoli, parts of loop of Henle
ii)	Stratified	mucous membranes of mouth, throat, rectum and vagina, skin surface
b) Cuboidal		intermediate shape (guess what, roughly cubic)
i)	Simple	thyroid gland, parts of kidney tubules
ii)	Stratified	ducts of sweat glands
iii)	Pseudostratified	
c) Columnar		tall, narrow cells, many cells in a small surface area
i)	Simple	intestinal lining, stomach lining, kidney collecting ducts
ii)	Pseudostratified	lining of nasal sinuses, bronchial lining
iii)	Stratified	ducts of salivary glands, urethra, mammary glands
2) Connective tissue.		provide support, connects body structures
a) Loose fibrous		much matrix, few cells and fibers
i)	Areolar	subcutaneous skin layers (hypodermis)
ii)	Adipose	subcutaneous skin layers (hypodermis)
iii)	Reticular	liver, spleen, lymph nodes, bone marrow
b) Dense		fibres are closely packed, little matrix
i)	Regular	tendons, ligaments, aponeuroses (tendon sheets)
ii)	Irregular	periosteum, perichondrium (coverings of bones and cartilage), nerve sheaths, portions of dermis
iii)	Elastic	blood vessel walls, elastic ligaments of spinal column

c) Fluid		fluid matrix, many cells, few or no fibres present
i)	Blood	plasma, leukocytes, erythrocytes, platelets, proteins
ii)	Lymph	interstitial fluid, leukocytes, chylomicrons (lipids from intestinal absorption)
d) Bone		osteocytes, matrix mostly of mineral salts,
i)	Compact	shafts of long bones
ii)	Spongy	ends of long bones
e)		Cartilage chondrocytes, matrix is a gel of derivative carbohydrates
i)	Elastic	ear pinna (flap), epiglottis
ii)	Hyaline	laryngeal supports, bronchial rings, sternum joints
iii)	Fibrocartilage	intervertebral disks, pads in some synovial joints
3) Muscle tissue		elongated cells able to undergo contraction
a) Skeletal		appendicular muscles
b) Smooth		blood vessel walls, digestive tract walls
c) Cardiac		heart
4) Nervous tissue		neurons and support cells of nervous system
a) Neurons		electrically stimulated, carry signals
i)	Motor	carry signals to muscles
ii)	Sensory	carry signals from sensory organs
iii)	Interneuron	central nervous system components
b) Glial cells		Schwann cells, astrocytes

Make sketches of the various tissues based on what you could distinguish using the microscopes.

Label your sketches, including as many structural components as you can identify. Calculate the magnification of your drawings and include that value in the caption beneath each sketch.

For each of the tissue types, include a description of the structure and functions of the substance with your sketch. The description should include:

- a listing of the distinguishing characteristics of the material
- important features that affect its activity
- locations in the body
- roles the tissue fulfils in the body
- common associations with other tissue types
- any further subdivisions of the tissue (e.g., components of blood, glial cell types)

Use your textbook and other available references as source material.

Once you have identified examples of each of the tissue types, examine a slide of the trachea. This structure contains numerous tissue types and provides an excellent opportunity to practice differentiation of the differing tissues.

Sketch portions of your tracheal slide to illustrate the tissue types you can identify.

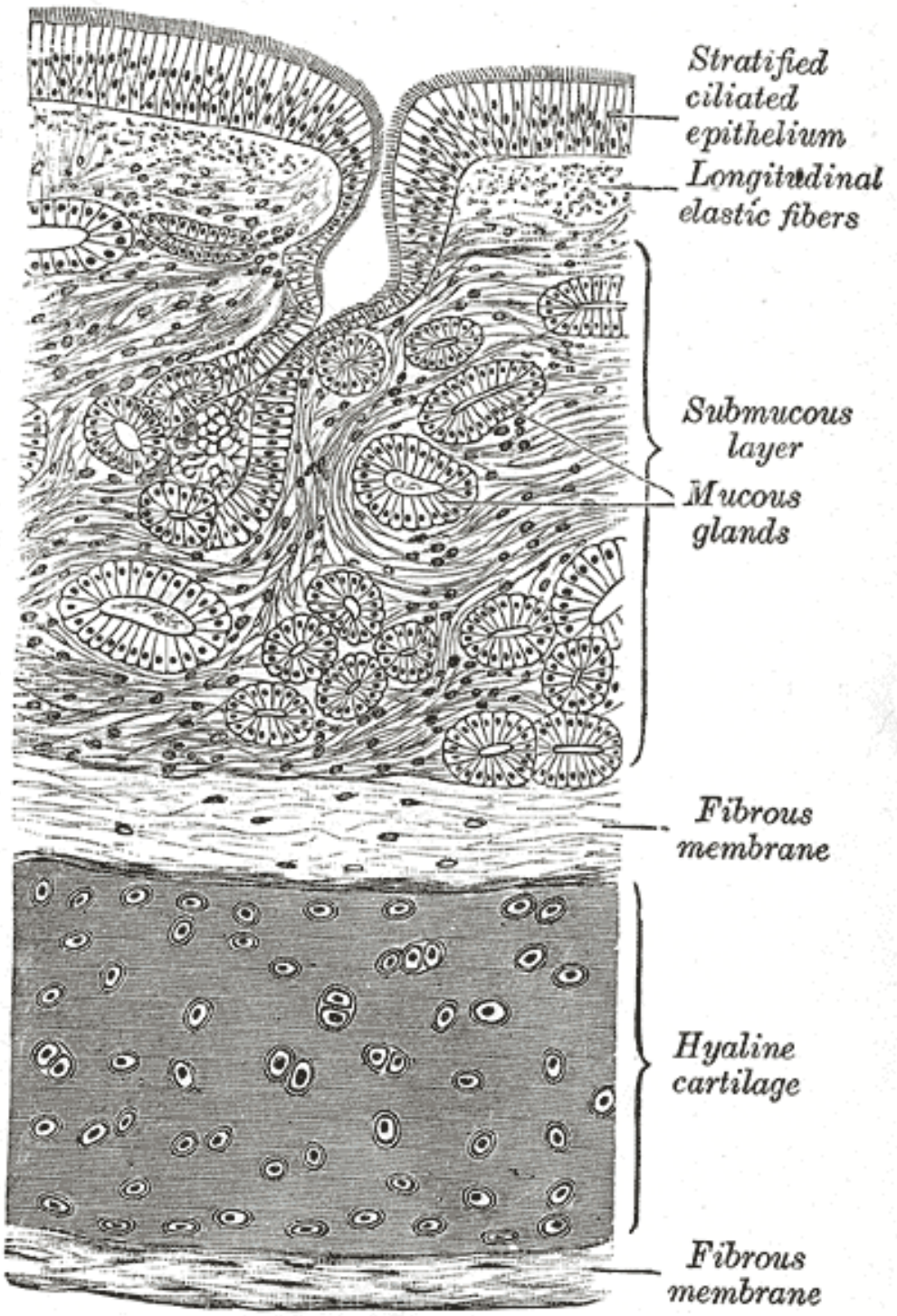

Figure 14. Cross-sectional anatomy of the trachea, showing some of the different tissues present in this material (Gray, 1920).

Table 2. List of additional Histology slides, including locations, labels and titles, for use with the Histology Lab

Sticker Colour	Tray	Sticker Number	Tissue	Slide Title
Red	B2	1	nervous	motor nerve cells
Green	A19	2a	skeletal muscle	striated muscle: sec. striated muscle: cs and ls
	A18	2bi 2bii	smooth muscle	smooth muscle: macerated smooth muscle: cs and ls
	A19	2ci 2cii 2cii	cardiac muscle	cardiac muscle: sec human cardiac muscle cardiac muscle, intercalated disk
Yellow	A1 A2	3ai 3aii 3aiii	blood	human blood smear human blood smear, Wright's stain
	A16	3b	compact bone	human bone (ground section) bone human ground cs
	A17	3c	hyaline cartilage	hyaline cartilage
	A17		elastic cartilage	elastic cartilage
	A17		fibrocartilage	fibrocartilage
	A11	3di	elastic tissue	human aorta
	A10 A9	3dii 3diii 3div 3dv	elastic tissue	artery vein and nerve artery, vein human vein: cs elastic tissue stain artery and vein artery, vein and nerve: cs artery and vein human: cs

	A19	3e	areolar tissue	areolar (loose) connective: wm
	A20		adipose	human adipose tissue adipose tissue, brown
	A20		fibrous connective	fibrous connective, (tendon)
	A20		reticular	reticular tissue
Blue	B6 B7 B8	4a	squamous epithelium	stomach, small, large intestine small intestine, jejunum human jejunum, sec. pyloric stomach: sec. small intestine, three regions
	B19	4b	cuboidal epithelium	kidney mammal, ls kidney human, sec. kidney mouse, ls
	B6 B7 B8	4c	columnar epithelium	stomach, small, large intestine small intestine, jejunum human jejunum, sec. pyloric stomach: sec. small intestine, three regions
	B12	4d	stratified squamous epithelium	tongue with taste buds tongue, foliate papilla
	B5	4e	pseudostratified columnar epithelium	pseudostratified ciliated columnar epithelium
Pink	B12	IIii IIiii	assorted tissues	trachea, cs

Biology 1120

Laboratory Exercise 6: Brain Dissection

Work in groups of about 4, using a dissecting microscope in addition to basic dissection materials. Other resources will include your textbook (Chapter 14) and colouring book, as well as the concise sheep brain diagrams and atlas of the sheep brain available on the benches around the edge of the room. Due to availability, we may use brains from other mammalian species, such as cow or horse brains.

General notes on dissections

For most dissections you will need:

one or two blunt probes	a sharp probe
a dissecting tray	6 – 12 dissecting pins
a pair of sharp-tipped dissecting scissors	one or two pairs of tweezers
a scalpel	Safety glasses

When dissecting whole organisms (not today), you may also need several flesh hooks to hold the specimen in position, or bone cutters for thick bones. A dissecting microscope may be needed for viewing fine structure of some specimens.

Of all of these instruments, the blunt probe is one of the most useful. It allows you to push and tweeze material out of the way while minimizing damage to surrounding tissues. The scalpel should be avoided as much as possible. Aside from its potential to injure the dissector, it causes severe damage to surrounding tissues on the specimen.

When carrying out a dissection, you should always start with the external features. Avoid the temptation to immediately start cutting. It is easier to locate important anatomical landmarks on an intact structure. When you cut the specimen (again, scissors are often preferred to scalpels), cut smoothly and decisively but only cut material that you need to remove or open. Tentative cutting will result in a ragged dissection that makes

identification difficult. Hacking a specimen apart will destroy important components before you can work with them. If you use scissors keep the tips of the scissors as shallow as possible to minimize damage to underlying tissues.

Surface Anatomy of the Brain

Begin by examining your brain for distinctive surface landmarks. Locate the following structures (as usual, doing a sketch of your own observations is a good idea). After the dissection, determine the functions of each of these structures.

1. **Cerebrum**
2. **Left and right cerebral hemispheres**
3. **Skull and dura meter**
4. **Pia mater covering surface of the brain**
5. **Cerebellum**
6. **Pons**
7. **Medulla oblongata**
8. **Spinal cord**
9. **Longitudinal fissure**
10. **Frontal lobe**
11. **Sulcus** (note that the specific sulci and gyri are not the same in sheep as in humans)
12. **Gyrus**
13. **Temporal lobe**
14. **Parietal lobe**
15. **Occipital lobe**
16. **Olfactory bulbs**

Examination of Cranial Nerves

Begin by placing your brain ventral side up in your dissecting tray. This ventral surface will be covered by remnants of the skull and dura mater. This material needs to be removed, but do so carefully. Use a blunt probe and scissors to cut away the membranes, while keeping the underlying cranial nerves and pituitary gland intact. This will probably require cutting away the meningeal remnants in several pieces. Try to leave the tissues and membranes around the pons and medulla fully intact.

Once the tissues of the ventral surface are fully exposed, you should again check for surface landmarks. Locate:

1. **Pituitary gland**
2. **Optic chiasm**
3. **Pyriform lobe** (nerve pathways from olfactory bulbs plus some processing regions)
4. **Cerebral peduncle** (floor of the midbrain)
5. **Pyramidal tract** (nerve pathways from the cortex to the spinal cord)

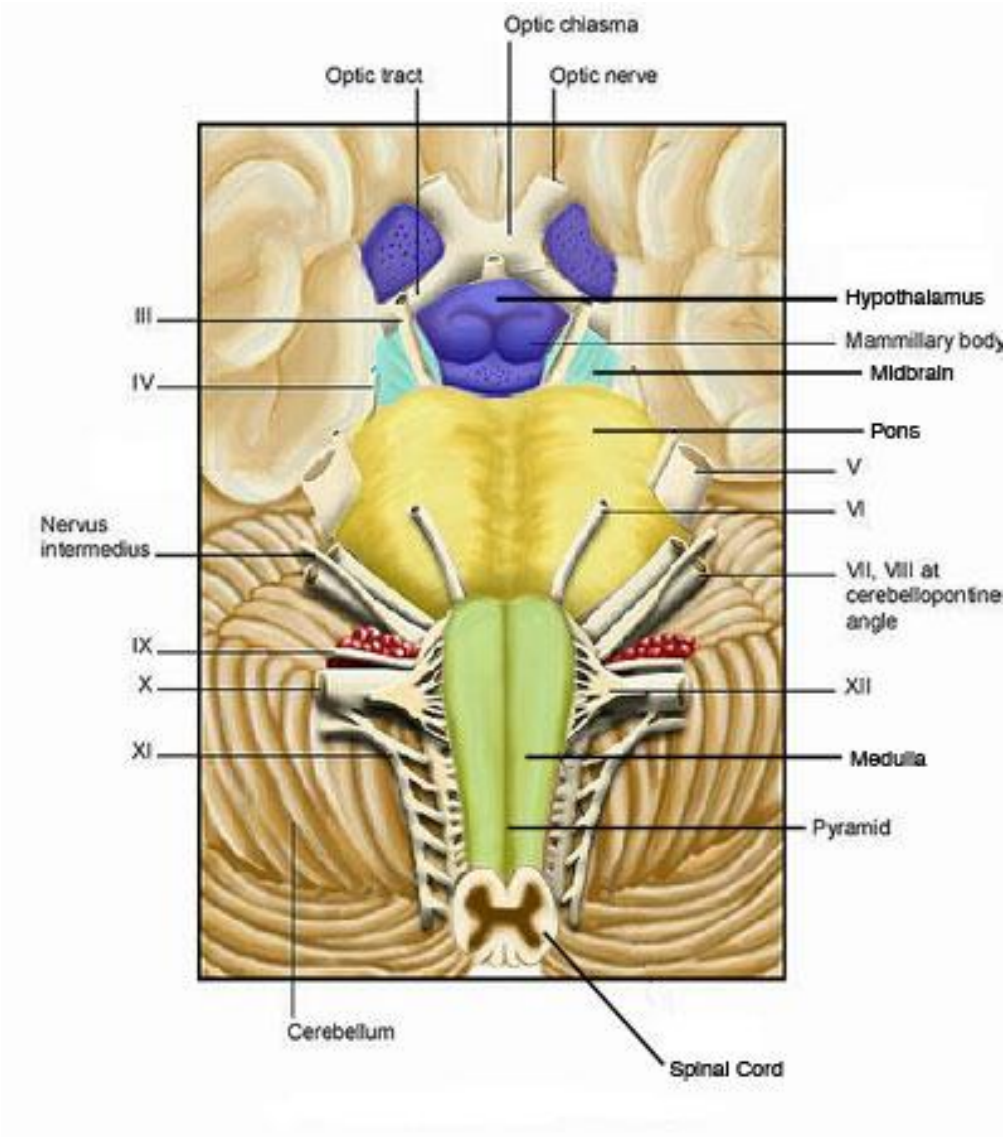

Figure 15. Ventral view of the human brain showing some of the cranial nerves and associated structures. (Royal College of Surgeons of Ireland Illustrations, 2012)

In order to see all of the cranial nerves, you will need to use a dissecting microscope. Use the same precautions for these scopes as for the compound microscopes you have used previously.

Locate as many of the twelve cranial nerves as is possible from the ventral surface. In some cases, especially nerves VII through XII, it may be difficult to distinguish nerves from meningeal remnants or emptied blood vessels. Nerves should appear uniformly whitish, without clear regions or rough surfaces. Cranial nerve IV, the trochlear nerve, is not on the ventral surface. It is located on the lateral portion of the brain, behind the inferior colliculus, just in front of the anterior end of the cerebellum. You may have to wait for more dissection before you can find this nerve. Exposure of some of the posterior cranial nerves may require you to tease away covering meninges and blood vessels.

Dissection for Internal Brain Anatomy

Once you have identified the cranial nerves you should bisect the brain, cutting a medial section through the longitudinal fissure. Once you have bisected your specimen, some of the internal structures should be visible. On the medial section you should be able to locate the following structures:

1. **Corpus callosum** (white matter joining the cerebral hemispheres)
2. **Cerebrum** (largest component of the human and sheep brain)
3. **Spinal cord** (sensory and motor tracts with some processing of signals)
4. **Medulla oblongata** (responsible for many autonomic functions)
5. **Pons** (works in concert with the medulla, autonomic and reflex functions)
6. **Cerebellum** (routine motor and equilibrium tasks, largest part of hind brain)
7. **Hypothalamus** (on ventral surface of brain, handles homeostasis and instincts)
8. **Pituitary gland** (master endocrine gland ventral to the hypothalamus)
9. **Optic chiasm** (site of partial decussation of the optic nerves, forms a cross)
10. **Thalamus** (deep portion of the forebrain responsible for sensory processing)
11. **Pineal body** (glandular structure involved in biological clock functions)
12. **Midbrain** (small in humans, located above the pons)
13. **Third ventricle**
14. **Cerebral aqueduct** (passage connecting the ventricles)
15. **Fourth ventricle**
16. **Septum pellucidum** (membrane covering the lateral cerebral ventricles)

Carefully remove the cerebellum from the dorsal surface of the brain, then the posterior and superior portion of one of the cerebral hemispheres. You can pull the cerebellum gently upward at its caudal end, then cut through the cerebral peduncles to remove the

cerebellum. Use a scalpel to excise part of the cerebrum. Examine the cut surfaces of the removed cerebellum and cerebrum to identify grey and white matter regions. Contrast the anatomy of the cross-sections of these structures to each other and to the spinal cord, whose cross-section you should also examine. How do the placement of white and grey matter differ? Why might this difference be important?

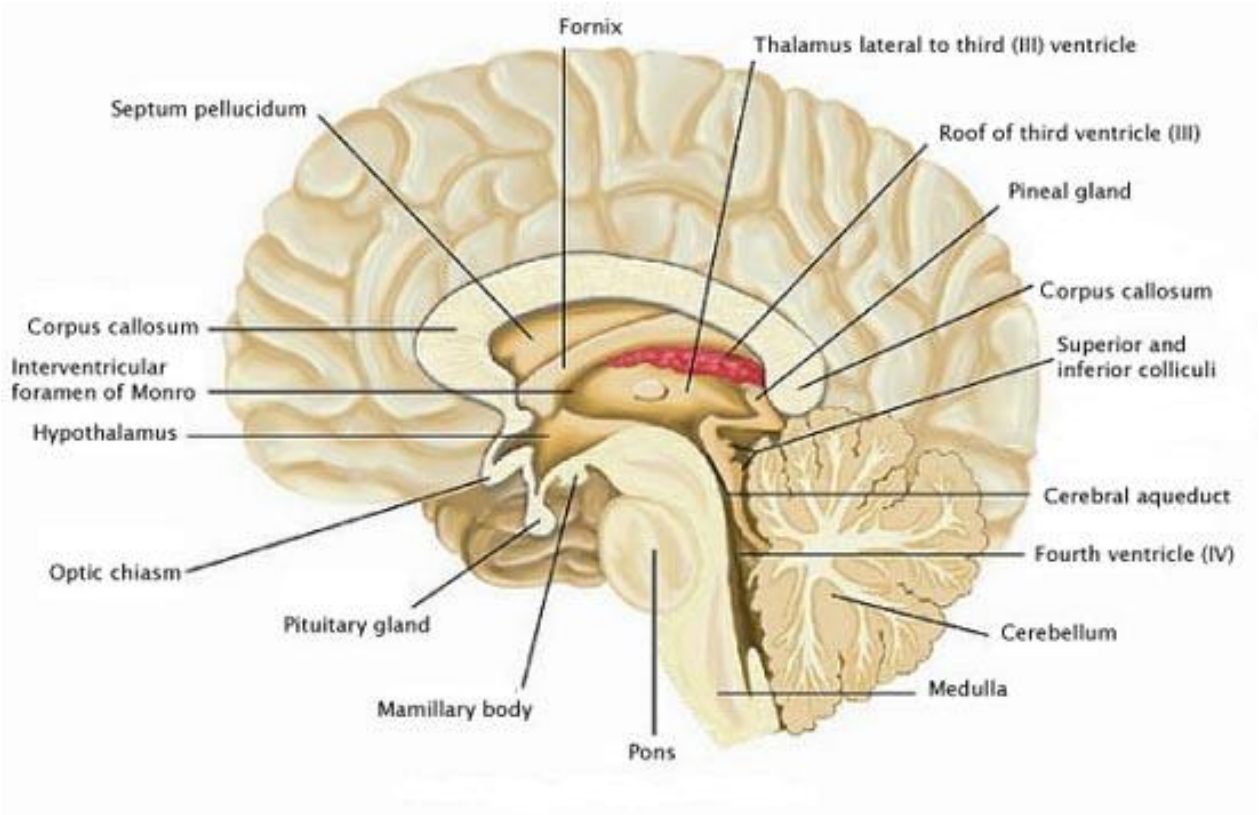

Figure 16. Midsagittal view of the human brain showing some major anatomical features (Royal College of Surgeons of Ireland Illustrations, 2012).

Some of the cerebral and cerebellar tissues have been removed, but the remaining cerebral structures in the posterior region of one side should be removed now. You may need to use a blunt probe for this removal to minimize damage to underlying tissues. Try to remove all of the cerebral tissue in this area down to the lateral ventricle. It should now be possible to get a better view of yet more structures. Locate the following structures:

1. **Fourth ventricle**
2. **Trochlear nerve (IV)**
3. **Superior colliculus** (processes visual information)
4. **Inferior colliculus** (processes auditory information)
5. **Pineal body** (photoperiod processing)
6. **Hippocampus** (memory consolidation)

Once you have identified all of the associated structures of the brain, dispose of the remaining material as directed by your instructors. Rinse your instruments and place them in the container next to the sink at the back or side of the room. Rinse your dissecting tray and place it upside down (so it can drain) beside the sink.

Biology 1120

Laboratory Exercise 7: Reactions and Reflexes

In this exercise you will investigate neural responses to both voluntary functions and reflexes. A number of differing factors can affect response times to outside stimuli including the length of nerve tracts, brain and spinal processing times, receptor processing, nerve myelination, and nerve damage, among others. We lack the facilities to carry out a full investigation of these factors (it would take teams of researchers working for years with specialised equipment to even begin), but we can examine a few simple factors in response times.

One of the most significant problems in measuring response times is that we must deal with both the subject's and observer's responses in many situations. One way to avoid this is to devise situations where the subject provides their own measure of reaction. The reaction time tests presented here attempt to eliminate observer delays wherever possible.

Part I: Reflexes

Since reflexes do not require processing by the brain, they are typically faster than responses where you must think before acting. Unfortunately, we do not have equipment to accurately measure the time for some of the quick reflex responses, but we can examine the responses qualitatively. Medical professionals often use reflexes to diagnose different types of damage to the nervous system, because of their predictability. For these exercises you should work as a group of about four students. Try each one of these reflexes on yourself and your partners. Make notes about the responses to use in your lab report. Compare results with other groups and see if there is a consensus about reflex effects.

You may find that you need to modify the procedures slightly for differing test subjects. In some cases, the reflex may be easier to elicit with legs crossed, while for others it will work better uncrossed. Try slightly modified body positions if you can't induce a strong reflex response.

a. Patellar Reflex

Have one member of your group sit on the lab bench with their legs crossed and their eyes closed. Tap the patellar tendon gently with a reflex mallet. Is the response the same for both legs? Jendrassik's Maneuver is a modification to this process. Have the subject hold their arms in front of their chest with the elbows extended out to their side. They should lock their hands together by their flexed fingers with one hand above the other. When you use the hammer to tap their patellar tendon, have them immediately try to pull their hands apart. How does this alter the response? Why?

b. Achilles Reflex

Have one group member kneel on a chair or a lab bench with their feet hanging free. Have them bend their foot upwards, so that the gastrocnemius muscle and Achilles' tendon are both stretched. Have a group member tap the Achilles tendon. What is the result? Repeat the process, but this time have the subject grasp an object firmly before the tendon is tapped. How does this change the result? Repeat the process again, but this time have them clench their teeth before the tendon is tapped. What happens this time?

c. Plantar Reflex

Use a blunt probe to firmly stroke the inner side of the sole of the foot. The normal plantar reflex is for the toes to curl down. If the toes flex out and upward, it is called Babinski's reflex. Babinski's reflex is normal in children under one year old due to lack of myelination of the nerve fibres, but in adults, it may indicate damage to the pyramidal tract fibres.

d. Pupillary Reflex

Note the size of your lab partner's pupils. Shine a bright light in their eye and note the response of the iris. What happens to the size of the pupil on the opposite side from where you shone the light?

e. Ciliospinal Reflex

Pinch the skin on one side of the nape of the neck and note the dilation of the pupil on the same side. This is a reflexive response to pain mediated by the sympathetic nervous system.

f. Nystagmus

Nystagmus is the reflexive movement of the eyes in response to signals from the semicircular canals of the ears. Fluids in these canals help to give information about body movements in space. If a person is rotated rapidly the fluid in their semicircular canals will move with them. Eventually, the fluid will catch up with the rest of the body. When the body stops its rotation, the fluid in the semicircular canals continues to move making the person feel as if they are still moving.

Note: do not do this exercise if you have any signs of illness such as cold or flu, or a history of dizziness, nausea or vertigo. Due to a shortage of suitable chairs, we will conduct this exercise in larger groups, with volunteers only. Place the volunteer on a lab stool that is easily rotated and have them hold their head at a 30° forward. Rotate them rapidly for about 10 rotations in a clockwise direction. Bring them to a rapid stop and observe the movement of their eyes. How do you explain this movement?

Part II: Measuring reaction times with a reaction ruler

In this experiment you will work with a partner or partners to measure voluntary muscular responses. You will compare reaction times to simple visual, sound and touch cues. Each partner will take turns either recording reaction times or attempting to catch a dropped ruler as soon as possible. The subject should sit comfortably while their partner stands in front of them and holds a reaction ruler immediately above their partner's outstretched hand. The standing partner should drop the ruler directly between their partner's fingers, who must attempt to close their fingers on the ruler and catch it as soon as possible. These rulers have a scale along their length that is measured in milliseconds. By reading the scale, you can determine the time it took to close your hand on the ruler once it was dropped. Try this once to get the feel of the process before recording any results.

a. Visual cues and handedness

When you are ready, drop the ruler for your partner and record the time it took for them to grab it. Repeat the drop five times for each hand. Once one subject has completed ten drops, trade places and have your partner catch the ruler five times for each hand. Calculate the average reaction time for each hand and share those values with the rest of the class. For simplicity's sake, each pair or group should only share the data for one subject with the class. That subject should be right-handed to eliminate any confounding effects of handedness on calculations.

b. Auditory cues

Once you have completed the trials using this procedure, repeat the process but this time have your partner close their eyes before they attempt to catch the ruler. Let them know when you will release the ruler by making a sound as you drop it. A tongue click or a simple spoken word will suffice. As before, try a practice drop first, then record five trials for each partner. Share the average reaction times for one subject with the rest of the class.

c. Tactile Cues

This time, your partner should again sit with their eyes closed. When you drop the ruler, touch your partner lightly on one of their outstretched arms. Do a practice drop, then record five trials. Share the average reaction times for one of the subjects.

Notes regarding the laboratory report

This report will follow the format presented in the appendix section on formal laboratory reports. There are several important issues to address in the sections of the report.

Introduction

The background information for this section should include material detailing the basic processes involved in signal transmission in the central and peripheral nervous system, including the effects of myelination and synaptic connections. You should also include information on sensory processing, especially for the visual, auditory and tactile cues we tested. Discuss the differences between simple, recognition and choice reaction time experiments. Describe the components and functioning of reflex arcs and the purposes they serve.

Hypotheses for this report should include predictions about differences in reaction times between the three sensory cues as well as differences due to handedness for the visual cues.

Results

Information from the reflexes exercises will be qualitative. Note any important observations you made while conducting these tests.

The data from the reaction times section should be presented as a summary graph. The raw data does not need to be included in your report.

Provide a bar graph comparing auditory, visual and tactile reaction times. Each bar should include the overall average as the height of the bar. Error bars (vertical lines above and below the main bar should indicate the range of values for each set of reaction times. The range should extend from the fastest individual average reaction time to the quickest, for each sensory cue type. Mark your own personal value on this range. For the visual data, include the overall average as one bar.

Include a second bar graph to show the effects of handedness. Include 2 bars for dominant hand reaction times (i.e., left hand times and right hand times by right-handed subjects). Again, include error bars and your personal results. In the text portion of the results section, include a sentence or two describing important trends or features of your graphs. Do not attempt to explain the results, however.

Discussion

In this section you will interpret your results and discuss sources of error. Incorporate answers to the following questions into your discussion. Do not list them as a separate part of the lab report.

1. Did your results agree with your hypotheses? Explain your results in light of your hypotheses.
2. Relate your results to the background information in your introduction.
3. Relate your results to the real world. What is the importance of reflex responses? How does the complexity of a task affect reaction times? What are the implications for driving? How do distractions, age, drugs, and alertness affect reaction times?
4. How does training affect reaction times?
5. Discuss CNS processing effects on reactions. Do handedness and motor and sensory decussation affect reaction times? Is there any indication of a difference in reaction times for left and right-handed responses?
6. What do your personal results indicate about your reaction times? What factors might have affected your reaction times?
7. What were the sources of error in this experiment? What were the sources of instrumental error (inaccuracies in measuring devices and other equipment) and procedural error (problems with performance of the experiments)? Be specific. Avoid vague terms like human error.

Biology 1120

Laboratory Exercise 8: Eye Dissection

Begin by examining the structures external to the eyeball. Identify as many of the following structures as possible based on the amount of surrounding tissues still attached to your eyeball:

Eyelids – connective tissue in the lids provide protection and act as anchors for attaching muscles.

Eyelashes – help to keep debris and harmful parasites off the eye.

Lateral and **medial canthi** (where the upper and lower eyelids meet)

Caruncle - the pinkish tissue in the medial corner of the eye helps facilitate movement. It is a remnant of the nictitating membrane or third eyelid found in other mammals (such as the sheep and cats and dogs).

Iris and **pupil** – the iris colour is genetically determined. Blue is a recessive trait. The pupil, the hole through the centre of the iris, expands and contracts to regulate light penetration into the eye. The control of the pupil is autonomic.

Sclera – the white outer surface of the eye which serves for support and protection

Cornea – the clear anterior portion of the sclera.

Conjunctiva - the mucous membrane lining the inner surface of the eyelids. These surfaces are quite easily irritated and are often inflamed in allergic reactions or by debris, drying or exposure to harsh chemicals, even as mild as gases from cut onions.

All of these structures should be visible from the anterior aspect of the eye. They should also be visible on your own eyes, if your specimen does not have all of the structures present. Once you have located these structures, examine the stubs of muscles attached to the eye. Locate the remnants of the six major muscles responsible for eye movement. These include:

Superior oblique muscle - rotates the superior surface of the eye medially. It inserts on the superior surface and attaches deep in the orbital socket. It passes through a fibrocartilage ring on the medial surface of the socket.

Inferior oblique muscle – inserts on the lateral surface of the eye and rotates the inferior surface of the eye medially.

Superior rectus muscle – raises the anterior surface of the eye.

Inferior rectus muscle - lowers the anterior surface of the eye.

Lateral rectus muscle – moves the anterior surface of the eye laterally.

Medial rectus muscle – moves the anterior surface of the eye medially.

If your eye is especially intact, try to find the **levator palpebrae** and **orbicularis palpebarum** muscles, which raise and lower the eyelid.

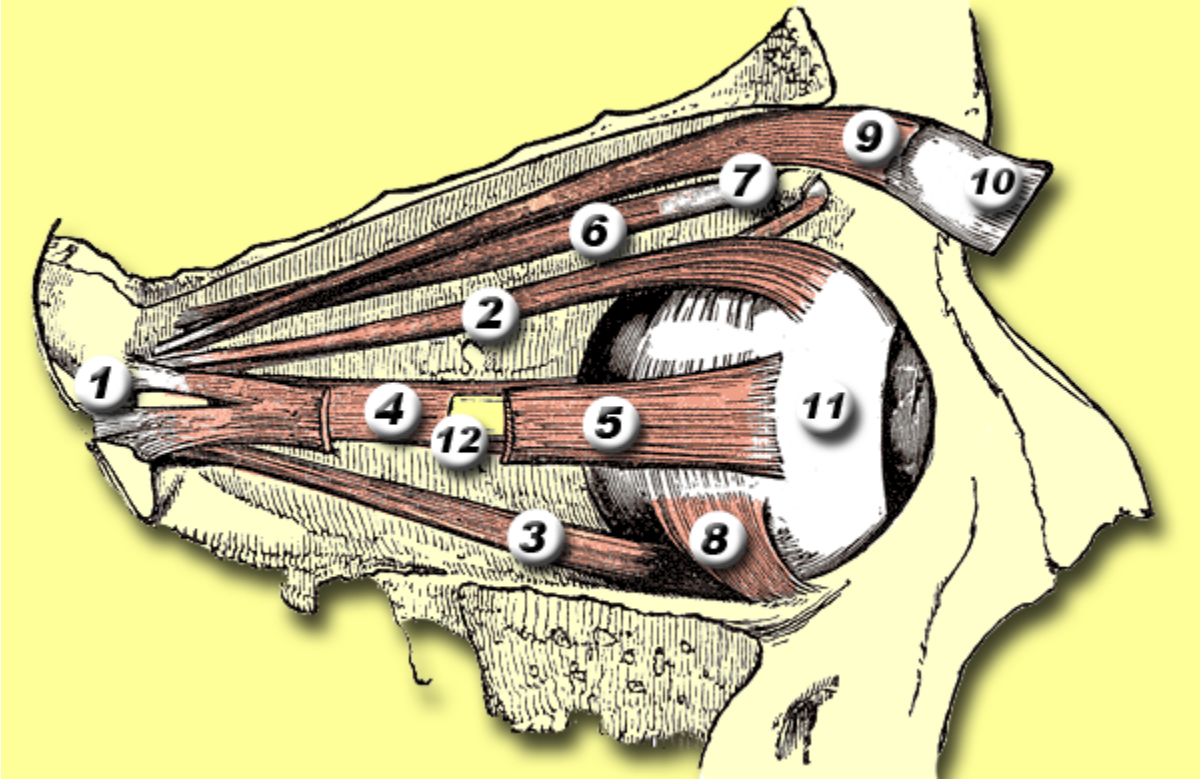

Figure 17. The muscles of the eye in a laterally viewed sagittal section (Gray, 1918). 1. Annulus of Zinn, a ring of fibrous tissue. It is the origin for several of the eye muscles. 2. Superior rectus. 3. Inferior rectus. 4. Medial rectus. 5. Lateral rectus. 6. Superior oblique. 7. Trochlear ring. It acts as a medial anchor for the superior oblique. 8. Inferior oblique. 9. Levator palpebrae. 10. Superior tarsus, a connective tissue anchor in the upper eyelid. 11. Sclera. 12. Optic nerve.

To examine the interior structures of the eye, you will need to bisect it. Cut it in a sagittal section, slightly medial to the midline of the eyeball, so that you can avoid cutting through the blind spot and fovea. The base of the optic nerve and the centre of the lens should help you to find the midline. The positioning of the eyelids should in turn help you to determine the medial and lateral sides of the eyeball. The position of the oblique muscles is another aid to determining lateral and medial, superior and inferior surfaces. The inferior oblique muscle inserts on the lateral surface, while the superior oblique attaches to the superior surface. Differentiate the sides of the eye from the top and bottom. Sheep have horizontal pupils so the widest edges of the pupil should point to the lateral and medial surfaces. Of these, the lateral surface will have two muscle insertions, as will the superior surface.

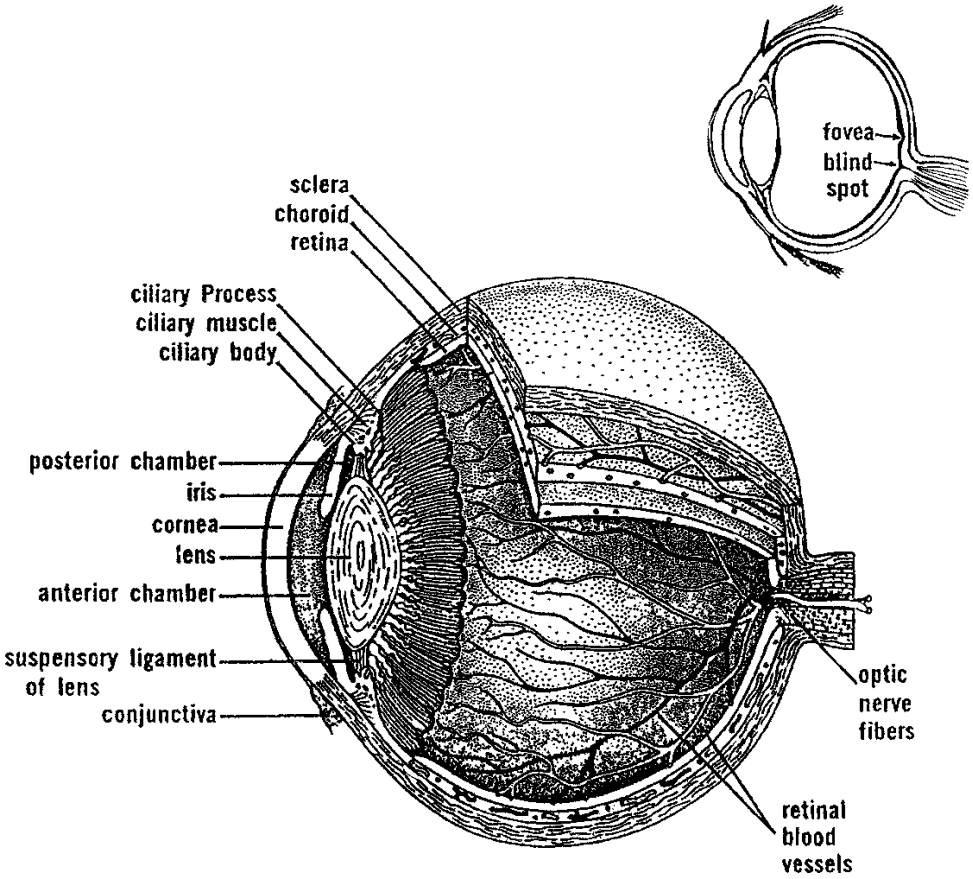

Figure 18. The anatomy of the human eye, in a sagittal section. Inset image is of an eye seen from a lateral view.

Once the eye has been cut, find the interior structures. The **anterior chamber** is the fluid filled region behind the cornea but in front of the iris. The **posterior chamber** is the equivalent region between the iris and the lens. Both of these areas are filled with a very clear fluid known as the **aqueous humor**. It is likely to leak out as soon as you cut the eye. The rear of the eye, behind the lens is mostly filled with a much more viscous fluid known as the **vitreous humor**. This material helps to support the shape of the eye and hold the nerve tissues against the outer layers of the eye.

The **lens** is clear in young living mammals but yellows with age and can become cloudy and opaque, a condition known as a cataract. In the preserved specimens, this object will be yellowish. Once you have identified all the internal structures, it is worth removing and bisecting the lens to observe its structure. It is multilayered, similar in appearance to an onion. Its main source of nutrition is via its attachments and the bathing fluids. This poor ability to obtain nourishment is one of the reasons for its deterioration with age.

The attachments of the lens are the **suspensory ligaments**. These structures will be barely visible, except as you can feel their presence anchoring the lens. Figure 11 shows these as the fibres in the Zonule of Zinn. These ligaments attach to the **ciliary processes**, which are an inward extension of the **ciliary body**. The muscles in the ciliary body are anchored near the front and inner edge of the ciliary body. Contraction of these muscles pulls the tissue forward and in toward the middle axis of the eye. As a result, tension on the suspensory ligaments is released and the lens becomes rounder, shortening the focal length of the eye. Conversely, relaxation of the ciliary muscles causes increased tension in the ligaments, resulting in stretching and flattening of the lens, improving long range focus. This process is known as lens accommodation.

The ciliary body is also responsible for production of the aqueous humor and regulation of the fluid's drainage through the microscopically small canal of Schlemm. Interference with this drainage can result in buildup of intraocular pressure and damage to the nervous tissue of the eye. This condition is known as glaucoma.

The ciliary body and processes are part of the middle layer of the eye which is known as the **choroid**. The choroid in sheep and many other animals is somewhat different than that of humans. Our choroid layers are embedded throughout with melanin, a pigment that reduces light penetration and protects the eye from bright light. Albinos cannot produce this melanin, so they are extremely sensitive to light. Their irises will also lack any melanin, since the iris is a forward extension of the choroid. This causes albinos to have pink appearing eyes, since you can see the blood infused tissues instead of the colouration due to melanin presence. Reflection of bright light from the darkened choroid causes the red-eye effect often seen in flash photography.

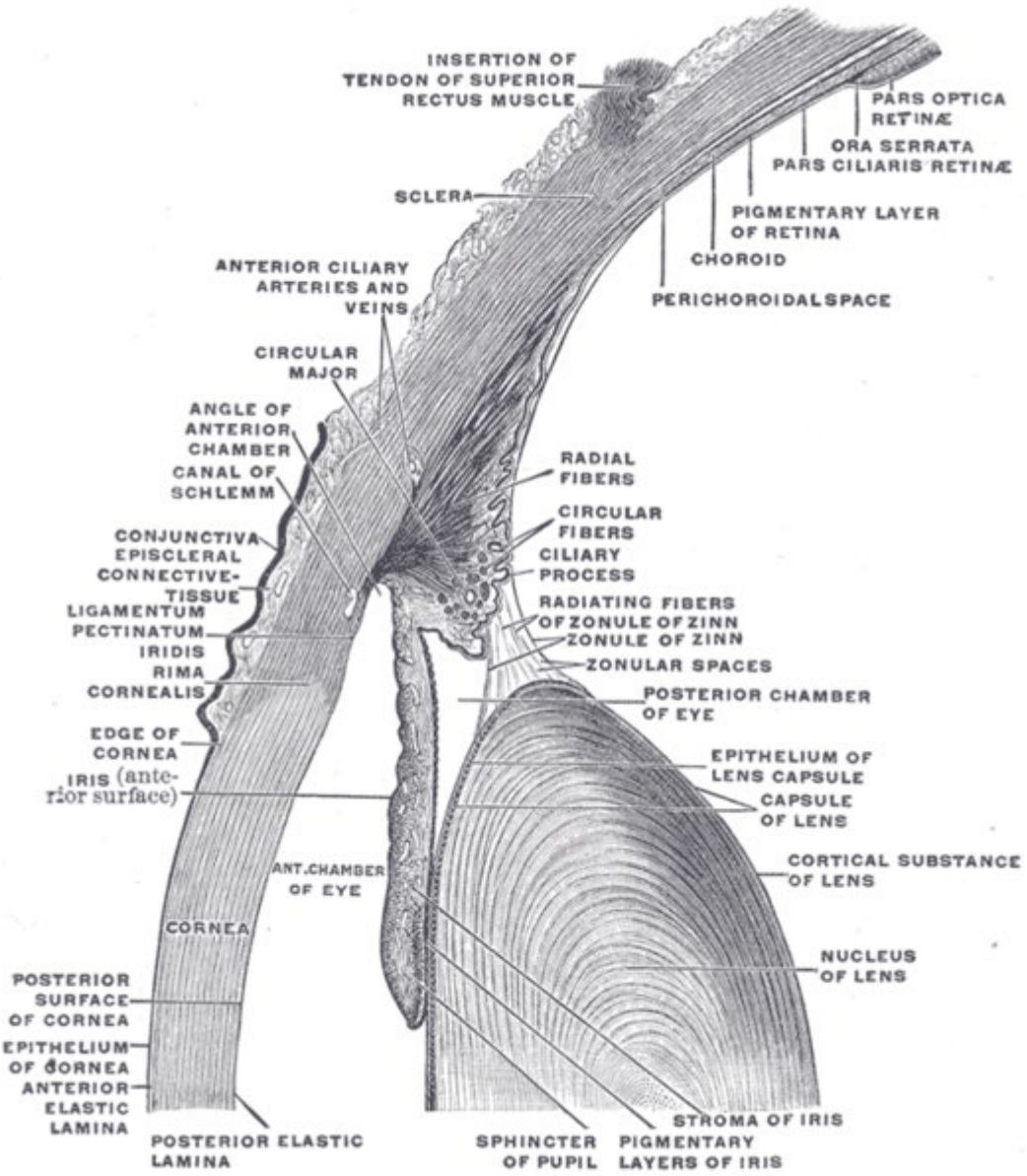

Figure 19. Detailed view of the attachments of the lens (Wikimedia commons, 2012).

Many mammals have melanin in only some areas of the choroid. Those portions will appear nearly black as you will see in your specimen. Other portions do not have melanin, forming the tapetum lucidum, a reflective portion of the choroid that increases light absorption by the retina, aiding greatly in night vision. In your specimen, these regions will look light blue-green to white. Reflection of light from the tapetum lucidum can cause these animals eyes to glow blue-green. Cat's eyes glow green under reflected light. Various other species show different reflected colour.

The inner layer of the eye is the **retina**, which is nervous tissue. It appears as a thin grey layer on the inner surface of the eye in your specimen. This is the photoreceptive portion of the eye. It has multiple microscopic layers, including the ganglionic layer, bipolar layer and receptor layer containing the rods and cones. The nerve fibres from the photoreceptors gather at the **blind spot** and exit the eye as the **optic nerve**. The blind spot is easy to locate by the wrinkles and lines that radiate from it, as well as the white optic nerve visible penetrating through the choroid and sclera at the posterior of the eye.

The most photo-sensitive portion of the retina is the **fovea centralis**. It is often easier to find the fovea by first locating the blind spot, which will be the centre of radiating nerves and blood vessels. Gently lift the retina lateral to the blind spot. A brightening of the choroid layer (the brightest part of the tapetum lucidum) should be visible with a small depression in the centre. The retina just above this spot is the fovea, the central focussing spot on the retina.

Biology 1120

Laboratory Exercise 9: Special and General Senses

In this exercise we will investigate a number of the senses except for hearing and equilibrium (those senses will be covered in the next lab). While we will carry out tests of most senses, the majority of our time will be devoted to visual testing.

Visual Acuity

Visual acuity is the ability to distinguish details. We can measure this using a Snellen eye chart. The size of letters on the chart are such that you should be able to read the first line of the chart from 200 feet away (just over 60 metres) and line 8 of the chart from 20 feet away (about 6 metres). If you can read line 8 from 20 feet away, your visual acuity is 20/20. If you need to be within 10 feet to read line 8 your acuity is 10/20; you are nearsighted or myopic. Nearsighted eyes have acuity values less than 1, and farsighted eyes have values exceeding 1. Snellen charts typically have letter sizes for assessing acuity of 20/15, which is better than normal acuity, to 20/200, which is very poor acuity.

The eyes of farsighted people (hyperopics) focus the image behind their retina. They see distant objects clearer than close objects, although they must actively focus (via lens accommodation) to see these distant objects clearly. Nearsighted people (myopics) focus the image in front of the retina. They see close objects better than they do distant objects. Both conditions can be corrected with glasses or contact lenses. People with 20/20 vision (emmetropics) can see objects fairly well at distance and do not have to actively focus in order to see them.

1. Stand 6 metres from the Snellen eye chart.
2. Cover one eye and read the letters that your partner points to on the chart. Begin at the top of the chart and work your way down.
3. Note the lowest row of letters that you can read accurately. Record the number printed next to that row: That number is the farthest distance (measured in feet) that a person with normal vision could read the letters in that row. For example, if the number is 40 then the person has 20/40 vision, meaning that the person can see at 20 feet what a person with normal vision can see at 40 feet.
4. Test both eyes. If you wear glasses or contacts, test your eyes with and without your lenses.

Left eye visual acuity: _____ **Right eye visual acuity:** _____

Astigmatism

Astigmatism is a distortion of vision due to irregularities in the shape of the cornea. Many people have varying degrees of astigmatism without being aware of the condition. If you wear corrective lenses leave them off for this test, since most prescriptions correct for astigmatism.

The astigmatism test chart is a set of radiating lines. When viewed with an astigmatic eye from a distance of 1.5 to 2.5 metres, certain lines will seem to stick out and look larger or darker than the rest. Repeat the test for both eyes. If you wear corrective lenses, check whether they correct for an astigmatism by repeating the test with your glasses or contacts in place.

Left eye astigmatism (Y/N): _____ Right eye astigmatism (Y/N): _____

Eye Dominance

Our eyes exhibit right-left dominance in a similar way to the handedness that most of us exhibit. Eye dominance is important for how we see and react to our world. Because of the fixed position of a batter, baseball players are strongly affected by eye dominance. For example, right-handed hitters in baseball have their right hand in the upper control position when they hit. Similarly, 65% of baseball players are right-eye and right-hand dominant. Only about 17% are crossed dominant (right hand-left eye or left hand-right eye), while another 18% have no eye dominance. Players with no eye dominance see the world from a point halfway between both eyes. Interestingly, the best hitters (as judged by batting average) are either crossed dominant or lack dominance. While the phenomenon is less pronounced in other sports such as hockey and golf, the relationship between eye and hand dominance still plays a significant role.

1. Hold your hands at arm's length, straight out from your eyes. Overlap your fingertips and thumbs such that a triangular shaped opening is formed between your hands
2. With both eyes open, focus on an object 3 to 5 metres away.
3. Without moving your hands, close one eye and then the other. With which eye was the object still visible through the opening? With which eye was the object obscured? The eye to which the object was visible is your dominant eye. If the object remained visible for both eyes, you lack eye dominance (central dominance). Do you have right, left, or central dominance? If you demonstrate dominance, is your dominant eye the same as your dominant hand? If not, you are crossed dominant (right hand - left eye, or left hand - right eye).

Eye dominance: _____

Visual Mapping

The fovea centralis, which is the centre of the macular region of the retina, has a high concentration of cones. As a result, this region has the most acute colour vision and the greatest visual acuity. Your clearest vision results from stimulation of this area. Whenever you look directly at an object, its image is focused on the fovea. We can use a visual map to determine the size of the fovea.

1. Tape a Visual Map to the wall at eye level.
2. Cover the left eye with an index card (if you normally wear glasses for reading, leave them on).
3. Centre your right eye in front of the dot in the small line of type.
4. Place one end of a ruler against the map and the other against your forehead to maintain a constant 300 mm (12 inch) distance. Stare intently at the dot in the centre of the small line of type.
5. Without shifting your eye, notice which letters are clearly in focus on either side of the dot.
6. Draw a circle around the dot that encloses only those letters that were clearly focused.
7. Measure the diameter of the circle in mm and substitute into the Actual Diameter formula given below to calculate the diameter of the fovea.

Actual foveal diameter = _____ mm.

$$\text{Actual diameter} = \frac{\text{Map diameter X distance from lens to fovea}}{\text{Distance from map to eye}} = \frac{\text{mm x 17 mm}}{\text{300 mm}}$$

Near the fovea is the blind spot, where the optic nerve and blood vessels enter the eye. As a result, there is no vision in this region of the retina. We can use this flaw to map the blind spot just as we mapped the fovea.

1. Stand in front of the Visual Map as before, with your left eye covered (if you normally wear glasses for reading, leave them on). Stare at the dot, keeping your eye completely still. If your eye moves, this activity will not work.
2. Cover a pencil with white paper except for its tip. Have your partner slowly move the pencil across the map from left to right, beginning at the dot. When the pencil point seems to disappear, make a mark on the map. When it reappears, make another mark.
3. Repeat the procedure going vertically through the blind spot and then diagonally to the left and right through the blind spot.
4. Connect the marks with a curved line to complete the map.
5. Measure the approximate map diameter of the blind spot in mm and again substitute into the Actual Diameter formula given below to calculate the blind spot diameter.

Actual blind spot diameter = _____ mm.

$$\text{Actual diameter} = \frac{\text{Map diameter X distance from lens to fovea}}{\text{Distance from map to eye}} = \frac{\text{mm x 17 mm}}{\text{300 mm}}$$

Peripheral Vision

Rods are able to perceive low levels of light but are generally colour insensitive. Cones, which have differing colour sensitivities and better acuity, require higher light intensity. The cones are densest at the fovea while the edges of the retina, which are active in peripheral vision, are dominated almost exclusively by rods. You can demonstrate the monochrome nature of the peripheral field by means of this demonstration:

1. While the subject stares forward, slowly bring a brightly coloured card into the visual field from behind the subject's head.
2. Stop when the subject indicates that the card has just entered the visual field.
3. Repeat the process 10 times with different colours of cards, randomly testing the left and right eyes, and record the number of times the subject correctly identified the colour of the card.
4. Now repeat the process using black and white cards and record the number of times the subject was correct.

Total number wrong (coloured cards) _____

Total number wrong (black and white cards) _____

Lens Accommodation

As we age, our ability to distort the lens of the eye to focus on near objects begins to decline. The most abrupt decline occurs between the ages of 40 and 50 years. We can provide a very rough estimate of the "age" of our lenses by measuring the minimum distance (near point) at which we can focus our eyes on an object.

1. Close one eye and hold a pencil vertically at arm's length in front of your eye. Focus on the tip of the pencil and slowly bring the pencil toward your face. Stop the pencil at the closest position where you can keep the tip in sharp focus.
2. Have your partner measure the distance from the pencil tip to the front of your eye.
3. Repeat the process for your other eye. If you wear glasses or corrective lenses try the test without using them.
4. Record the results and compare them to the chart below to calculate the "age" of your eyes.

Left eye near point = _____ cm. **Right eye near point = _____ cm.**

Table 3. Ability to Focus on Near Objects as an Approximate Analog to Age.

near point (cm)	9	10	13	18	50	83
"age"	10	20	30	40	50	60

Proprioception

Proprioception is the ability to sense the contraction or tension of a muscle organ. Receptors for proprioception include muscle spindle stretch receptors and Golgi tendon

organs. We can demonstrate the use of the proprioceptive sense with the following exercises:

1. On the first line of a piece of notepaper, write your name with your eyes open, as you normally would. On the second line, write your name again but with your eyes closed. In this case you are relying primarily on proprioception. Compare your results.
2. With your eyes open, draw a cross on the blackboard at about eye level. Now close your eyes, extend your hand out to the side, then touch the centre of the cross with the chalk. Make a small mark at that spot. Now open your eyes and measure the distance from your spot to the centre of the cross. Relate your result to the operation of the proprioceptive sense.

Touch Sensitivity

The sense of touch is dependent on various receptors in the skin. We rely on our ability to localize touch receptors when we scratch an itch or swat an insect without looking. The density of these receptors varies for different regions of the body. We can estimate the distance between receptors by mapping touch sensitivity on different parts of the skin.

1. Touch the subject (with their permission) with the corner of a piece of paper on a predetermined region of the skin (forearm, back of hand, thigh, or back) while the subject is not looking.
2. Ask the subject to touch the same point with a pencil point and measure the distance between the two touches. Do this several times for that general region of the skin. What is the average distance by which the subject erred?
3. Repeat the process for the other skin locations.
4. Have the subject continue to sit with their eyes closed. Lightly and quickly touch the skin on their forearm or back of their hand with one or two scissor tips. Ask them whether one or two points have touched them.
5. Vary the distance between the scissor tips and repeat the process for both skin regions. Estimate the distance between touch receptors based on the minimum detectable separation distance. Is there a correlation between receptor density and the errors recorded in parts 1 to 3?

Taste Sensitivity and Smell

We've all heard that smell constitutes the majority of what we usually refer to as the taste of food. Just for fun we're going to try the school level experiment to determine how well we can identify foods without using smell. For this experiment we will use cubes of apple, potato and yam.

1. Close your eyes and hold your nose. Have your partner feed you a clean sample of one of the three foods. Try to determine which food it is by taste alone.
2. Repeat the process for the other foods. Now try it without holding your nose. Did smell assist in identifying the foods?

Olfaction, Taste and Trigeminal Involvement

Some chemicals produce a cooling or irritating sensation in the nasal cavity and mouth by stimulating nerve endings of the trigeminal (fifth cranial) nerve complex in addition to smell receptors. Trigeminal stimulation with chemicals such as ammonia, chlorine, and formaldehyde can often be stinging or painful. Stimulation of these nerve endings in the sinuses or the mouth is responsible for the hot taste of many food items such as chilli and curry.

Take three strong sniffs each from the two containers and describe the sensations. How are they different? Which of the two is the most intense? How many sniffs did it take to adapt to the smell of pepper?

Repeat the process by dabbing clean cotton swabs into the solutions and then touching the solutions onto your tongue. Describe the sensations. How do they differ this time? Is the same solution still the most intense? How long does it take to adapt to the pepper?

Biology 1120

Laboratory Exercise 10: Hearing and Balance

In this exercise, you will examine various sensory functions associated with the ear. Part of the lab will be devoted to hearing testing while the rest will look at equilibrium and balance. The audiometers will be the prime instruments for testing hearing. Since we only have three of these instruments, you will have to work efficiently when using these, so that all class members will have a chance to conduct this part of the exercise. Take turns using the instruments. The exercises do not have to be done in any particular sequence.

A. Balance

The sense of equilibrium rests primarily in two sets of sensory organs in the inner ear. The first set is concerned with static equilibrium, maintaining body position while you stand still. The second set helps maintain dynamic equilibrium, balancing the head and body during movement, especially sudden movement.

The organs of static equilibrium are found in the inner ear vestibules, while those dealing with dynamic equilibrium are found in the ampullae of the semicircular canals. Both of these sets of structures work in combination with other sensory input such as kinaesthesia and vision to maintain correct posture and position.

The following tests will examine how these senses operate. Work in groups of about four to carry out the exercises. Make qualitative observations relating to the procedures and the responses of the subjects.

I) Vision and Equilibrium

Have a subject attempt to stand erect on one foot for up to one minute with their eyes open and their arms relaxed at their sides. Observe their degree of unsteadiness. Use a timer to see how long the subject is able to maintain their balance. Repeat the procedure with their eyes closed. Again, use a timer to see how long the subject is able to maintain their balance. Carry out three trials for each method and share your data with the class.

II) Nystagmus Revisited

The test for nystagmus that we carried out in the reflexes lab is just one of many tests designed to investigate the response of a subject to equilibrium challenges. In addition to the variations described here, other nystagmus tests include following moving objects with your eyes and testing responses following application of cold and warm water to the eardrum.

1. As in the reflexes lab, have the subject sit on a rotating chair with his or her eyes closed and head tilted forward about 30º. Rotate the chair ten times. Abruptly stop the movement of the chair. Have the subject open their eyes, and note the nature of the eye movements and their direction. Note the time it takes for the nystagmus to cease.
2. After several minutes of rest, repeat the procedure with the subject's head tilted at about 90º onto one shoulder. Is there any change in the recovery time from nystagmus? How do the subject's eyes move because of this stimulus?
3. After another rest period, repeat the procedure with the subject's head bent all the way forward so that their chin is touching their chest. Once again, note recovery time and the quality of eye movements.

The differences in the results from these tests should relate to which of the semicircular canals are receiving maximal stimulation. Interpret your results in relation to the position and the likely movement of fluid in the posterior, superior and lateral canals.

B. Hearing

I) Hearing tests with a tuning fork:

Hearing tests are designed to test for hearing loss. The two main reasons for a hearing deficit are problems with the bones of the middle ear (conductive loss), or problems with the cochlea itself, often involving damage to the sensory hair cells (sensorineural loss).

A. The simplest test, known as Rinne's test for its inventor, compares bone and air conduction using a tuning fork. We test bone conduction by firmly striking the upper end of the fork against a hard surface and placing the base of the fork firmly on the mastoid process, just dorsal and inferior to the pinna of the ear. Once the subject can no longer hear the sound, the vibrating top is placed one inch from the external ear canal to test air conduction. Inability to hear the sound once the fork is moved in front of the ear canal may indicate a conductive hearing loss.

B. In the Weber test, a tuning fork is placed on the subject's forehead. If the sound lateralises (is louder on one side than the other), the subject may have either an ipsilateral conductive hearing loss or a contralateral sensorineural hearing loss.

C. For the Bing test, the fork is struck and placed on the subject's mastoid tip. The examiner alternately occludes or blocks the subject's ear canal. Use a fingertip to do this. You are not trying to force your finger into the canal. Simply block the opening. If the subject has normal hearing or a sensorineural loss, he or she will notice a change in intensity with occlusion. If the patient has a conductive hearing loss, he or she will notice no change.

D. The Schwabach test simply compares the subject's bone conduction to that of the tester. If the subject stops hearing before the tester, this suggests a sensorineural loss. If the patient hears it longer than the examiner, this suggests a conductive loss. This test assumes that the tester has normal hearing.

II) Hearing tests with an audiometer:

The graph used to plot hearing levels is called an **audiogram**. The audiogram charts the level at which an individual becomes aware of sounds at various pitches. These levels are called **thresholds**. As a quick reference, to make the decibel levels more meaningful, a whisper at one and a half metres of distance is about 30dB, average conversation is about 60dB, a loud motorcycle is in the range of 100 dB, and a jet engine can exceed 150 dB. Normal hearing thresholds are from 0 to 25 dB across the tested frequencies of 125 Hz to 8000 Hz.

The audiometers that we have are capable of testing hearing via air or bone conduction for either ear. Sounds played to the subject can be simple tones, warble tones or speech. Due to time constraints, we will not carry out a full hearing test that requires more stringent environmental sound controls and threshold detection techniques. Professional hearing testing often involves bone conduction and speech testing in addition to the air conduction

we will use. The audiometers will be placed in the room so that the tester and subject can sit opposite each other. The subject should sit at either 90 degrees to the machine or even facing away. The tester should still ensure that the lid of the audiometer obscures the subject's vision so they cannot see whether a tone is being produced based on hand movements on the switches and dials of the machine.

1. Have the subject wipe the headphones with an alcohol swab and place them on their head so that red earphone is centred over the right ear and the blue on the left, with no obstructions such as hair or eyeglasses.
2. Ensure that the **output selector** on the audiometer is set to **AC** (air conduction) and the **signal selector** is set to **tone**.
3. Set the **frequency** to **1000 Hz** using the buttons on the left-hand side of the machine and the **intensity** to **0 dB** by rotating the knob on the left of the machine. Alternate ears throughout the test by changing the **left/right** button located just to the left of centre at the bottom of the control panel.
4. Press the **stimulus** button at the top left for at least **one second**. The subject should respond by raising their right hand if they hear a tone in their right ear and left hand for left ear. If the subject does not respond, increase the intensity in 5 dB increments until they hear the tone. If they do respond, reduce the intensity in 5 dB increments until they fail to hear the tone.
5. Change the frequency to 125 Hz and repeat the same process, starting at 0 dB and adjusting the intensity to find the subject's hearing threshold. Continue alternating ears as you work through the frequencies from 125 Hz to 8000 Hz. Mark the audiogram with an O for a right ear threshold and an X for the left ear.
6. Once the audiogram has been filled in for all available frequencies, switch positions so that each partner can be tested. Work quickly to allow other groups to use the machines.

Notes regarding the laboratory report

This report (if required by your instructor) will once again follow the format presented in the appendix section on formal laboratory reports. There are several important issues to address in the sections of the report.

Introduction

The background information for this section should include material detailing the basic processes involved in hearing and equilibrium. Discuss the role that other sensory inputs play in hearing and equilibrium (e.g., vision and proprioception). You should include information on the common types of hearing loss and equilibrium disorders related to our tests and their detection. Include a brief section on variability in hearing acuity and on the effects of aging on hearing.

The hypothesis for this report is fairly self-evident (hearing will be normal), so it should not be necessary to state it in the introduction.

Results

Information from the equilibrium exercises and tuning fork exercises will be qualitative. Note any important observations you made while conducting these tests. The data from the audiometer tests should be presented as a figure. In the text portion of the results section, include a sentence or two describing important trends or features of your audiogram. Do not attempt to explain the results, however.

Discussion

In this section you will interpret your results and discuss sources of error. Incorporate answers to the following questions into your discussion. Do not list them as a separate part of the lab report.

1. Did your results agree with a hypothesis that your hearing would be normal? Compare your results to those of a “normal” individual of your age.
2. Relate your results to the background information in your introduction.
3. Relate your results to the real world. What might have caused any deficits in your hearing thresholds? What might have produced the results from the tuning fork tests?
4. What produced the differing nystagmus results? What role do vision and proprioception play in equilibrium?
5. What were the sources of error in this experiment? What were the sources of instrumental error (inaccuracies in measuring devices and other equipment) and procedural error (problems with performance of the experiments)? Be specific. Avoid vague terms like human error.

Biology 1120

Laboratory Exercise 11: Rat Dissection

This lab is designed to give you a first hand look at two of the organ systems that we have examined this term. While there are many important systems that can be seen by dissecting a rat, we will limit ourselves to the endocrine and reproductive systems in this lab. A more complete examination of animal systems will be part of the laboratory program for Biology 1220, the second half of this course.

Work in groups of about 4, using a dissecting microscope in addition to basic dissection materials if necessary. Other resources will include your textbook (Chapter 14) and colouring book, as well as the concise rat guide and the laboratory anatomy manual for the rat. These latter two guides are available at the front of the room.

General notes on dissection

For this dissection you will need:

one or two blunt probes	a sharp probe
a dissecting tray	6 – 12 dissecting pins
a pair of sharp-tipped dissecting scissors	one or two pairs of tweezers
a scalpel	examination gloves (optional)

You may also need several flesh hooks to hold the specimen in position, although pins will probably suffice. A dissecting microscope may be needed for viewing fine structure of some specimens.

Of all of these instruments, the blunt probe is one of the most useful. It allows you to push and tweeze material out of the way while minimizing damage to surrounding tissues. The scalpel should be avoided as much as possible. Aside from its potential to injure the dissector, it causes severe damage to surrounding tissues on the specimen.

As with our previous dissections, you should start with the external features. Avoid the temptation to immediately start cutting. It is easier to locate important anatomical landmarks on an intact structure. When you cut the specimen (again, scissors are often

preferred to scalpels), cut smoothly and decisively but only cut material that you need to remove or open. Tentative cutting will result in a ragged dissection that makes identification difficult. Hacking a specimen apart will destroy important components before you can work with them. If you use scissors keep the tips of the scissors as shallow as possible to minimize damage to underlying tissues.

Surface Anatomy of the Rat

Begin with a quick examination of your rat for distinctive surface landmarks. Place your rat ventral side up in your dissecting tray. You may want to use pins to hold the body in a convenient orientation. Locate the posterior extent of the ribcage as well as the clavicle, which forms the anterior end. Find the anus. If you have a male, locate the penile opening and scrotum, while you should find the vaginal opening if you have a female.

Endocrine System

1. Glands of the throat

Begin your internal examination by opening the ventral surface of the throat. Make a medial incision starting just anterior to the ears and extending posteriorly to between the front legs. Pull back the skin and fur to expose the underlying tissues. Tease apart the ventral muscles of the throat to expose the **thyroid gland**, which lies just ventral and posterior to the larynx. It should appear as a round, pink structure.

An important set of exocrine glands in the neck region consists of the three pairs of **salivary glands**. The **parotids** lie laterally near the ears. The **sublinguals** lie lateral to the trachea at about the level of the cranial tip of the shoulders. Finally, the **submandibulars**, which are usually the most visible pair of salivary glands, lie just posterior to the sublinguals on either side of the thyroid gland.

The parathyroid glands are at the lateral tips of the thyroid lobes but are unlikely to be visible as they lie within the connective tissue capsule around the gland. You may, however, see several small white gland-like structures in the throat region. These are lymph nodes, and are usually located near fat deposits.

2. Visceral Glands

Once you have located the various neck glands, open up the chest and abdomen by extending your incision from the clavicle down to the anus. Try to keep the incision just lateral to the midline, as this will minimize damage to underlying tissues, in particular the reproductive structures. Pull back the skin and muscles, making transverse incisions as required to expose the cavities. Cut through the ribcage with a pair of scissors, again staying just lateral to the midline. Once the ribs are pinned back, you should be able to see the **thymus gland**. It will be lying anterior to the heart, near the cranial end of the rib cage. It should be a dark brown colour, and roughly triangular in shape.

The **pancreas** lies just posterior and medial to the stomach and appears as a greyish pink strip of pebbly tissue. The exocrine portion of this gland will have a pancreatic duct entering the duodenum (first portion of the small intestine) just beyond the caudal tip of the stomach. The islets of Langerhans form the endocrine portion of the pancreas. They cannot be distinguished by external examination from other pancreatic structures.

Also lying posterior to the stomach, but now in a lateral position is the dark red strip of tissue that is the spleen. This is not an endocrine structure, but can act as a landmark to help locate the small **adrenal glands**. These glands are at the anterior tip of the kidneys and on the left side, lie just between the spleen and the kidney at the level of the last rib. If you section one of the adrenals, you should be able to distinguish the outer **cortex** and inner **medulla**.

Reproductive System

1. Male

The most obvious structures are the scrotal sacs. Begin by opening one side with a sagittal incision through the skin, muscle (**cremaster**) and visceral membranes (**tunica vaginalis**). This should expose the **testis**, which will typically be oval, pink and vascularised. The **epididymis** in rats may appear to consist of separate structures on the anterior, lateral and caudal surfaces surrounding the testis, but it is all the epididymis.

The **vas deferens** begins at the caudal portion of the epididymis and extends anteriorly along the medial side of the scrotal sac. As it enters the abdominal cavity, it approaches the vas from the opposite side and merges with it at the base of the **urethra**.

The **prostate gland** of the rat is a lobed structure, unlike that in humans, and is found medially, at the juncture of the vas and urethra. The accessory glands in rats are somewhat different from those in humans, but the pair of **vesicular glands**, located just anterior of the prostate, are equivalent to the **seminal vesicles**. Rats also have a **coagulating gland** (but humans do not), at the same level as the vesicular glands, and a pair of **ampullary glands**, nestled in between the lobes of the prostate. The urinary bladder is also found between the lobes of the prostate. It will be a thin-walled sac, typically with a smooth surface.

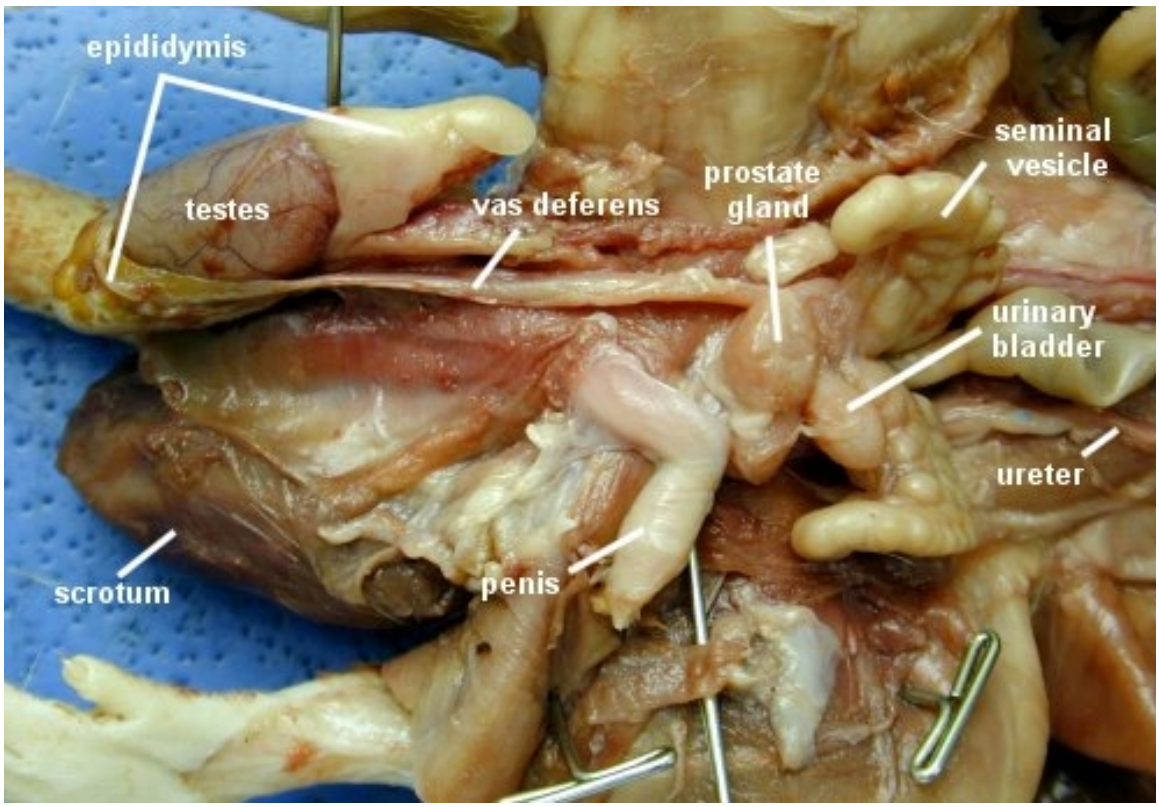

Figure 20. Male reproductive structures of a rat. The coagulating glands are indistinguishable from the seminal vesicles in this image.

The **penis** extends out to the skin. This structure is one of the reasons that your initial incision needed to be off the midline. The penis will be a short muscular structure roughly 1 cm in length. Adhering to its lateral surfaces will be yet more glands, in this case the large **preputial glands**, which lie near the glans of the penis, and the small **Cowper's glands** which should attach near the base of the penis, just lateral to the entrance of the urethra. If you cut a transverse section through the penis, you should be able to identify the paired **corpus cavernosa**, which are the lateral erectile compartments, and the **corpus spongiosum**, which surrounds the urethra. Since this is a rat, you may also find the **baculum**, which is the penile bone.

2. Female

The majority of the components of the female reproductive system will lie in the dorsal portion of the abdominal cavity. The most visible reproductive structure in the female rat will be the large **uterus**. The uterus in rats extends anteriorly into two separated **horns**. This is a different shape from a human uterus, which is a simple triangular shape. The horns of the rat uterus stay as separate compartments due to the **cervix**, which acts as a wall between the sides at the opening of the uterus into the vagina. You should be able to see the cervix by sectioning this region of the uterus.

The **vagina** extends caudally from the uterus and opens to the surface of the skin at the **vaginal orifice**. Just beneath the skin at this point are the paired **preputial glands**, or **clitoridean glands**, equivalent to the male structures. The **urethra** runs alongside the vagina on its ventral surface and empties the **urinary bladder**. At the tip of the urethra, on the outer skin, is the **glans clitoris**, homologous to the male's penis.

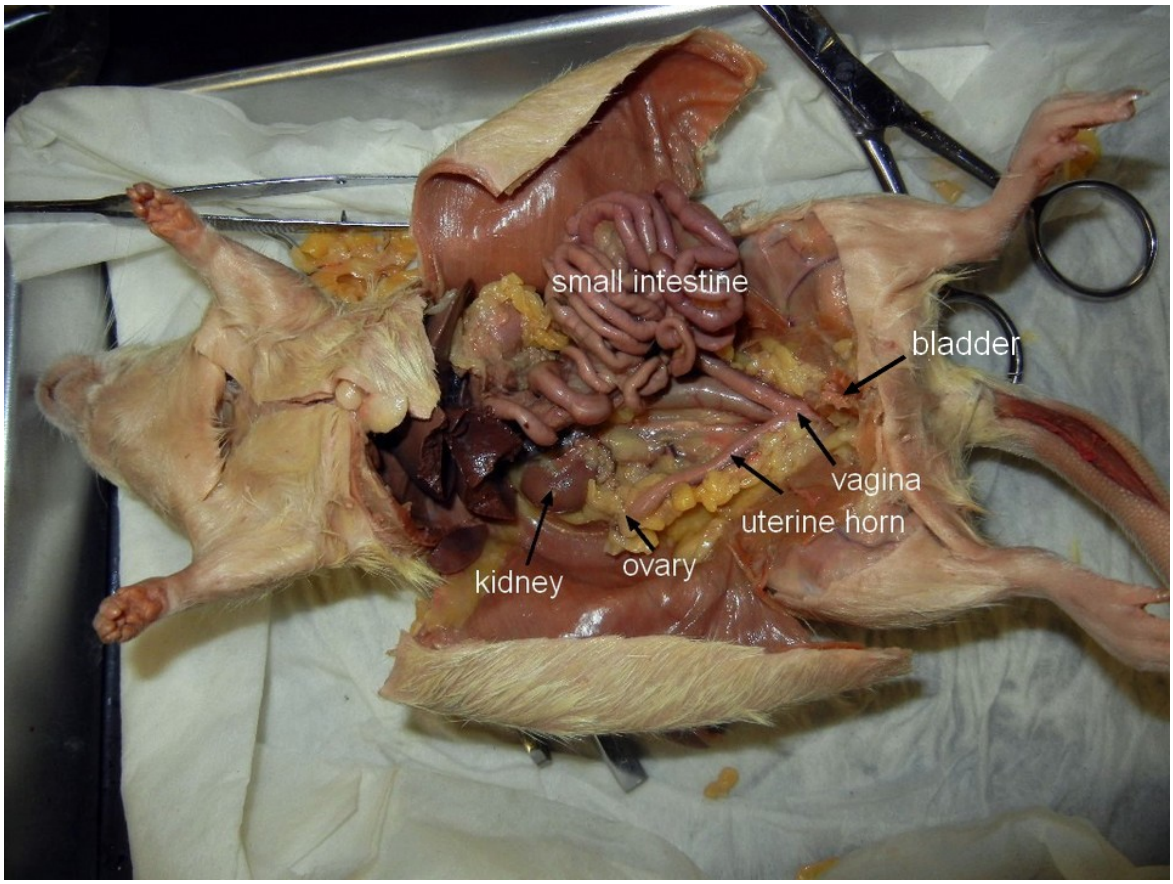

Figure 21. Female reproductive structures of a rat.

Anterior to the uterine horns are the **oviducts**, or **Fallopian tubes**. These structures are quite short in a rat when compared to humans. In humans, the distance spanned by the oviducts is equivalent to the distance for both the uterine horns and oviducts in rats. The oviducts will appear as short, pink, narrow and convoluted tubes. At the anterior tips of the oviducts are the **ovaries**. These will appear dark red and are often slightly pebbly in texture. They will usually be less than half a centimetre in length and be found just posterior to the kidneys. They will be surrounded by fatty tissue, which may play a role as shock absorbers and as a source of chemicals for steroid manufacture. If you section the uterus, you may be able to distinguish some of the **follicles** inside, with their associated **ova**.

2a. Pregnant Female

If you have a pregnant female, the structures will be the same as in the non-breeding female, but the proportions will be distorted by the enlargement of the **uterine horns**.

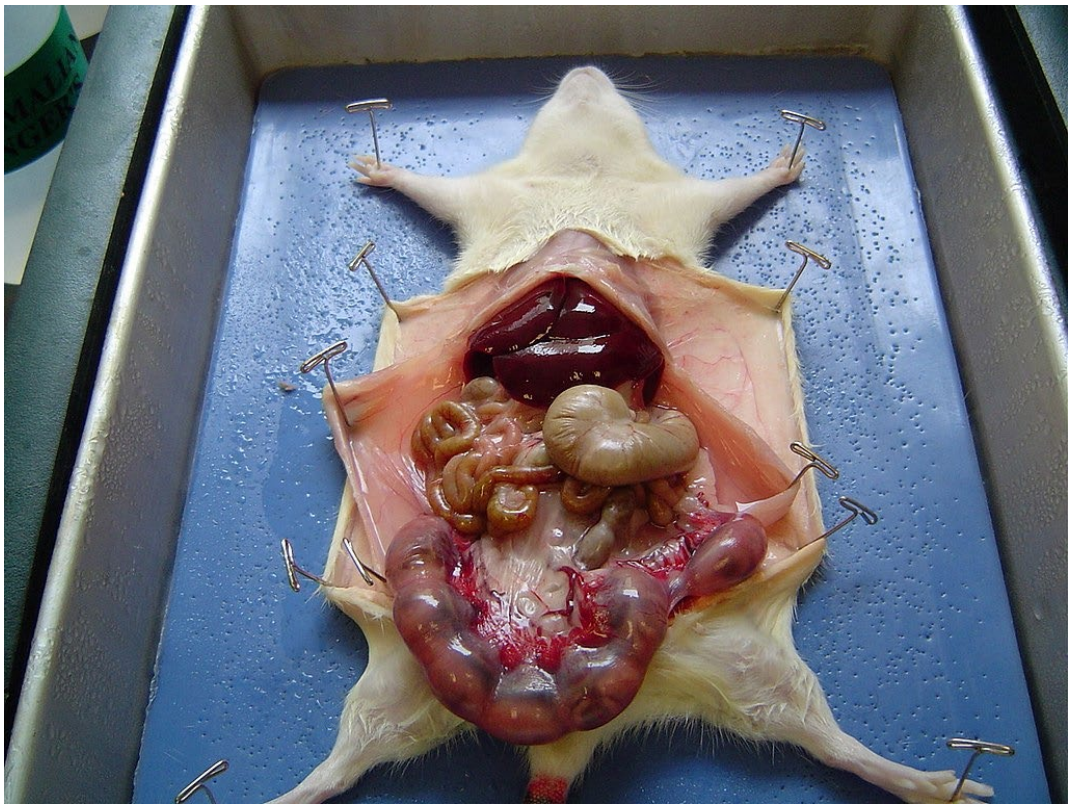

Figure 22. Female reproductive structures of a pregnant rat. In this image, foetuses and their accompanying placental support structures are shown along one uterine horn.

Count the numbers of **foetuses** present, and then open one of the uterine horns to expose the foetuses inside. In rats, like humans, the **placenta** is a **discoid** structure, meaning that the placenta attaches to the uterus at one spot, which surprisingly enough is disc-shaped.

The foetus is attached to the placenta by the **umbilical cord**, which should show signs of the umbilical blood vessels. If you gently remove the foetus from the uterus and section the placenta you should be able to see the large **uterine artery**. This blood vessel will branch throughout the placenta and may protrude into the uterine membranes, although the foetal and maternal blood supplies stay separate. The foetal blood vessels pass right beside the maternal ones, which are the **uterine venous plexus**.

The outer membrane surrounding the foetus and placenta is the **chorion**. This membrane often tears loose from the embryo when it is removed from the uterine wall. If you remove any remaining portions of this membrane, the **amnion** will be exposed, which forms the fluid-filled sac within which the foetus develops. The foetus itself may be at early or late stages of development, but a brief examination should show the limbs, developing eyes and ears, and other structures similar to those found in an adult rat.

Once you have identified all of the structures of this lab exercise, dispose of the remaining material as described by your instructors. Rinse your instruments and place them in the container next to the sink at the back or side of the room. Rinse your dissecting tray and place it upside down (so it can drain) beside the sink.

Biology 1120

Laboratory Exercise 12: Embryology

This lab is designed to expose you to some of the developmental changes that occur during the embryonic phases. Work in groups of about 4, using a Zeiss compound microscope. For some of the whole mount chick slides you may choose to use a dissecting scope instead, as the embryos are quite large. For additional resources your texts will be quite helpful. In addition, there is a good website covering issues in developmental biology (http://www.uoguelph.ca/zoology/devobio/dbindex.htm) from the University of Guelph. This site has both whole mount and sectioned slides of chick embryos as well as other species.

Examine the prepared slides of frog embryos to see the earliest stages of development. There are slides that show the first cleavage stages, blastula, gastrula and neural tube formation.

The whole mounts of chick embryos show development at 16, 33, 48 and 72 hours. The total gestation time until a chick hatches is 21 days. Bird embryos develop somewhat differently than other vertebrates due to the large yolk sacs they require for survival. As a result, the embryo is flattened onto one side of the yolk. The primitive streak in early stage (16 hour) embryos is a groove through which cells sink down before migrating out to the sides to form new germ layers during the process of gastrulation. This is followed by rapid vascularisation and rotation of the embryo onto its side.

By 33 hours organogenesis is evident. The nervous system and circulatory systems are the first structures to develop. Muscle segments (somites) are also becoming visible. These same systems are still the most evident structures at 48 hours. The brain is beginning to show regional specialisations including a separation into the forebrain, midbrain and hindbrain. The components of the eye and the structure of the heart are becoming visible. By 72 hours, the brain is beginning to show adult components such as the cerebellum and medulla, the basic chambers of the heart (atrium and ventricle) are forming and external features such as limb buds and a mouth are apparent.

Use the following diagrams as an aid to identify structures. As usual, making your own sketches is the best way to show examples of each of the stages. The diagrams are not all at the same scale. The 72-hour chick embryo, for instance, has grown so much that you may need to use a dissecting microscope instead of the standard compound microscope.

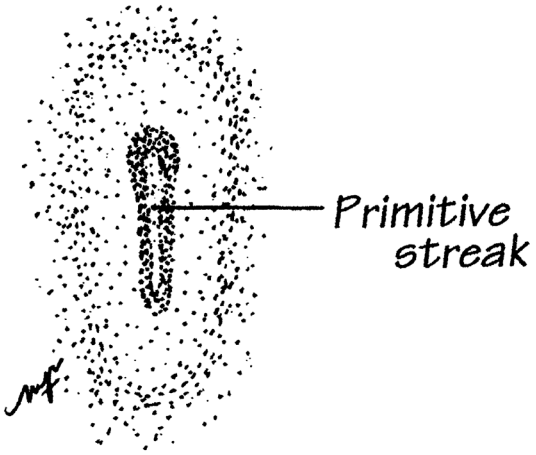

Figure 23. Whole mount of a chick embryo at a development age of 16 hours (Mackenzie, 1985).

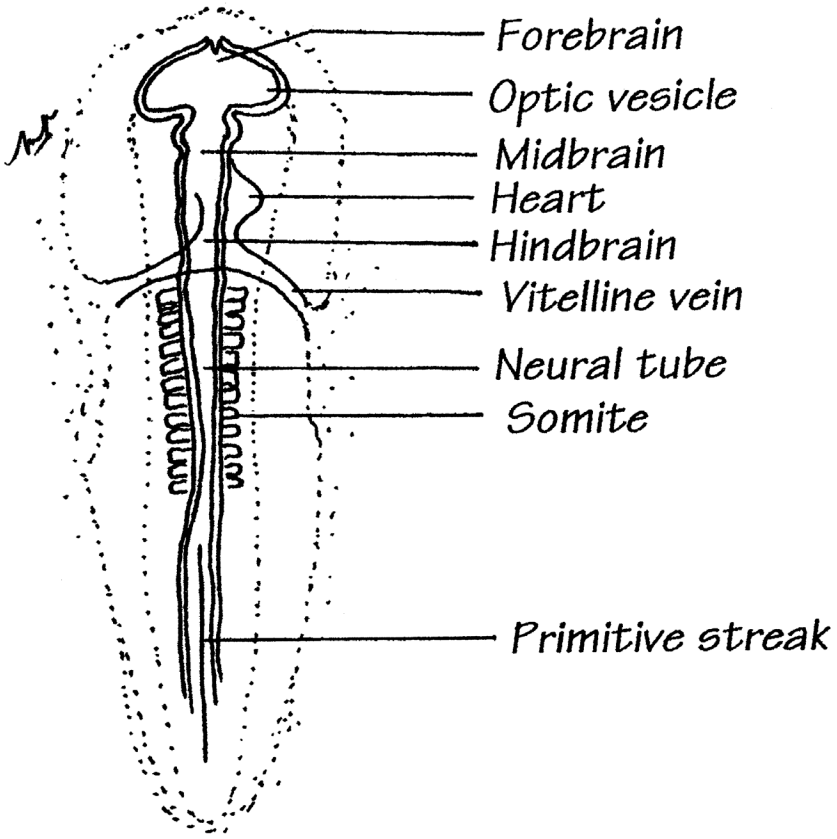

Figure 24. Whole mount of a chick embryo at a development age of 33 hours (MacKenzie, 1985).

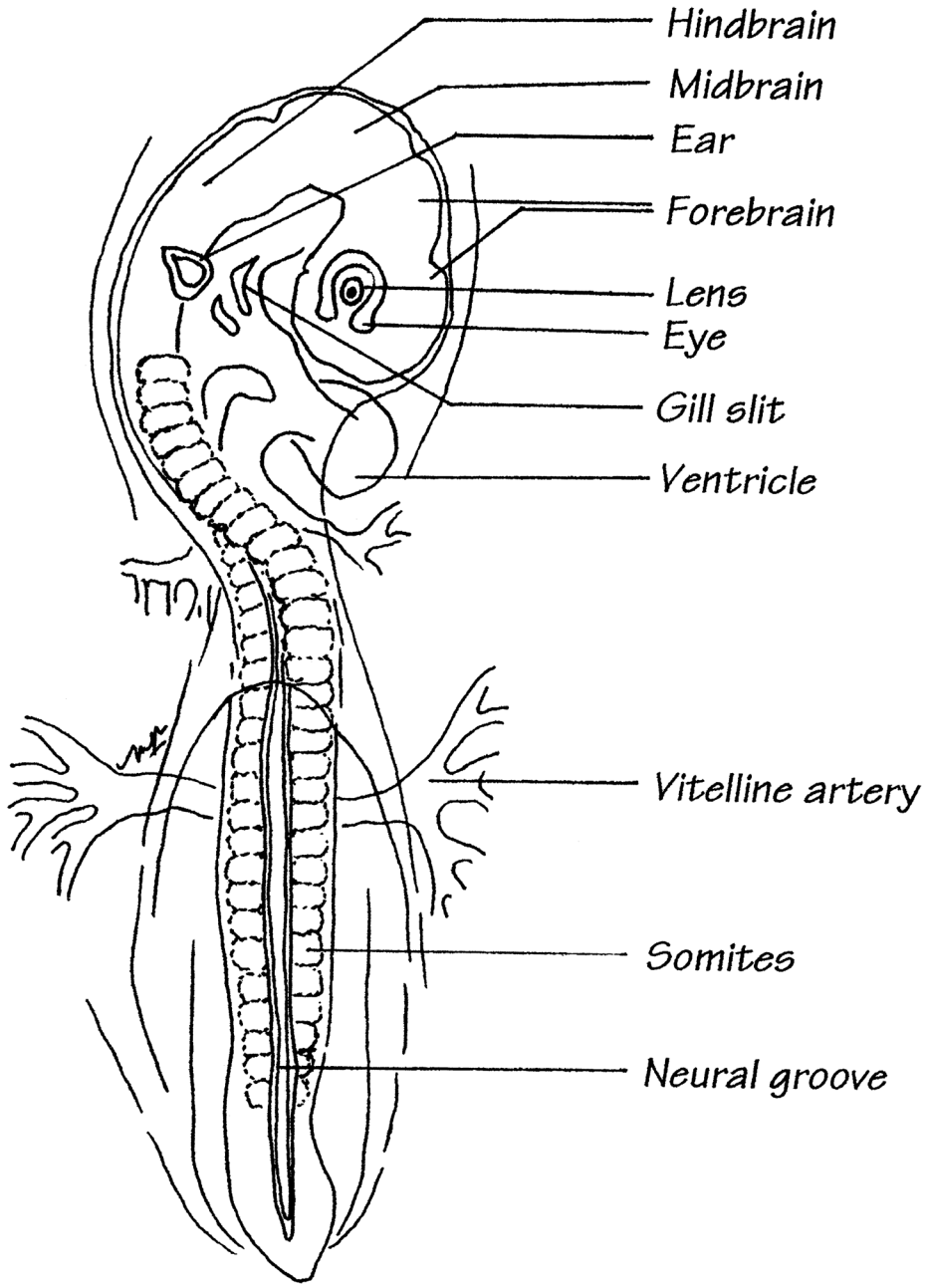

Figure 25. Whole mount of a chick embryo at a development age of 48 hours (MacKenzie, 1985).

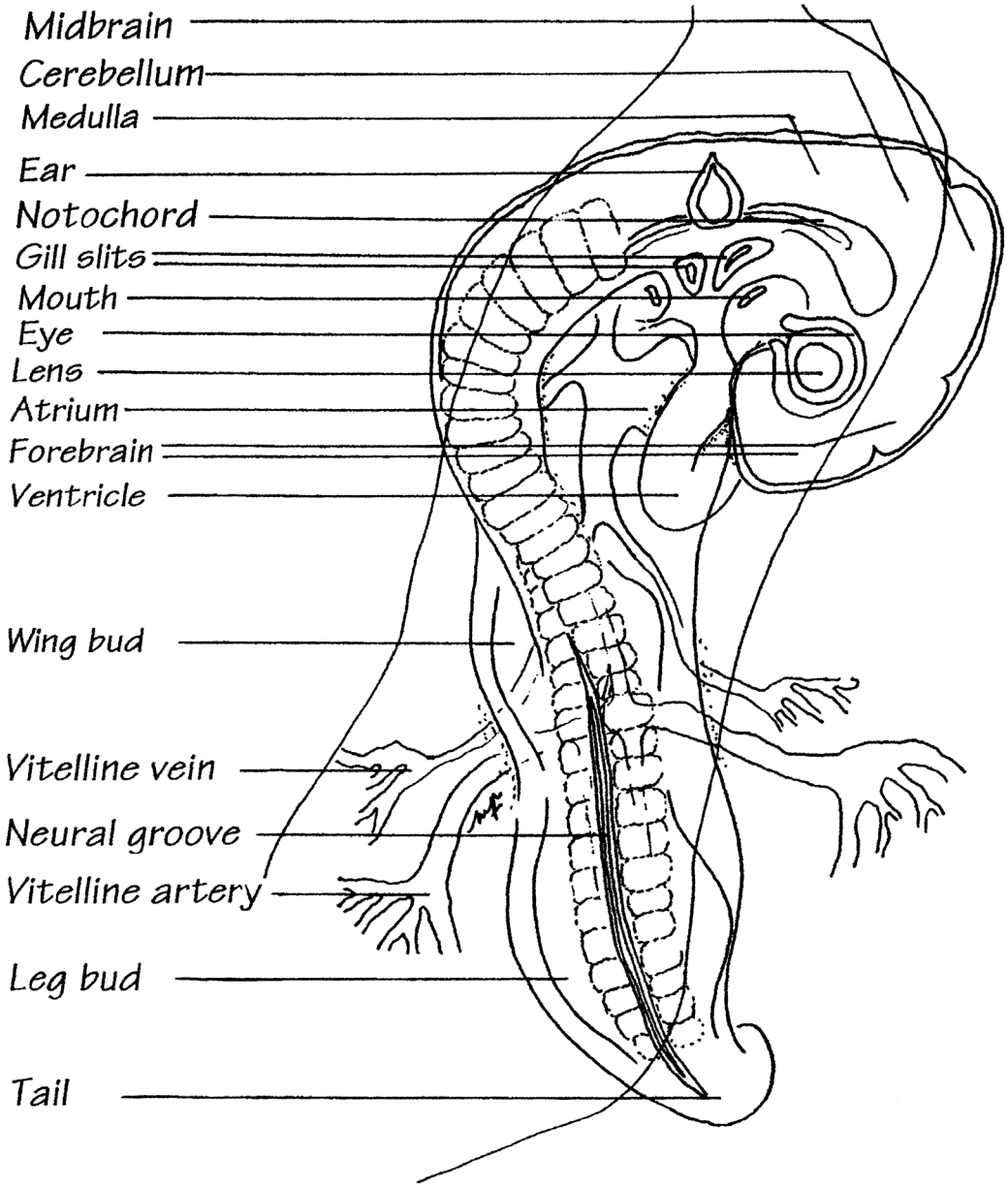

Figure 26. Whole mount of a chick embryo at a development age of 72 hours (MacKenzie, 1985).

Biology 1220

Laboratory Exercise 1: Skeletal Anatomy and Terminology

Just as in the muscle lab, you should work in groups of about 3 or 4, using the human models, charts, skeletons, skulls and text diagrams to familiarise yourself with the following structures. Ask each other (including other groups) for help in locating any of the structures that you are unfamiliar with or can't locate.

Part I: Terminology

A. Bones have a number of features that help to describe components of these bones, especially articulations, ridges, furrows and openings. Use the following terms to describe these features:

tubercle, tuberosity, ramus, fissure, foramen, fovea, sulcus, trochanter, spine, meatus, canal, condyle, epicondyle, head, neck, facet, crest, line, process, alveola, fossa

1. Small, rough projection: _____.
2. Small, rounded projection: _____.
3. Socket or pit in a bone: _____.
4. Pointed ridge or process: _____.
5. Expanded articular end of a bone: _____.
6. Any projection or bump: _____.
7. Large, rough projection: _____.
8. Prominent ridge: _____.
9. Small, flat articulation: _____.
10. Projection above a rounded articulation: _____.
11. Small opening into a larger channel: _____.
12. Shallow depression in a bone: _____.
13. Smooth, rounded articular process: _____.

14. Passageway through a bone: _____.

15. Narrow region between an articular end and a shaft: _____.

16. Elongated cleft in a bone: _____.

17. Angled extension of a bone: _____.

18. Low ridge: _____.

19. Narrow groove: _____.

20. Small pit: _____.

21. Small round passageway through a bone: _____.

Part II: Becoming familiar with the major bones

For each of the bones, indicate its general location, function (in a number of cases these will be similar), and important markings such as condyles, trochanters, processes, etc. Work in groups with the post-it notes provided and stick labelled post-its onto the skulls and skeletons to indicate the individual bones. Draw sketches to show positions and shapes.

Where I have put a number in front of the name it indicates the number of these bones found in the body. The **skeletal component** blank for each section should be filled in to indicate whether that region belongs to the **axial** or **appendicular** portion of the skeleton.

Note: This is the list of bones that you should know for this course. In some cases, I have also included non-bone parts of the skeleton that are important for you to know.

A. Bones of the skull. ***Skeletal Component:*** _____

	Location	Function	Important Markings
Cranium:			
1. Frontal			
2. Occipital			
3. Sphenoid			
4. Ethmoid			
5. 2 Parietal			
6. 2 Temporal			
Facial Bones:			
7. 2 Nasal			
8. 2 Maxilla			
9. 2 Zygomatic			
10. 2 Lacrimal			

A. Bones of the skull, continued.

	Location	Function	Important Markings
Facial Bones (continued):			
11. 2 Palatine			
12. 2 Inferior nasal concha			
13. Vomer			
14. Mandible			
Other Skull Bones:			
15. 2 Incus			
16. 2 Stapes			
17. 2 Malleus			
18. Hyoid			

B. The Vertebral Column and Ribs. ***Skeletal Component:*** _____

	Location	Function	Important Markings
19. 7 Cervical			
20. 12 Thoracic			
21. 5 Lumbar			
22. Sacrum			
23. Coccyx			
24. Intervertebral Disks.			
25. Sternum			
26. 14 True ribs (1 - 7)			
27. Costal Cartilages			
28. 6 False Ribs (8 - 10)			
29. 4 Floating Ribs (11 and 12) (note that the floating ribs are also considered false ribs)			

C. The Pectoral Girdle, Arm and Hand. Skeletal Component: _____

30. 2 Scapula

31. 2 Clavicle

32. 2 Humerus

33. 2 Radius

34. 2 Ulna

35. 16 Carpals

36. 2 Trapezium

37. 10 Metacarpals

38. 28 Phalanges

D. The Pelvic Girdle, Legs and Feet. Skeletal Component: _____

39. 2 Ilium

40. 2 Ischium

41. 2 Pubis

42. 2 Femur

43. 2 Patella

44. 2 Tibia

45. 2 Fibula

46. 14 Tarsals

47. 2 Talus

48. 2 Calcaneus

49. 10 Metatarsals

50. 28 Phalanges

Part III: Joints

As you have learned in lecture, joints can be classified both by anatomy and by movement. Use post-its again and this time label the joints of the body. Use the coloured ones if they are available, so that you can use a different colour for the different types of joints. Indicate if they are immovable, semi-movable, or synovial. If the joint is immovable (synarthrosis) indicate whether it is a suture or gomphosis. If it is semi-movable (amphiarthrosis) indicate whether it is a symphysis or syndesmosis. Finally, if it is synovial (diarthrosis) indicate the type of motion the joint can accomplish: ball and socket (multiaxial), hinge (monaxial), saddle (biaxial), pivot (monaxial), gliding (monaxial), or condyloid (biaxial). Remember, however, that joint classification is a grey area, with considerable debate about distinctions, especially between synarthroses and amphiarthroses.

Practice the types of movement by using both the skeletons and your own joints. Write the type of joint in the space beside each of the following joint names.

Joints to label:

1. Skull sutures

2. Temporomandibular

3. Tooth sockets

4. Atlanto-occipital

5. Atlantoaxial

6. Costovertebral

7. Sternocostal 1

8. Sternocostal 2 - 7

9. Intervertebral

10. Lumbar-sacral

11. Sacroiliac

12. Sacrococcygeal

13. Pubic symphysis

14. Acromioclavicular

15. Claviculosternal

16. Humeroscapular

17. Elbow (humeroulnar-humeroradial)

18. Proximal Radioulnar

19. Distal Radioulnar

20. Wrist (radiocarpal)

21. Intercarpal

22. Trapeziometacarpal

23. Carpometacarpal 2-5

24. Metacarpophalangeal

25. Interphalangeal (fingers)

26. Coxal (hip)

27. Knee

28. Proximal tibiofibular

29. Distal tibiofibular

30. Ankle (talocrural)

31. Intertarsal

32. Tarsometatarsal

33. Metatarsophalangeal

34. Interphalangeal (toes)

Part IV: Building a Body

Work in larger groups for this exercise. Groups sizes of 4 –7 should work well. Use a disarticulated skeleton and assemble it into a complete structure. Make notes about the important structural features that allowed you to identify specific bones and their orientations. Pay close attention to the articulations between the bones and again make notes about how the bones articulate. Check with your instructor or a lab demonstrator for help and to confirm that the skeleton is correct.

Biology 1220

Laboratory Exercise 2: Muscle Anatomy and Terminology

Work in groups of about 3 or 4, using the human models, charts, skeletons and text diagrams to familiarise yourself with the following muscle groups. Ask each other (including other groups) for help in locating any of the structures that you are unfamiliar with or can't locate. Muscles are often named based on their actions (flexors and extensors), shapes (deltoid), locations, origins and insertions (subscapularis, pectoralis, coracobrachialis), branches (biceps, triceps) and orientation (transverses). Use the names as clues to their locations and functions. While there are over 600 skeletal muscles in the body, it is beyond the time frame of this class to learn all of them. We will concentrate on the principle superficial muscles of the body.

Part I: Naming and Terminology

A. One of the characteristics used to name muscles is a description based on their shape. Use each of the shape terms once to complete these definitions:

bipennate, unipennate, parallel, convergent, circular, fusiform, digastric, teres, multipennate, bicipital, deltoid.

1. Fasciculi run the same way as the long axis of the muscle: _____.
2. Muscle is round: _____.
3. Fasciculi are arranged at many places around the central tendon: _____.
4. Base is much wider than the insertion: _____.
5. Muscle is organized like a sphincter: _____.
6. Fasciculi are on both sides of the tendon: _____.
7. Muscle has two bellies (the largest part of the muscle): _____.
8. Tendon has fasciculi on only one side: _____.
9. Muscle has two heads or origins: _____.
10. Triangular shape to muscle: _____.
11. Fascicles run mostly in direction of long axis, taper at ends: _____.

B. Other characteristics used in muscle naming are features such as the direction of muscle fascicles, and the size of the muscle. Match the names to the descriptions by placing the correct letter in the space in front of the description.

a. Rectus _____ widest

b. Minimus _____ large

c. Brevis _____ longest

d. Longus _____ smallest

e. Oblique _____ fascicles are diagonal to the midline

f. Vastus _____ shortest

g. Latissimus _____ fascicles are parallel to the midline

h. Magnus _____ huge

i. Transverse _____ smaller

j. Minor _____ fascicles are perpendicular to the midline

C. Function or action of the muscle is often used to name or describe a muscle. Fill in the blanks to complete the following statements about the actions of muscles. You can find the appropriate terms in your textbook

Decreases the angle of a joint: _____

Increases a joint angle: _____

Elevates a body part: _____

Lowers a body part: _____

Moves a bone away from the midline: _____

Moves a bone towards the midline: _____

Moves a body part to face downward: _____

Turns a body part face upward: _____

D. Some of the following statements are correct, but others don't quite make the grade. Place an X beside the statements that contain errors or are not always correct.

___ An aponeurosis is a flat, sheet-like tendon.

___ A fulcrum is the point at which a muscle carries out its work.

___ A fulcrum is a point around which a lever moves.

___ A sphincter controls the size of an opening.

___ Synergists oppose the action of agonists.

___ Extrinsic muscles bridge two or more regions of the body.

___ The load is between the fulcrum and effort in a second-class lever.

___ The fulcrum is between the effort and load in a third-class lever.

___ During biting, the mandible is a first-class lever.

___ Fixators allow movement in one direction only.

___ Agonists are the prime movers of a body part.

___ Muscles carry out their work by contracting.

Part II: Becoming familiar with the major muscle groups

For each of the muscles, indicate its general location, origin, insertion and function. Wherever possible you should try to locate the muscle on your own bodies as well as in the reference material. Draw sketches to show positions and shapes. Use your textbook, flash cards, anatomical models and charts or the internet as potential sources of information.

Note: This is the list of muscles that you should know for this course.

A. Muscles of the forearm and hand.

	Location	Origin	Insertion	Function
1. Pronator teres				
2. Flexor carpi radialis				
3. Palmaris longus				
4. Extensor carpi radialis longus				
5. Flexor carpi ulnaris				
6. Extensor carpi ulnaris				
7. Extensor digitorum				
8. Flexor pollicis longus				
9. Extensor pollicis longus				
10. Abductor pollicis longus				

B. Muscles of the torso, shoulder and upper arm.

	Location	Origin	Insertion	Function
11. Pectoralis major				
12. Latissimus dorsi				
13. Deltoid				
14. Infraspinatus				
15. External intercostals				
16. Teres minor				
17. Teres major				
18. Rectus abdominus				
19. External oblique				
20. Serratus anterior				
21. Trapezius				
22. Triceps brachii				
23. Biceps brachii				
24. Brachialis				
25. Brachioradialis				

C. Muscles of the hips and legs.

	Location	Origin	Insertion	Function
26. Gluteus maximus				
26. Iliopsoas (combined ilicacus and psoas muscles)				
27. Pectineus				
28. Quadriceps femoris:				
Rectus femoris				
Vastus lateralis				
Vastus medialis				
29. Sartorius				
30. Adductor magnus				
31. Gracilis				
32. Hamstrings:				
Biceps femoris				
Semitendinosus				
Semimembranosus				
33. Tibialis anterior				
34. Popliteus				

D. Muscles of the hips and legs, continued.

	Location	Origin	Insertion	Function
35. Extensor digitorum longus				
36. Gastrocnemius				
37. Soleus				
38. Peroneus (or Fibularis) longus				

E. Muscles of the head and neck.

	Location	Origin	Insertion	Function
39. Frontalis				
40. Corrugator supercilii				
41. Zygomaticus				
42. Depressor anguli oris				
43. Orbicularis oris				
44. Orbicularis oculi				
45. Medial pterygoid				
46. Lateral pterygoid				

47. Buccinator

48. Risorius

E. Muscles of the head and neck, continued.

	Location	Origin	Insertion	Function
49. Platysma				
50. Masseter				
51. Temporalis				
52. Levator palpebrae				
53. Nasalis				
54. Genioglossus				
55. Digastric				
56. Sternocleidomastoid				

Part III: Applications

In this section, try to apply some of the anatomical knowledge you have picked up by describing the major muscles that will be involved in the following activities. If you got extremely detailed you could probably tie in almost every major muscle in the body if you start considering the elements of posture and balance. Instead, key on the muscles that are directly involved in the activity.

Consider, even if you don't list all of the muscles involved, the roles that agonists, antagonists, synergists and fixators will play. You may need to include muscles that aren't on your official need to know list. That's okay, as you still need to understand their roles even if you aren't required to use them on an exam.

For at least 3 of the muscles for each activity list the type of lever action that the muscle will be exerting, whether it will be acting as an agonist (or one of the other categories), and what type of action the muscle will be carrying out (e.g., flexion, extension, adduction, abduction, etc.). Again, a rough sketch may help you to think about the muscles involved.

1. Kicking a soccer ball. Just consider the kicking action, not any run up to the ball or other activities.

2. Biting, chewing and swallowing a chunk of apple.

3. Breathing hard after a five kilometre run.

4. Writing notes in class.

Biology 1220

Laboratory Exercise 3: Respiratory Physiology

In this exercise we will investigate a few aspects of respiration. In particular we will measure the various lung capacities and flow rates and observe how they respond to changes in posture and activity. Some of the activities we carry out in this lab will also be applied in the exercise physiology lab, so learning the procedures now will help you to prepare for the data collection for that more involved lab. It is probably best to work in groups of about 4, with one person volunteering to act as the subject, one or two measuring volumes and flows and one or two recording data and doing any required calculations.

One of the main instruments we will be using for this exercise is a spirometer. We have two different types: a wet spirometer and a portable spirometer. In addition, we will measure respiratory flow using a peak flow meter, and will measure respiratory rates with a timer.

Using the Wet Spirometer

Examine the spirometer to determine how it works. It consists of two cylinders, each of which is closed at one end and open at the other. The air hose is connected to a tube which runs into the outer cylinder at the bottom, and then upwards in the center. The outer cylinder (spirometer body) is filled with water to within 3 or 4 cm of the top. The inner cylinder (spirometer bell) is positioned with the closed end up and the open end floating in the water. It contains air. A chain attached to the middle of its upper surface runs up over a calibrated pulley wheel, then down to a counter-weight on the outside of the outer cylinder.

Exhaling increases the volume of air and raises the inner cylinder. The pulley wheel turns clockwise. The free-swinging pointer mounted in the center of the wheel should be set on the upper side of the fixed pin on its periphery.

Before you begin, check the calibration of the spirometer. Adjust the position of the wheel by raising the weight and allowing the chain to slip around the pulley wheel as you turn it. Allow the bell to float freely again, and note the position of the pointer. It should point to a value just above 0 on the scale. The scale is graduated in litres and 0.l litres.

Practice using the spirometer while <u>standing</u> comfortably beside it. Obtain a CLEAN mouthpiece and attach it to the end of the air hose. If you are uncertain whether the mouthpiece is clean, wipe it with an alcohol swab and allow the alcohol to evaporate before you put it into your mouth.

You can breathe into the spirometer in two ways (use the method which allows you to breathe most comfortably).

1. Put the mouthpiece in your mouth, making sure that there is a good seal and air won't leak out around it. Breathe through your nose several times, then inhale through your nose, pinch your nose shut and exhale through the mouthpiece into the spirometer. DO NOT INHALE THROUGH THE MOUTHPIECE. Rather, release your fingers from your nose and inhale through it. Practice doing this until you become accustomed to the sequence. To determine the volume of air exhaled, note the dial readings at the beginning and end of exhalation, and subtract the initial from the final volume. Allow the disc to return to its initial position by removing the mouthpiece from your mouth (or opening your mouth around it).

2. Using the second method, only place the mouthpiece in your mouth when you exhale. Inhale normally without the mouthpiece, pinch your nose shut and exhale through the mouthpiece (forming a good seal around the mouthpiece). Between breaths the disc will return to its initial position when you remove the mouthpiece from your mouth.

Using the pocket spirometer

This instrument measures respiratory volumes between one and seven litres. It consists of a windmill-like set of vanes inside an outer housing. As air passes through the body of the spirometer, the vanes turn, driving the indicator needle.

Before using the pocket spirometer, check the calibration. The scale should read zero. If it doesn't, move the upper outer ring on the spirometer to the left or right as necessary to zero the scale. As with the wet spirometer, use a clean mouthpiece. If you are unsure whether the mouthpiece is clean, wipe it with and alcohol swab and allow the alcohol to evaporate for a few seconds before you use the spirometer.

Hold the spirometer in one hand, making sure that you keep the spirometer still and horizontal. Make sure that your hand does not cover the small holes on the side of the spirometer. As with the wet spirometer, you will measure volumes by exhaling into the instrument. Place a clean mouthpiece over the nozzle on the base of the pocket spirometer. Breathe into the pocket spirometer using one of the two methods described above for the wet spirometer. Once you have read the volume measurement from the scale, reset the needle to zero.

If you want to measure small volumes, such as tidal breathing, adjust the needle to rest on the 1000 mL mark. Your tidal volume will be the final reading minus 1000 mL.

Using the peak flow meter

This instrument is used to indicate the peak expiratory flow rate of a subject in litres per minute. It consists of a mouthpiece placed in front of a hinged sheet that bends at a calibrated force level. Blowing through the mouthpiece bends the sheet and moves the indicator gauge to show the maximum force of exhaled air, which can be measured as a maximum flow rate in litres per minute. It provides an indication of the respiratory passages to allow airflow. This can be useful for measurements for physical training purposes or to assess respiratory disorders such as asthma or emphysema, where changes to the respiratory system have increased its compliance.

Before using the flow meter, ensure that the sliding needle on the side of the meter is set to zero. As with the other instruments use a clean mouthpiece or clean the existing mouthpiece with an alcohol swab and allow the alcohol to evaporate for a few seconds.

To measure peak flow, stand upright, inhale deeply, pinch your nose closed and blow as hard and as fast as possible through the flow meter. You only need to blow for a few seconds as it is unlikely that the flow will ever exceed this initial value. Read the value in litres per minute from the scale, then reset the needle to zero.

A. Determining Resting Respiratory Rate

For this activity, simply count the number of exhalations in a 60 second period. Make 3 counts of Respiratory Rate while standing quietly. Count for 60 seconds each time and average. Record your results below for each member of your group.

Table 4. Resting Respiratory Rates from Class Activity

Resting Respiratory Rate (breaths/min)	**1st**	**2nd**	**3rd**	**Average**
Subject 1				
Subject 2				
Subject 3				
Subject 4				

B. Determining Peak Flow Rate

You will use the peak flow meter for this exercise. Take 3 readings for each subject as described above. The single highest reading (not the average) is your peak flow rate. Record the results for each member of your group.

Table 5. Peak Flow Rates from Class Activity

Resting Peak Flow Rate (litres/min)	**1st**	**2nd**	**3rd**	**Highest Value**
Subject 1				
Subject 2				
Subject 3				
Subject 4				

C. Determining Respiratory Volumes

Respiratory volumes and capacities will be measured using the spirometer (except total lung capacity and residual volume since measuring these values requires more sophisticated techniques).

Do all measurements with the subject standing erect, but not watching the spirometer dials. Try to get readings to the nearest 0.05L or 50mL. In all tests (except inspiratory reserve volume) only exhaled volumes are measured. The spirometers should be calibrated to zero between each reading.

Charles' Law states that volume of a gas is proportional to its absolute temperature. Air expands when heated and contracts when cooled. The volumes determined in the spirometer, which is at room temperature, are smaller than they would be at body temperature (37°C) and should be corrected to be representative of volumes in the lungs. This correction is necessary to improve accuracy when spirometry is being used as a diagnostic technique or when comparisons between individuals or to standard values are necessary. Table 1 lists the correction factors by which the raw data would be multiplied to get the true volumes for body temperature. Calculate the corrected values for each volume to allow more accurate comparisons to values from your texts.

Table 6. Correction Factors for Converting Spirometer Volumes to Body Temperature Adjusted Volumes.

Spirometer Temperature (^{O}C)	**Correction Factor**
15	1.130
16	1.124
17	1.118
18	1.113
19	1.107
20	1.102
21	1.096
22	1.091

Spirometer Temperature (^{O}C)	**Correction Factor**
23	1.085
24	1.08
25	1.075
26	1.068
27	1.063
28	1.057
29	1.045
30	1.039

Spirometer/air temperature = _____°C.

Using the spirometer can affect your breathing rate, due to the psychological effects of being monitored and the physical change in compliance since the instrument will slightly impair airflow. A small amount of practice can minimize this effect. Measure the subject's respiration rate for several trials of exhaling through the spirometer until it closely matches the values obtained without the spirometer. Try counting while breathing freely, and while holding the spirometer in your mouth and breathing through the nose - the results should be the same. As well, carry out several trials where you measure the amount of air exhaled in quiet breathing, repeating until your results are consistent. If the value exceeds 0.5 litres (500 ml) consistently, you are probably blowing into the apparatus. practice breathing with a normal rhythm.

I. Tidal Volume

Make 3 separate measurements while maintaining **normal quiet breathing rhythm**. Inhale and exhale through the nose several times. When you feel ready, exhale through your mouth without forcing it and remove the mouthpiece. Repeat if the determinations are not within 0.l litres of each other.

Table 7. Tidal Volumes from Class Activity

Resting Tidal Volume (ml)	**1st**	**2nd**	**3rd**	**Average**	**Corrected Average**
Subject 1					
Subject 2					
Subject 3					
Subject 4					

II. Resting Respiratory Minute Volume

As activity levels increase the amount of oxygen that is transferred from the air in the lungs to the blood must increase. For this lab, though, we will simply calculate the resting rate. In the upcoming exercise physiology lab, we will examine the effects of exercise on these values, so make sure you **save your data from today's lab session**. Ventilation (V) or respiratory minute volume (ml/min) is calculated by multiplying the average respiratory rate (breaths per minute) by the average corrected tidal volume (ml per breath).

Table 8. Resting Respiratory Minute Volumes from Class Activity

Respiratory rates and volumes	**Subject 1**	**Subject 2**	**Subject 3**	**Subject 4**
Respiratory rate (60 sec)				
Corrected Tidal Volume (ml)				
Respiratory Minute Volume (V in ml/min) = (Rate x $TV_{corrected}$)				

III. Expiratory Reserve Volume

Breathe normally in and out through the nose. At the **end of a normal expiration** pinch your nose closed and continue to blow out into the spirometer, emptying your lungs as completely as you can. Performance of this test often improves with practice. Rest between trials for a minute or two. Encouragement of the subject by one of their partners often helps ("Come on - Keep going - you can still blow out more"). Repeat several times until 3 consistently high values are obtained. Calculate the mean, discarding initial values if they are not consistent with the rest.

Table 9. Expiratory Reserve Volumes from Class Activity

Resting Expiratory Reserve Volume (ml)	**1st**	**2nd**	**3rd**	**Average**	**Corrected Average**
Subject 1					
Subject 2					
Subject 3					
Subject 4					

IV. Inspiratory Reserve Volume

Breathe normally in and out through the nose for about one minute then breathe in as deeply as possible. At the end of the inspiration pinch the nose closed and **exhale** through the mouthpiece normally, without forcing the air out. Subtract your tidal volume from the spirometer reading and record this difference as the Inspiratory Reserve Volume. Repeat 3 times, with a rest between trials. Calculate the mean.

Table 10. Inspiratory Reserve Volumes from Class Activity

Resting Inspiratory Reserve Volume (ml)	**1st**	**2nd**	**3rd**	**Average**	**Corrected Average**
Subject 1					
Subject 2					
Subject 3					
Subject 4					

V. Vital Capacity

Calibrate the spirometer pointer to near zero, if necessary. Inhale as deeply as possible through your nose. Pinch your nose closed and exhale into the mouthpiece as much as you can. Empty your lungs of air as completely as possible. Repeat 3 times. **Record the largest value (NOT the mean)**.

Test the consistency of your results. Vital Capacity should equal Tidal Volume + Inspiratory Reserve Volume + Expiratory Reserve Volume.

Table 11. Vital Capacities calculated from Class Activity

Measured Resting Vital Capacity (ml)	**1st**	**2nd**	**3rd**	**Largest Value**	**Corrected Value**
Subject 1					
Subject 2					
Subject 3					
Subject 4					

Predicted Measured Vital Capacity VC (ml): TV + IRV + ERV =

Do not assume that these volumes should match exactly. Inconsistency will probably be relatively large since the apparatus used is crude, and the results depend on voluntary efforts on the part of the subject. Vital capacity varies with sex, body size and age. Its value, based on data collected from large numbers of non-smoking individuals living in a low pollution area, may be predicted as follows:

Male: Predicted VC = 0.121 H - 0.0136 A - 3.18

Female: Predicted VC = 0.078 H - 0.0154 A - 1.05

H = height in inches
(if you measure height in centimetres use 0.0476 H instead of 0.121 H for males and 0.0307 H instead of 0.078 H for females)

A = age in years

Predicted Vital Capacity is measured in Litres

Calculate the predicted vital capacity for your gender, height and age, and compare with the measured value (you will need to use table 1 to get the temperature corrected value in order for this comparison to be accurate). Measured values within $\pm$ 20% of predicted values are considered to be normal.

Predicted Vital Capacity (ml) =

VI. Residual Volume and Total Lung Capacity

Residual Volume and Total Lung Capacity cannot be measured with the spirometer because they consist of (or include) the volume of air that cannot be exhaled under any circumstances. However, these values can be roughly predicted for normal individuals using the factors listed in Table 12.

Table 12. Age Adjustment Factors for Estimating Residual Volume (RV) and Total Lung Capacity (TLC) from Vital Capacity (VC).

Age	Residual Volume (RV)	Total Lung Capacity (TLC)
16-34	RV = VC x 0.250	TLC = VC x 1.250
35-49	RV = VC x 0.305	TLC = VC x 1.305
50-69	RV = VC x 0.445	TLC = VC x 1.445

Calculate your predicted Residual Volume and Total Lung Capacity from your **measured Vital Capacity**.

Predicted Residual volume (ml) =

Predicted Total Lung Capacity (ml) =

Biology 1220

Laboratory Exercise 4: Respiratory Chemistry

In this exercise we will investigate a bit of the interaction among inhaled and exhaled gases. This particular activity has picked up the nickname of the breathalyser test. Unlike the famous roadside test that measures the level of alcohol in your exhaled air, however, in this activity we will see how exhaled and inhaled air can cause a chemical reaction. This reaction will mirror what occurs continually in our bloodstream, where dissolved gases undergo similar reactions.

To carry out this activity you will need a breathalyser kit which will include a pair of glass bottles, a mouth piece set that has two corks with glass rods attached to plastic tubes and a mouthpiece, an alcohol swab to sterilise the mouthpiece before use, and a mixture of water, sodium hydroxide and phenolphthalein (a pH indicator – it is pink in a basic solution and clear in an acidic one).

Preparing and Using the Apparatus

Begin by filling the bottles about 2/3 full with water (about 100 ml per bottle). The amount doesn't have to be exact as this is a qualitative reaction rather than a quantitative one. You should then add 5 ml of sodium hydroxide to each bottle, followed by 3 or 4 drops of phenolphthalein for each of the two bottles. Insert the corks into the bottles. Once you are done, the fluid levels should be above the longer glass rod in each bottle but below the shorter rod.

Sterilise the mouthpiece. One member of your group will act as the subject while the others will observe the reactions. Put the mouthpiece in your mouth. Breathe in and out through the mouthpiece, raising your hand when you inhale and lowering your hand when you exhale. The arrangement of the glass rods will cause you to inhale through one of the bottles and exhale through the other. Raising and lowering your hand will allow your partners to keep track of which bottle is receiving exhaled air versus which is being used during inhalation. Continue breathing in a normal fashion until there is a visible change in the solutions in the bottles. Breathe until this reaction has gone to completion.

Try to explain the reason for the changes observed in the solutions in the bottle.

Which of the bottles (inhalation or exhalation or both) experienced a change?

What chemical reaction could be causing this change? Which gases in our breath are responsible for this reaction?

Explain the reactions based on what we know of acid-base chemistry. How do the reactions in the bottles mimic what occurs in our bloodstreams?

Biology 1220

Laboratory Exercise 5: Cardiovascular Anatomy

In this lab we will look at three major components of the cardiovascular system: blood vessels, the heart and blood itself. Much of this work will be microscopic examinations, but we will also dissect a sheep heart, and work with the models and charts to identify some of the major blood vessels.

A. Blood Vessel Anatomy

Work in groups of about 2 to 4 with a compound microscope. Use the microscope slides at the side of the room to identify the three major types of blood vessels. We will not look at examples of arterioles or venules, since their structure is basically similar to that of their larger cousins, the arteries and veins. Both veins and arteries have three layers. The tunica interna (inner layer) consists of an endothelium surrounded by a basement membrane and connective tissue. The endothelium is the most important component of this layer and consists of squamous epithelium that minimizes turbulences in the blood and therefore enhances flow. The tunica media (middle layer) is primarily smooth muscle along with collagen and variable amounts of elastic tissue. This layer is important for the constriction, expansion and recoil of the blood vessels that account for much of the changes in blood pressure. The tunica externa (outer layer) serves as a protective layer and anchor to the other tissues of the body. It is mostly connective tissue. Much of this layer is loose connective tissue, allowing room for nerves and other small vessels to connect to the structure.

Their thick, muscular walls and prominent elastin layers distinguish arteries. You can identify veins based on their large diameters, thinner muscular layers and weak or invisible elastin components. Finally, capillaries have a very different structure than any of the other blood vessels. They are usually only one cell thick to enhance diffusion, often with an accompanying basement membrane. Some capillaries will also have pores that further ease movement of materials from the blood to surrounding tissues.

B. Major Blood Vessels of the Human Body

As with the bone and muscle labs, work with your textbooks, models and the large charts to learn the locations and names of the following major arteries and veins of the body. Note that with a few exceptions, most arteries and veins have both left and right versions.

Arteries:

Aorta

Brachiocephalic

Common, External and Internal Carotids

Subclavian

Vertebral

Axillary

Brachial

Radial

Intercostals

Coeliac Trunk

Common Hepatic

Splenic

Gastric

Superior and Inferior Mesenterics

Renals

Common, External and Internal Iliacs

Femoral and Deep Femoral

Popliteal

Anterior and Posterior Tibials

Pulmonary Trunk

Pulmonary

Coronaries

Veins:

Superior and Inferior Vena Cava	Superior and Inferior Mesenterics
Pulmonary	Splenic
Brachiocephalic	Lumbar
Jugular	Gonadal
Subclavian	Renal
Axillary	Common, External and Internal Iliacs
Radial	Femoral and Deep Femoral
Subscapular	Popliteal
Cephalic	Anterior and Posterior Tibials
Hepatic Portal	Great and Small Saphenous

C. Blood Cell Anatomy and Physiology

Work in groups of about 2 to 4 with a compound microscope. Use the microscope slides of blood smears at the side of the room to identify the types of blood cells. You should be able to identify red blood cells (erythrocytes), platelets, and the 5 varieties of white blood cells (leukocytes). In addition, you should be able to identify some of the common pathologies of blood including anaemias and leukemias, diseases involving the red blood cells and white blood cells, respectively.

Anatomy

Erythrocytes will be easy to identify, as they will appear as pink to violet (depending on the particular preparation method used) discs about 7 microns in diameter. They will be the most numerous cells visible in the smear.

Platelets are often difficult to see due to their small size. Since these are cytoplasmic fragments from megakaryocytes, they can be irregularly shaped, although they usually appear roughly circular. They will be less than half the size of a red blood cell.

Leukocytes are either granular in appearance, with prominent grains in the cytoplasm, or agranular. Agranular leukocytes will still show some grainy texture to their cytoplasm, but much less than in the granular forms. Typically, white blood cells will have been stained so that their nuclei will appear dark red to purple. They will be much less common than red blood cells. A typical field of view may only contain a handful of white blood cells surrounded by thousands of red blood cells. High numbers of leukocytes is an indication of a pathological (disease) condition such as leukemia. Granular leukocytes include neutrophils, eosinophils and basophils, while agranular types are the monocytes and lymphocytes.

Neutrophils are the most common of the white blood cells. Over half the leukocytes in a healthy blood sample will be neutrophils. They are somewhat larger than erythrocytes, usually about 9 to 15 microns in diameter. The multi-lobed nuclei of neutrophils are their most distinguishing feature. In many cases, the lobes will be almost detached from one another with only thin filaments connecting them.

Eosinophils are fairly uncommon, so finding one in a single field of view is unlikely. You will need to search the slide to view an example of this type of granular leukocyte, as they comprise only 1 to 3 percent of white blood cells. They are fairly large (usually about twice the size of a red blood cell) with a nucleus that typically displays two lobes. Their cytoplasmic granules often stain a bright red colour.

Basophils are the least common type of white blood cell. They comprise less than 1 percent of leukocytes. They average just slightly larger than neutrophils, and just like eosinophils, will typically have nuclei with two lobes. The nucleus in these cells is often hard to see, as the prominent cytoplasmic granules, which are often stained blue, can obscure it.

Monocytes are agranular and very large. They are usually more than twice the size of a red blood cell. They will have a thick, pale cytoplasmic layer around their nuclei, which are usually oval or show some indentation to produce a nucleus that is roughly U-shaped. Monocytes make up 4 to 10 percent of white blood cells.

Lymphocytes are the second most common type of white blood cell. Roughly one quarter of the leukocytes are of this variety. They are small for a white blood cell. The smallest lymphocytes are about the size of a red blood cell, although the largest ones can be still be up to twice the size of an erythrocyte. The nucleus of a lymphocyte is usually round, and the cytoplasmic layer will be quite thin and pale.

Anaemia

Anaemia is a disorder reflected in problems with the red blood cells. Anything that interferes with the production or function of erythrocytes will produce anaemia. Common symptoms are weakness and shortness of breath, since oxygen transport is affected. There are many forms of anaemia, but we will examine three specific pathologies.

Iron-deficiency anaemia is one of the most common forms. As you would expect, it results from a lack of iron with which to manufacture fresh haemoglobin. This can result from poor diet or problems with iron absorption and metabolism. A blood smear of a victim of this disorder will show either reduced numbers of red blood cells or erythrocytes that are pale or erythrocytes that are smaller than normal.

Pernicious anaemia is also related to nutrition. In this disorder, problems with absorption of vitamin B12 interfere with erythrocyte manufacture. Again, the common result is fewer red blood cells than in a normal blood smear. Occasionally, pernicious anaemia can produce abnormally large erythrocytes due to the improper formative period.

Sickle cell anaemia is a genetic defect that results in abnormal structure of the haemoglobin molecule. The result is that haemoglobin is more hydrophobic and the molecules collapse in on each other. As a result, the erythrocytes are misshapen (hence the sickle cell). The erythrocytes are not just crescent-shaped, however; they take on a variety of abnormal shapes, often with sharp protuberances. These deformities produce problems with oxygen transport, since it is harder for the gas to associate with the haemoglobin. As well, the edges of the erythrocytes can damage vessel walls resulting in vascular damage and clotting.

Leukaemia

Leukaemia is a disorder of the leukocytes. Essentially, one type of white blood cell has become cancerous, resulting in mitotic proliferation of that cell. Even though there are elevated counts for the particular leukocyte, these excess cells are non-functional and will interfere with normal blood cell functions because of the energy and space that they consume.

There are, basically, as many types of leukaemia as there are types of leukocytes. As well, the precursor cells to the leukocytes can produce their own versions of leukemia. In all instances the number of visible leukocytes will be increased. The type of leukocyte in higher than normal abundance can be used to identify the type of leukaemia. Leukaemias are also sometimes classified based on the histological development of the specific leukocytes (e.g., myeloid leukaemia) or the appearance of the leukaemic cell (e.g. hairy cell leukaemia, which is the appearance taken by cancerous B lymphocytes in this particular pathology).

In addition to being grouped by the particular type of leukocyte involved, leukaemias fall into acute and chronic categories. Acute leukaemias are versions that have appeared recently and are highly aggressive in terms of the proliferation of the cancerous leukocytes. The white cell counts in this case will be extremely elevated. Chronic leukaemias are versions that produce relatively fewer cancerous cells and can persist for years. Chronic leukaemias will still have an overabundance of leukocytes, but the condition might be missed from just a cursory examination of a blood smear, without conducting a formal differential cell count.

Other White Blood Cell Anomalies

There are a number of factors, aside from leukaemia, that can produce unusual white cell counts or appearances. The most common reason is disease and infection. Since the white cells proliferate to combat the problem, there can be an increase in certain types of white blood cells. Bacterial infections may result in increased neutrophil counts, while viral infections may impact lymphocyte numbers. **Leukocytosis** is the general term for an elevated leukocyte count, while **leukopenia** is a depressed count.

D. Anatomy of the Heart

We will dissect sheep hearts to examine the structures of the heart. As usual, work in groups of about 4 students. In addition to your textbook and colouring books, there are a number of copies of the concise sheep heart at the front of the room. This is a colour dissection guide to this organ. There is also a large model of the heart and the hearts from the torso models that may help you to identify the various structures.

For this dissection you will need:

two blunt probes	a sharp probe
a dissecting tray	one or two pairs of tweezers
a pair of sharp-tipped dissecting scissors	a scalpel

Exterior Anatomy

Begin by identifying important surface landmarks of the heart. There will probably be remnants of the pericardium attached to the heart (this inner, visceral layer is known as the **epicardium**). This will appear as a glistening membrane that is closely associated with the cardiac muscle tissue, the **myocardium**. There will also be large **fat deposits** over the surface of the heart. Determine the left and right side of the heart. One simple way to identify the sides is by palpation of the ventricles. The **left ventricle** is typically larger and firmer than the **right ventricle**. The left ventricle extends to the **apex** of the heart. The line separating the ventricles is known as the **interventricular groove** or sulcus. It has both an anterior and a posterior portion.

The left and right atria are most easily identified by the **auricles** or tissue flaps that project outward from the atrial chambers. The atria are separated externally from their respective ventricles by the right and left **atrioventricular grooves**, which are also known as the coronary sulcus. The **coronary sinus** will be found in the same region as the right atrioventricular groove. This sinus is a thin-walled chamber that collects blood from the vena cava before it is passed to the right atrium.

Identifying blood vessels externally can be problematic. The most obvious and unmistakeable structures are the **coronary arteries** running over the surface of the heart. The **left coronary artery** exits from the base of the aorta and branches into the **anterior**

interventricular artery that runs caudally down the heart by the anterior interventricular groove and the **circumflex artery** that curves over to the left by the atrioventricular groove. The other coronary artery coming off the aorta is the **right coronary artery**. This circles around the heart to the right. It also follows the atrioventricular groove and branches into the **posterior interventricular artery** that travels down the posterior interventricular groove towards the apex, and the **marginal arteries** that branch out across the surface of the right ventricle.

The major blood vessels entering and exiting the heart may be more or less identifiable, depending on the way that your sheep heart was removed from the body. The aorta, superior and inferior vena cava, pulmonary trunk and pulmonary veins may be visible, but is usually easier to identify them by following them from the chambers after sectioning the heart. Under ideal conditions, if the aorta section attached to the heart is long, you may be able to see the start of the branching of the aorta, where the brachiocephalic artery, left common carotid artery and left subclavian artery arise from the aortic arch.

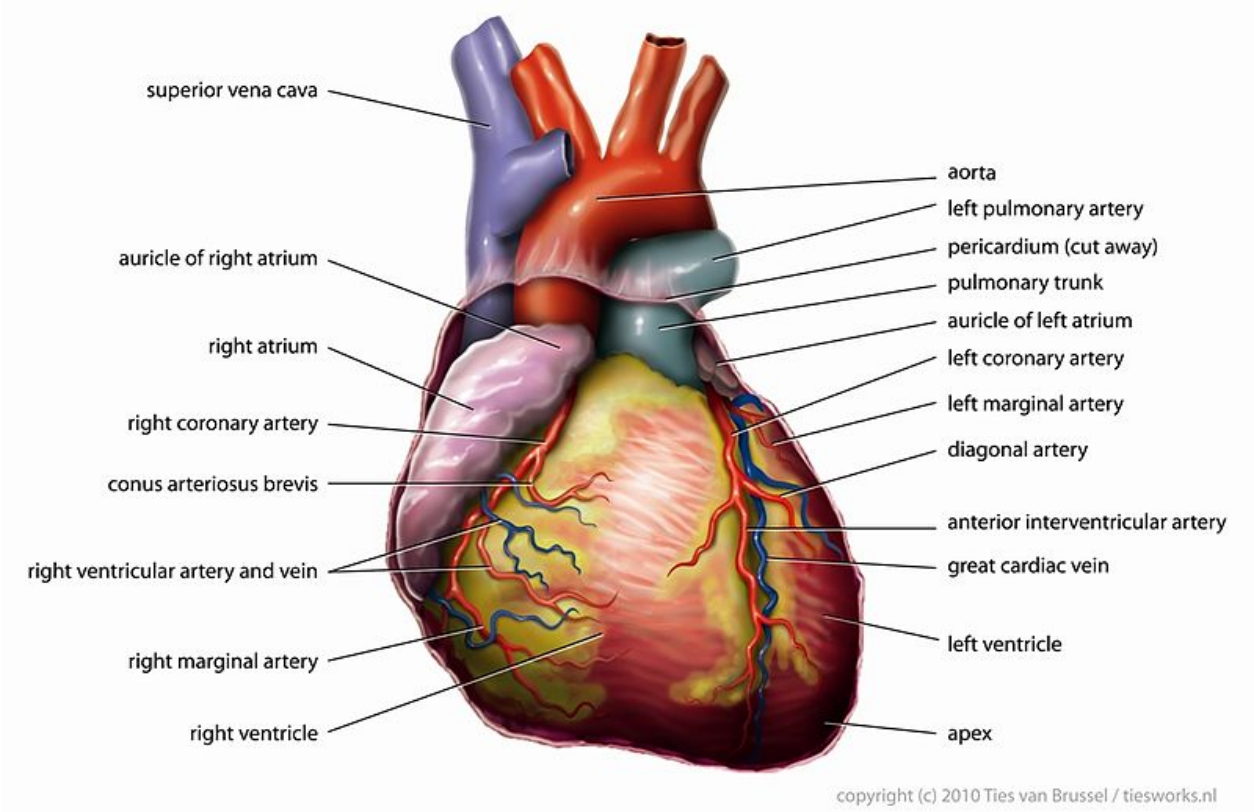

Figure 27. The external anatomy of the heart including major blood vessels (van Brussel, 2010).

Interior Anatomy

To expose the interior of the heart, you will need to bisect it along a frontal plane. Place your heart so that the right atrium and ventricle are facing up. Use the scalpel to make an incision through the right atrium, then down toward the apex of the heart. Turn your heart over and repeat the process by cutting through the left side of the heart, starting with the atrium and cutting downward through the thick wall of the left ventricle. If your cuts have not bisected the septum between the left and right ventricles, do that now, starting at the apex and working upward to the base of the heart.

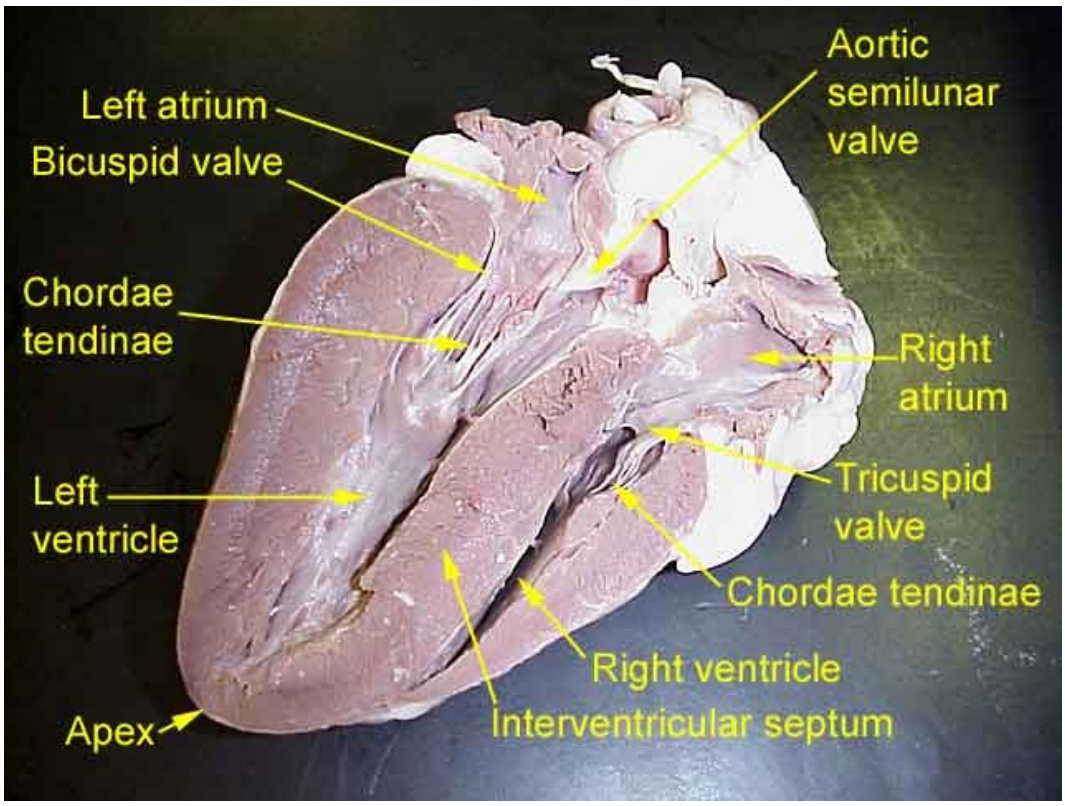

Figure 28. Some features of the internal anatomy of a sheep heart. (Niagara County Community College Virtual Anatomy Lab, 2003).

Begin by locating the four chambers of the heart. The easiest to identify is the large, thick-walled **left ventricle**. Directly opposite it is the smaller, thinner-walled right ventricle. At the apex end of these chambers, you will find thin whitish cords that run from the ventricular walls to the **atrioventricular valves**. These cords, known as the

chordae tendinae, help prevent prolapse of these valves. The enlargement of the ventricular wall that is the attachment for these cords is known as the **papillary muscle**. The anterior papillary muscle will also have attachments to the septum known as the **moderator band**. This reinforcement helps to keep the ventricular wall from overextending, and is important in conduction of electrical signals through the heart.

The atrioventricular valves appear as flaps at the top of the ventricles and separate them from the atria. The left atrioventricular valve is also known as the mitral valve or bicuspid valve. The right atrioventricular valve is also known as the tricuspid valve. The lining of the chambers has a smooth feel to it, so as to improve blood flow. In the emptied heart, this **endothelium** relaxes into ridges known as the **trabeculae carnae**.

Use a blunt probe to locate the arteries exiting from the ventricles. The **pulmonary trunk** exits from the right ventricle and branches almost immediately into the left and right pulmonary arteries. The **pulmonary semilunar valve** separates the ventricle from this vessel and prevents backflow of blood. The **aorta** exits from the left ventricle. It also has a valve to protect from backflow. Its valve is the **aortic semilunar valve**. Near the origin of the aorta, you should be able to find small **openings into the coronary arteries.**

The **atria** are at the base of the heart. Externally, you have already found the auricles. Internally they are located above the atrioventricular valves. Between the right and left atrium is the interatrial septum. You should be able to locate a thinner portion of this wall that is oval-shaped. This is the **fossa ovalis**, the remnant of the foramen ovale, which was the foetal opening between the atria. The walls of the atria will have distinct bands of muscle tissue, the **pectinate muscles**, to anchor and strengthen the outer wall.

Just as happened with the ventricles, you may find it easier to locate the vessels entering the atria by using a blunt probe. The **superior** and **inferior vena cava** enter the right atrium, while the **pulmonary veins** enter the left atrium. If your specimen is in good shape, you may be able to see all four of the pulmonary veins (two left and two right).

Once you have identified all of the associated structures, dispose of the remaining material as directed by your instructors. Rinse your instruments and place them in the container next to the sink at the back or side of the room. Rinse your dissecting tray and place it upside down (so it can drain) beside the sink.

Biology 1220

Laboratory Exercise 6: Exercise Physiology

In this lab you will investigate the effects of posture and exercise on cardiovascular and respiratory physiology. These systems are responsible for the delivery of oxygen and nutrients to muscles and other body structures. Muscle activity during exercise increases their demand for these substances. The cardiovascular and respiratory systems increase their activity to satisfy these demands. These systems also change their activity in response to other environmental effects. Even a change from lying down to standing up affects these systems as a result of the effects of gravity.

To investigate the effects of exercise and posture you will collect data on heart rate, blood pressure, blood oxygen, respiration rates and respiration volumes. Since we have limited pieces of some of the equipment, we will work with only 3 or 4 subjects who will carry out the exercise. The other students will collect the data from the subjects. Each subject will be tested under five conditions: resting while laying down, resting while sitting, resting while standing, immediately following mild exercise (rapid walking for 2 minutes) and following moderate exercise (stair climbing for 4 minutes).

Safety Procedures

- *Students volunteering as subjects should be physically fit and have no health problems that could surface as a result of exercise.*
- *Subjects should wear flat comfortable shoes and clothes suitable for exercise, including shirts with sleeves that can be rolled up well above the elbow to accommodate a blood pressure cuff.*

Techniques

Determining Heart Rate and Blood Pressure

These measurements can be obtained by traditional methods and with newer, electronic equipment. You will use a mixture of methods, depending on which equipment your team obtains.

Palpating the Radial Pulse

Place your fingertips (not your thumb, as it has a pulse) lightly over the radial artery in the ventrolateral region of the subject's wrist. Count the number of pulses in exactly 30 seconds and multiply by 2 for the number of heartbeats per minute. Repeat the count twice more and average the three values.

Palpating the Carotid Pulse

Place your fingertips lightly over the carotid artery in the anterolateral region of the subject's neck, just below the angle of the jaw. As with the radial pulse, count the number of pulses in exactly 30 seconds and multiply by 2 for the number of heartbeats per minute. Repeat the count twice more and average the three values.

Using a Manual Sphygmomanometer to Determine Blood Pressure

The sphygmomanometer consists of an inflatable rubber cuff connected by rubber hoses to a hand pump and to a pressure gauge (manometer) graduated in millimetres of mercury (mmHg). The cuff is wrapped around the upper arm snugly (but not tightly enough to obstruct venous flow), with the bottom edge about 2.5 cm above the antecubital space (hollow at the elbow) and with the stethoscope head located over the brachial artery on the inner side of the arm. The subject’s arm should be at about the height of their heart and resting quietly on a firm surface.

Raise the cuff pressure to about 150 mmHg. This is about 30 mmHg above the average systolic pressure and should be sufficiently high to pick up most subjects’ resting systolic pressure. After exercise you may want to inflate the cuff to a higher value such as 170 mmHg. In any case, do not maintain the cuff pressure at this level, as it can be quite uncomfortable for the subject. Release the pressure gradually, at a rate of about 2-3 mmHg per second, by opening the screw value adjacent to the hand pump. Listen for the Korotkoff Sounds.

Korotkoff Sounds

At rest, the blood normally flows through the arteries in laminar flow. That is, the fluid in the center part of the stream moves faster than the fluid in the peripheral layers, and there is very little transverse flow or mixing between the two layers (turbulence). Under these conditions the artery is silent when a stethoscope is used. When the cuff is inflated to a high pressure, the flow of blood is stopped and the artery is also silent.

As the pressure in the cuff is released gradually through the levels between systolic and diastolic pressure, the blood is pushed through between the walls of the flattened and compressed artery in a turbulent flow pattern. The layers of blood are mixed by eddies flowing at angles to the main stream, and the turbulence sets up vibrations in the arterial wall which are heard as sounds in the stethoscope. These are the sounds of Korotkoff.

As the pressure in the cuff gradually falls from the maximum, no sound should be heard at first. Note the pressure at which the first 'snapping' sound is heard. This is the **systolic pressure**. As the pressure in the cuff is reduced further the sounds first become quieter, then change to a louder tapping. With still further decreases in pressure, the sounds change again from a tapping sound to a muffled or blowing noise. The pressure at which this change occurs should be recorded as the **diastolic pressure**. Further reduction in cuff pressure leads to the total disappearance of any sound. If the systolic pressure is determined to be l20 mmHg and the diastolic 80 mmHg, the blood pressure is recorded as l20/80.

In some instances, you may not be able to detect the sound change that signals diastolic pressure. If this happens you should use the cessation of sound as your best estimate of diastolic, but be aware that the value will underestimate the true diastolic pressure.

Using A Digital Sphygmomanometer

This instrument is much easier to use than the manual version. It consists of a blood pressure cuff with stethoscope attached to an electronic unit that listens for the Korotkoff sounds for you. Place the cuff on the subject’s sleeve exactly as you would for the manual sphygmomanometer. Press the power button on the main unit. The cuff will slowly inflate, and then deflate. The instrument will provide the systolic and diastolic pressures and the heart rate from the brachial artery. Turn the instrument off after you have your reading.

The **pulse pressure** is a calculated value. It is the difference between systolic and diastolic pressures, e.g., l20 - 80 = 40 mm Hg.

The **mean arterial pressure** is also a calculated value. It is the diastolic pressure + l/3 pulse pressure, e.g., 80 + (l/3 x 40) = 93 mm Hg.

Using the Pulse Oximeters to Determine Pulse Rate and Blood Oxygen Levels

These instruments come in two styles, both of which measure pulse rate (beats / minute and blood oxygen (percent of oxygen saturation of functional arterial haemoglobin). One model is a larger hand-held instrument, while the second is a small fingertip sensor with a built-in electronic gauge. Both work on the same principles, measuring blood oxygen saturation and pulse based on fluctuations in the colour of the blood under the skin of the fingertip. Do not wear them while you are exercising, as they must remain still to provide accurate readings. The sensors should be at about chest level to provide the most accurate results. To get readings most reflective of the effects of exercise it is best to use values obtained within about ten seconds of placing the sensor on your fingertip. Longer time periods will allow for greater recovery, producing lower pulse rates and higher oxygen saturation levels.

Oxygen Saturation

Blood oxygen saturation is dependent on a number of factors including the amount of haemoglobin tied up by competitive inhibitors such as carbon monoxide, as well as the pressure inside the blood vessels, the pH and the temperature. Under normal conditions, there are about 15 g of haemoglobin in 100 ml of blood. This haemoglobin can combine with about 20 ml of oxygen under ideal conditions, in which case the blood is 100% saturated with oxygen. Any additional oxygen entering the bloodstream will be unable to combine with haemoglobin, since all molecules are fully occupied. The additional oxygen will instead remain in the form of dissolved gas molecules. Arterial measurements are typically in the 95% saturation levels, while the lowered pressures and altered pH in venous regions produce values that average in the 70% saturation level.

To use the hand-held sensor, begin by plugging in the fingertip sensor (if it is not already attached). Simply plug the 7-pronged cable into the top end of the machine. Turn it on by pushing the button marked with the vertical line. The arrow button is not needed as it simply changes the brightness of the display. The button marked with a zero is the off switch. Push it

when you are done, to conserve the batteries. Place your index, middle or ring fingertip into the sensor by bending the sensor gently open. Put your fingertip right to the end of the sensor. Keep your arm and hand relaxed and still to ensure maximum accuracy. Your finger should be placed in the sensor so that the connecting cable is on the nail side of the finger. If you have very long fingernails that prevent your finger from reaching the end of the sensor, inaccurate readings may occur. The final item to check is the perfusion sensor, which is the coloured light just above the on switch. This should blink green to indicate that accurate readings are being obtained. Either red or yellow lights indicate a problem. The readings will fluctuate over time.

The fingertip model is even easier to use. Simply insert a finger other than the thumb (the index finger is best) with the nail side up and pushed right to the end of the sensor. The unit will go through a short start up sequence and then display current readings. Once you remove your finger, the unit will turn itself off after a short period of time.

Experimental Procedures

A. Sitting

The subject should be seated comfortably for these counts. Practice recording measurements simultaneously: one student records blood oxygen, another records blood pressure, a third measures respiratory rate, and a fourth measures respiratory volume. Since these measurements should be stable, it is best to use an average of 3 separate measurements for your recorded value.

B. Reclining

Prior to this test the subject should lie down on a laboratory bench with eyes closed and relax completely for a period of 5 minutes before rates are determined. The subject has to keep lying down. **Do not stand up** before your partners are ready to take resting measurements.

Note: If all the measurements ***immediately after standing*** *cannot be obtained in one attempt (within about one minute), the subject should rest for another 5 minutes, then stand up to allow any additional measurements to be gathered. If you do repeat the procedure, try to get a second estimate of respiratory volume and use the average for your recorded measurement.*

C. Standing

Leaving the cuff in place, the subject should stand up, and measurements should be taken **immediately**. Count pulses for heart rate measurements for 15 seconds only (multiply by 4 for minute counts). Repeat blood pressure and heart rate measurements at 2 and 5 minutes after standing up. In each case record simultaneously heart rate, systolic and diastolic pressures, and calculate pulse and mean pressures. Stand in a relaxed manner in the intervals between counts, not absolutely still.

Note: if you miss a reading or are late taking the measurement, simply note the time that the reading was actually taken.

Table 13. Cardiovascular and Respiratory Measurements from Differing Postural Activities.

Measurement	**Supine**	**Sitting**	**Standing Still**	**After 2 Minutes of Standing**	**After 5 Minutes of Standing**
Heart Rate					
Diastolic Pressure					
Systolic Pressure					
Pulse Pressure					
Mean Arterial Pressure					
Blood Oxygen					
Respiratory Rate					
Corrected Respiratory Volume					
Respiratory Minute Volume					

D. Exercise

In this portion of the lab, you will investigate the effect that differing levels of exercise have on cardiovascular and respiratory indexes. You will measure the same items you used to investigate posture: heart rate, blood pressure, blood oxygen, respiratory rate and respiratory minute volume will be recorded before exercise, immediately after mild and moderate exercise and during the recovery from moderate exercise (while sitting). The measurements recorded **immediately** after exercise best illustrate what happens during exercise.

While **sitting**, record **pre-exercise** or **resting** measurements. If (and only if) you are short of time, you can use your values for respiratory rate and tidal volume from last week to substitute for these values. Once the resting values have been obtained, the subject should walk briskly for 2 minutes (lift your legs and swing your arms – this should be equivalent to power walking rather than a leisurely stroll). Immediately after exercise, the subject's partners should gather the various measurements. Try to get more than one estimate of respiratory volume and use the average measurement.

*Note: If all the measurements **immediately after exercise** cannot be obtained in one attempt (within about one minute), the subject should rest for 5 minutes, then repeat the same level of exercise to allow any additional measurements to be gathered. If you do repeat the exercise, try to get a second estimate of respiratory volume and use the average for your recorded measurement.*

The subject should rest for 5 minutes before conducting moderate exercise, which will consist of running up and down the stairs for 4 minutes. One of the subject's partners should accompany the subject, to keep track of elapsed time and to offer encouragement. At the end of 4 minutes of stair climbing, the subject should **run** (to keep cardiovascular stress high) back to their group to allow post-exercise measurements. Post-exercise measurements should be done while sitting. The respiratory rate should be based on a 30 second count and converted to breaths/minute. The respiratory volume measured should be the tidal volume. This is not truly a tidal volume measurement, since the tidal volume is the amount of air moved during relaxed events. By tidal volume here I mean that you should not force the breath in or out. Breathe as naturally as possible. The aim is to measure the amount of air that your body wants in response to the demands of exercise.

Note: If all the measurements ***immediately after exercise*** *cannot be obtained in one attempt (within about one minute), the subject should rest for 5 minutes, then repeat the same level of exercise to allow any additional measurements to be gathered. If you do repeat the exercise, try to get a second estimate of respiratory volume and use the average for your recorded measurement.*

At 2 minutes and 5 minutes after exercise, during the recovery period, the group should again gather measurements from the sitting subject.

Note: if you miss a reading or are late taking any of these recovery measurements, simply note the time that the reading was actually taken.

Table 14. Cardiovascular and Respiratory Measurements from Differing Exercise Activities.

Measurement	**Before Exercise**	**Immediately After Mild Exercise**	**Immediately After Moderate Exercise**	**2 Minutes After Exercise**	**5 Minutes After Exercise**
Heart Rate					
Diastolic Pressure					
Systolic Pressure					
Pulse Pressure					
Mean Arterial Pressure					
Blood Oxygen					
Respiratory Rate					
Corrected Respiratory Volume					
Respiratory Minute Volume					

Notes regarding the laboratory report

This report, if required by your instructor, will follow the format in the appendix section on formal laboratory reports. There are several important issues to address in the various sections of this particular report.

Introduction

The background information for this section should include material detailing the basic processes involved in circulatory and respiratory function. You should discuss the heart rate and how it is regulated, important mechanisms involved in maintaining and regulating blood pressure, breathing rates and volumes and their regulation, and the ways in which exercise and gravity affect cardiovascular and respiratory demand (mostly dealing with oxygen demand) and how our body recovers from increased demand.

Hypotheses for this report should include predictions about:

- the effects of posture on heart rate, diastolic and systolic blood pressure, and respiratory minute volume
- the effects of mild and moderate exercise on heart rate, diastolic and systolic blood pressure, respiratory rate and respiratory minute volume.

Results

For this report, you should include clean versions of the data tables. These will be based on the **pooled data** from all of the subjects, not that from one individual. Show average values from this pooled data in the summary tables. Remember that the caption for a table goes above the table while the caption for a figure such as a graph goes below the figure.

In addition to the two data tables, you will need to produce a series of graphs. The graphs should have the average values connected by a line. As with previous labs, just connect the values, as our data is too meagre to provide a good estimation of a line of best fit. Around each average value should be vertical error bars with a range from the minimum subject value to the maximum subject value. Also include the value of your group's subject. These should include graphs of:

- the effects of posture on heart rate
- the effects of posture on blood pressure, both systolic and diastolic.
- the effects of posture on respiratory minute volume
- the effects of exercise and recovery on heart rate
- the effects of exercise and recovery on diastolic, systolic and mean arterial blood pressure
- the effects of exercise and recovery on respiratory rate
- the effects of exercise and recovery on respiratory minute volume

Don't forget that the results section should include a text portion as well as summary figures and tables. The text should introduce the tables and graphs and include a short (usually one or two sentences) explanation of important factors such as trends in the data and changes in variation. As usual, do not attempt to explain the meaning behind the results, just report the facts.

Discussion

In this section you will interpret your results and discuss sources of error. Incorporate answers to the following questions into your discussion. Do not list them as a separate part of the lab report.

1. Did your results agree with your hypotheses? Explain your results in light of your hypotheses.

2. Relate your results to the background information in your introduction. The role of oxygen flow to the tissues should be one of the important focal points to your explanation. Compare the changes in respiratory volumes, heart rate, blood pressure and blood oxygen to each other. How and why do changes in one influence the others?

3. Relate your results to the real world. What is the importance of postural changes in cardiovascular and respiratory function? What are the implications of our responses to exercise and recovery? Describe and account for differences in these changes between a trained athlete and a sedentary person. What are the physiological effects of other lifestyle

differences such as diet or smoking? What are the implications of factors such as age or sex or genetics?

4. Discuss the differences between the four measures of blood pressure. What factors is each an index of and why would some respond differently to physical challenges than others

5. Compare the differences in respiratory rate and respiratory volume with those for respiratory minute volume. Which factor played the larger role in changes in gas exchange? Why might this be the case?

6. How would the responses in heart rate and blood pressure on standing up be altered if one stood very still? Explain. Why could fainting occur if one stood still for a long time? How would fainting correct the situation?

7. What were the sources of error in this experiment? What were the sources of instrumental error (inaccuracies in measuring devices and other equipment) and procedural error (problems with performance of the experiments)? What role did biological variation play in the results? In all cases, be specific. Avoid vague terms like human error.

Biology 1220

Laboratory Exercise 7: Haematology

In this lab, we will look at the components of blood. Doctors often use analysis of blood samples as a diagnostic procedure. By examining blood samples, we can gather information about many physiological conditions including nutrition, infection, cancer and genetic conditions. A variety of blood tests are used routinely to provide information not only for diagnostic purposes but also for monitoring the course of disease or the effects of drug treatment. These tests reveal defects in numbers and morphology of the blood cells.

The procedures we will use will be standard manual techniques for estimating the erythrocyte and leukocyte fractions of blood. They are only a small subset of the full battery of tests that would normally be carried out in a routine blood test. In addition, the procedures we are using have been largely replaced in large-scale facilities by automated procedures, but our techniques are still used in a wide variety of small clinical environments.

In this lab, you will work primarily with animal blood, but for certain tests it may be possible to use human blood. As a result, caution must be taken to prevent any chance of infection, no matter how slight. Read the following safety procedures carefully. Check with your instructors before handling any human blood or attempting to draw blood.

Safety Procedures

- Handle blood with care as it can transmit infectious diseases.
- Any students using human blood must wear examination gloves.
- Wear your safety goggles throughout this lab exercise
- If you have any open cuts on your hands, or anywhere that blood contamination could occur, do not handle blood.
- Never pipette blood or blood by-products by mouth.
- Carry out your work on paper towels or other protective materials such as dental bibs, to avoid spilling chemicals and blood on the bench.
- If you spill blood wipe it immediately with soap and rinse with tap water.

At the end of the lab:

- Wipe your bench and your microscope to remove any blood stains
- Wash your glassware with detergent and rinse it thoroughly with tap water. Rinse haemocytometer slides with distilled water. Let it dry on paper towels at the rear bench.
- Place any blood-contaminated materials in the biological hazard containers in the lab. Place any sharp-edged contaminated materials such as lancets, glass cover slips, and slides (but not the haemocytometers) in the sharps containers in the lab.
- Remove your gloves and goggles and wash your hands.

Experimental Procedures

A. Red Blood Cell Count

Any reduction in the total amount of haemoglobin in the blood is known as **anaemia**. **Polycythemia** is an abnormally high level of red blood cells. In some cases, it occurs as a result of increased erythropoietin release stimulated by hypoxemia due to high altitude (where the oxygen content of the air is reduced), or by heart failure or pulmonary disease when oxygen delivery to the tissues is below normal. One of the most basic components of a blood analysis is to count the red blood cells per cubic millimetre to detect any of these conditions.

To conduct a red blood cell count, you will dilute a known volume of blood and then place the mixture into a counting chamber of known volume called a **haemocytometer**, as shown in Figure 29. There are so many red blood cells in the blood that it would be impossible to count them in pure blood, so the blood must be diluted to decrease their number. The cells are counted by microscopic inspection, and corrections for dilution and volume are made to obtain the result in cells per cubic millimetre (microlitre) of blood.

Erythrocyte counting is a routine method. The basis of all counting methods is the dilution and preparation of a blood sample of known volume. The required cell type in a defined volume is counted and the number of cells per microlitre of blood is then calculated.

The haemocytometer **counting chamber** is a special thick glass slide with a central platform, divided in two and surrounded by gutters. The platform is exactly 0.l mm below the surface of the slide. When the special thick (and expensive) cover slip is placed on the slide, a chamber 0.l mm deep is formed. In the centre of each half of the platform is an engraved area 3 mm x 3 mm (9 mm^2). It is divided into 9 equal areas, each l mm^2. The central area is further divided (by triple lines) into 25 equal squares. Each of these squares is again divided into l6 very small squares. These smallest squares each have an area of 0.0025 mm^2.

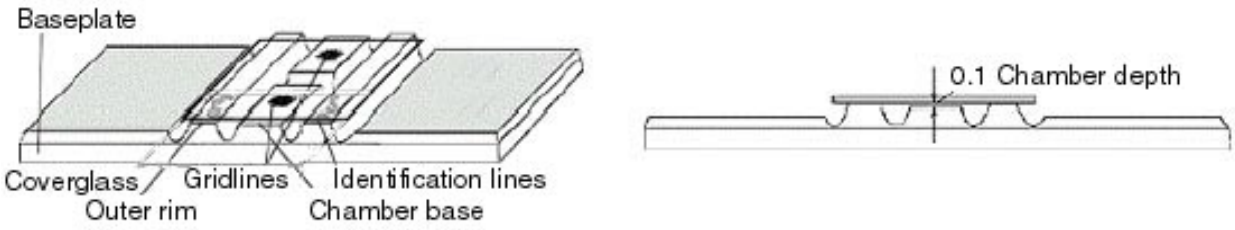

Figure 29. A Nebauer Haemocytometer showing major components of the instrument and a side view to illustrate the depth of the counting chamber.

Equipment:

- sheep blood in a small beaker
- distilled water
- isotonic saline solution
- erythrocyte capillary diluting pipette and pipette bulb
- haemocytometer and coverslip
- Kimwipes or lens tissue
- compound microscope
- hand counter

Beakers with red blood in a dilution of 1:200 should be available as well. If this is not available, the following procedures can be used to produce this dilution:

1. Examine the diluting pipette for red blood cell determinations (Figure 11). Note the colour of the agitating bead in the central filling chamber. It should be red. The lower stalk of the pipette has marks at 0.5 and 1.0, which are used for 1:200 and 1:100 dilutions of red blood cells, respectively. For our purposes, you should use a 1:200 dilution.

2. Filling the pipette is a bit of an art form and requires both capillary action and suction. You may use either a simple pipette bulb or a valved pipette bulb. For the valved pipette bulb, evacuate air from the bulb by squeezing **both** the large bulb and valve (enlarged portion of the stem) labelled with an up arrow. You will draw air or fluid into the pipette by squeezing the up arrow again. You can evacuate the pipette by squeezing the down arrow valve. Place either type of pipette bulb onto the short-stalked end of the diluting pipette. Do not push the bulb past the filling line near the reservoir of the pipette. Squeeze the bulb of a simple pipette bulb to evacuate air from the bulb.

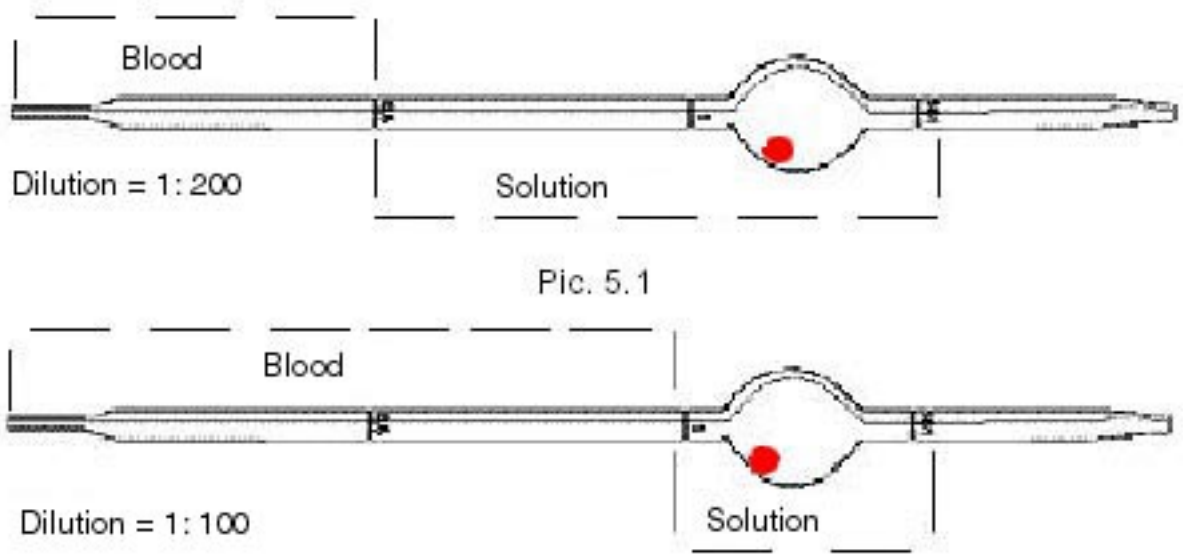

Figure 30. Erythrocyte Diluting Pipettes showing filling points for erythrocyte counting dilutions of 1:100 and 1:200.

3. Gently agitate the beaker of blood to eliminate any settling of cells to the bottom of the beaker.

4. Place the tip of the pipette into the blood. Keep the pipette bulb evacuated. The blood should flow into the pipette by capillary action only. Allow the blood to climb the pipette until it reaches the 0.5 mark. **Do not** use the pipette bulb to draw blood up into the pipette. If the blood goes slightly past the mark, remove the pipette from the blood and touch the tip to a Kimwipe. This should draw a small amount of blood back out of the pipette. When you have the correct amount of blood, remove the pipette from the blood and carefully wipe any excess blood from the pipette's surface with a Kimwipe.

5. Place the tip of the pipette into a small beaker containing isotonic (0.9%) saline solution. **Gently** draw saline up into the pipette by using the pipette bulb until the fluid reaches the fill mark just above the reservoir (Figure 11). **Do not** draw the fluid up too aggressively or you will overshoot the mark, contaminate the pipette bulb, and get an inaccurate dilution.

6. Place your fingertip over the end of the pipette and remove the pipette bulb. Mix the contents of the reservoir chamber by gently agitating the pipette horizontally with your

fingertips covering both ends. Do not shake it up and down along the longitudinal axis of the pipette or you will lose a portion of the contents. Continue shaking the fluids for 30 seconds.

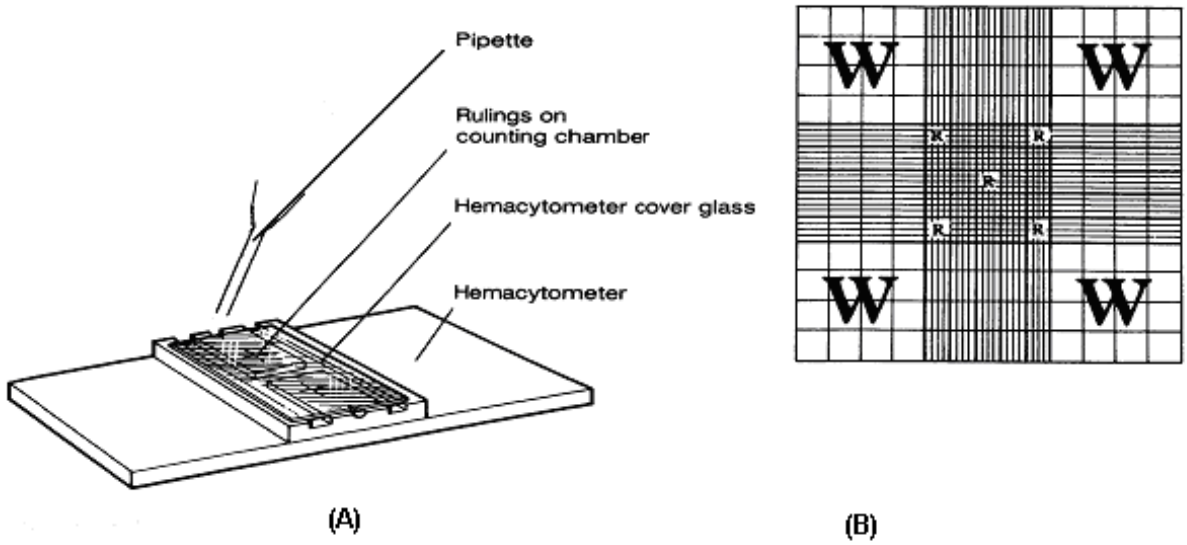

Figure 31. A Nebauer Haemocytometer. Illustration A shows the location for the coverslip and the positioning of the pipette tip to fill the counting chamber. Illustration B is an enlargement of the counting grid. Typically, the four squares marked W are counted for a white blood cell count, while the five squares marked R are counted for a red blood cell count.

7. Wipe the cover of the haemocytometer and position it as shown in Figure 31.

8. Touch the end of the pipette to a Kimwipe to draw out the contents of the capillary stem. This will ensure that you use only the mixed contents of the reservoir. Now touch the tip of the pipette to the angled notch at one side of the counting chamber so that you can deposit a small drop of the diluted specimen onto the polished surface of the counting chamber. Just fill the chamber, being careful not to let fluid leak over into the gutter or allow the chamber to overfill. If the chamber overfills, fill the other side of the chamber. If you do not succeed (this is also a bit of an art form, although easier than filling the diluting pipette), wash the haemocytometer and its cover with warm water and soap, rinse thoroughly with distilled water, wipe it dry and try again.

9. Carefully, place the charged haemocytometer on the microscope stage, and focus with the

low-power objective to bring the small (R) grid areas into clear view. These grids are illustrated in figure 2g.

10. Move the high-power objective (40 power) into place, and count the number of cells in each of the five specified areas. It may be necessary to wait a few minutes before counting to permit the cells to settle. Each square you will count consists of sixteen smaller squares. There will be a triple line around the edge of each sixteen-part square. The middle of these three lines is the actual edge of the counting grid. In order to deal with cells sitting right on the boundary of the squares you should use a simple rule of thumb to determine which cells to include in your count. On the edges of the squares, count only the cells that touch the lines on the top and left sides. Omit the cells touching the lines at the bottom and right sides.

11. Rinse the haemocytometer thoroughly with distilled water and wipe it dry.

12. **Calculations:** Calculate the number of red blood cells per mm^3 in sheep and human blood.

Each tiny square has an area of 0.0025 sq. mm. and a depth of 0.l mm so the volume is 0.00025 mm^3.

80 (5 x 16) squares are counted, so the total volume is 80 x 0.00025 = 0.02 mm^3.

The number of cells per mm^3 in the diluted blood is N x (1/0.02) = N x 50

(N being the number of cells counted in the 5 RBC squares of the haemocytometer)

Since dilution in the pipette was l: 200, this factor must be multiplied by a further 200.

N x 50 x 200, or N x l0, 000 = number of RBC per mm^3 of whole blood.

13. Record your results in Table 1. Although we used sheep blood, Table 1 also includes results obtained from human male and female subjects. Calculate the red blood cell counts for the sheep and the human male and female.

Table 15. Red Blood Cell counts using a haemocytometer and a 1:200 dilution with isotonic saline in an erythrocyte diluting pipette. Counts for humans are based on average values.

Blood	**Sheep**	**Human Female**	**Human Male**
Red blood cells counted in the 5 red blood cell squares of the haemocytometer		460	540
Red blood cell count (number of red blood cells in 1 mm^3 of blood)			

B. White Blood Cell Count

Neutrophils are the most common of the white blood cells. The cytoplasm of a neutrophil has numerous fine lilac-coloured granules, which sometimes are hardly visible. The nucleus is dark purple or reddish purple, and it may be oval, horseshoe-or-S shaped, or segmented (lobulated). The neutrophil is further subclassified according to age. Young neutrophils are known as band neutrophils since their nuclei are still in a single band and have not fully lobulated. **Eosinophils** are fairly rare. They often have a bilobed nucleus, but are best distinguished if you can detect the orange to reddish colour of their grainy cytoplasmic layer. **Basophils** are also very rare. They, like eosinophils, also commonly have bilobed nuclei. The large dark-blue granules filling their cytoplasm, however, often obscure their nuclei.

The cytoplasm of a **lymphocyte** is bluish in colour and fairly thin, with a few unevenly distributed granules. The granules will often have a light-coloured halo around them. Large white blood cells with normal shaped nuclei and a thicker cytoplasm layer, again with few cytoplasmic granules are **monocytes**. Their colour resembles that of a lymphocyte, but their cytoplasm is a muddy grey-blue.

The methods used to count white blood cells are similar to those used for the red blood cell count with a few differences.

1. The white and red blood cell diluents differ. The white blood cell diluent haemolyses the red blood cells so they will not interfere with the white blood cell counting process. Common diluents for this purpose include weak acetic acid, ammonium chloride, ammonium oxalate and others.

2. The white blood cells are less common than erythrocytes so less dilution is needed. Dilutions ranging from 1:10 or 1:20 up to 1:100 are common. We will use a 1:20 or 1:100 dilution.
3. The number of cells will be counted in each of the four corners of the haemocytometer grid marked W in Figure 31.

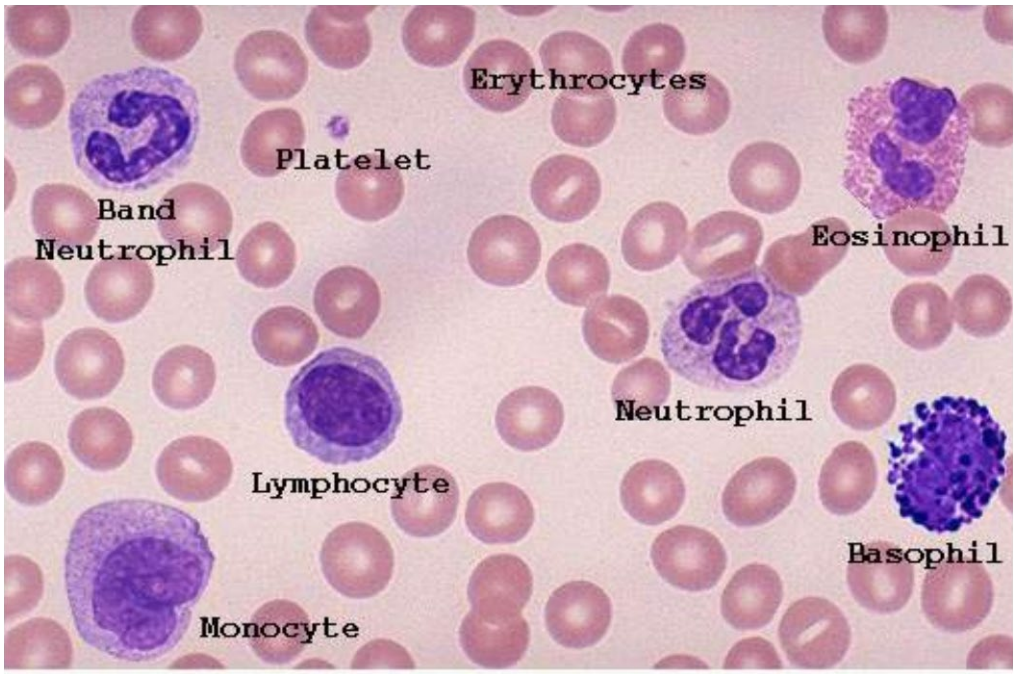

Figure 32. The appearance of leukocytes, erythrocytes and platelets in a normal human blood smear that has been enhanced with Wright's stain. In practice, it is unlikely to find a single field of view containing all of the leukocyte varieties. Magnification is 1000X.

Equipment:

- Sheep or other animal blood in a small beaker
- Sterile lancets for human blood collection (if desired and approved by instructor)
- Alcohol swabs for sterilization
- Haemocytometer and coverslip
- Kimwipes or lens tissue
- Compound microscope
- Hand counter
- Distilled water
- Leukocheck reservoir and pipette
- White blood cell diluting pipette and pipette bulb (if not using Leukocheck system)
- 1% acetic acid solution or other diluent (if not using Leukocheck system)

Using a Leukocheck system for dilution.

This equipment consists of a reservoir and a capillary pipette assembly. Note that this method typically uses a dilution of 1:100. Adjust your calculations appropriately

1. Puncture the top of the reservoir using the pointed tip of the cover on the pipette assembly.
2. Remove the cover from the pipette and use the pipette to draw up blood. Make sure the pipette is completely filled.
3. Hold the reservoir and squeeze lightly to evacuate some air from the chamber. This will create a mild suction. Maintain the pressure on the reservoir and insert the pipette into the reservoir. Keep a finger over the top of the pipette to prevent any leakage during mixing.
4. Release the pressure on the reservoir to draw the blood from the pipette down into the diluent inside the reservoir. Keep the top of the pipette assembly covered and again squeeze the reservoir lightly to help mix the blood and diluent. Invert the reservoir several times to further mix the materials.
5. Remove the pipette assembly from the reservoir and reattach it in the reverse direction, with the pipette tip protruding from the reservoir. You can now use the assembly as a dropper to fill the haemocytometer chambers.

Figure 33. Leukocyte Diluting Pipettes showing filling points for white blood cell counting dilutions. The marking shown is actually for a dilution of 1:20. The area marked with Leukopur will be filled with weak acetic acid.

Alternative procedure using a diluting pipette for dilution.

Follow steps 1 to 8 of the diluting procedure for red blood cell counts with a diluting pipette, but use the diluting pipette designed for white blood cell determination and 1% acetic acid solution as a diluent. The leukocyte pipette should have a white agitating bead in the central reservoir.

Carrying out the white blood cell count.

1. Place the haemocytometer on the microscope stage. With the low power objective, focus on the chamber area to bring the four large (w) corner regions into view (see figure 2g).
2. Determine the number of cells in each of the four specified areas. As before, on the edges of the squares, count only the cells that touch the lines on the top and left sides. Omit the cells touching the lines at the bottom and right sides. It may be necessary to wait a few minutes before counting to permit the cells to settle.
3. Rinse the haemocytometer with distilled water and wipe it dry.
4. Record your results in table 16. As before we added typical results obtained from human blood. Calculate the white blood cell counts for the sheep and the human male and female.

<u>Calculations</u>:

Each of the 4 W squares has an area of $1mm^2$ and a depth of 0.1 mm.

The total volume is $4 \times 1 \times 0.1 = 0.4\ mm^3$.

The number of cells per mm^3 in the diluted blood is: $N \times (1 / 0.4) = N \times 2.5$

(N is the total number of cells counted in the four squares)

Dilution was l:20, so there are $N \times 2.5 \times 20 = N \times 50$ white blood cells per mm^3 of blood. If a higher dilution of 1:100 was used, the value would be $N \times 250$ cells per mm^3 of blood.

Table 16. White blood cell counts obtained using a haemocytometer and a 1:20 dilution with 1% acetic acid solution in a leukocyte diluting pipette. Counts for humans are based on average values. The values for human females and males will be 29 and 28, respectively, if a 1:100 dilution is used.

Blood	**Sheep**	**Human Female**	**Human Male**
White blood cells counted in the 4 white blood cells squares of the haemocytometer		145	140
White blood cells count (number of white blood cells in 1 mm^3 of blood)			

C. Haematocrit Measurement

The **haematocrit** is the volume of packed red cells found in 100 ml of blood and is usually recorded as a percentage. It is routinely determined in hospital and is useful in diagnosing problems such as anaemia. Centrifuging blood causes the formed elements to spin to the bottom of the tube, with **plasma** forming the top layer. Since the blood cell population is primarily red blood cells, the packed cell volume is often considered equivalent to the red blood cell volume although this is not strictly true. A thin whitish layer can be seen between the clear plasma and red cell mass. This represents the leukocyte fraction and platelets and is called the **buffy coat**. A more accurate measurement of packed cell volume would include this layer.

Equipment:

- Sheep or other animal blood in a small beaker
- heparinized capillary tube
- capillary tube tray with plasticine
- centrifuge with head for capillary tubes
- ruler

1. Gently agitate the beaker of blood to eliminate settling of blood cells to the bottom of the beaker.
2. Hold the red-line-marked end of the capillary tube slightly below the surface of the blood and allow the tube to fill at least three-fourths full by capillary action.
3. Plug the blood-containing end by pressing it into the plasticine.

4. Tubes from several groups will be centrifuged simultaneously. Place the tube in the centrifuge **with the plugged end pointing OUT**. If the open end points out, the blood will spray everywhere due to centripetal acceleration. You will not only lose your sample but also make a mess of the centrifuge. Tubes have to be opposite to one another in the radial grooves of the centrifuge in order to balance the centrifuge. Make a note of the location of your tubes.
5. Centrifuge at 12,000 rpm for 4 minutes.
6. Examine the tube. Note the colour of the plasma. Locate the buffy coat, the thin whitish layer that lies between plasma and red cells. This consists of platelets and white cells.
7. Measure the height of the total blood column and of its separate components with a ruler. The haematocrit is calculated by using the following formula:

$$\frac{\text{Height of column composed by the formed elements (mm)} \times 100}{\text{Height of the original column of whole blood (mm)}}$$

The same approach is used to calculate the thickness of the buffy coat.
The **mean cell volume** can now be calculated as well. This is the average size of red blood cells. In the formula below the result will be in mm^3 per red blood cell. In medical reports the value is usually expressed in femtolitres (1 femtolitre = 10^{-15} litre or 10^{-18} m^3). A typical human value would be 80 to 100 femtolitres per red blood cell. Mean cell volume is calculated by dividing the haematocrit by the number of red blood cells:

$$\text{MCV} = \frac{\text{haematocrit}}{\text{\# RBC}}$$

NOTE: If the haematocrit = 40%, then write 0.4 in the equation, not 40.

Record your results in Table 17. If you would like to convert your MCV value to femtolitres multiply the number in Table 17 by one billion (10^9).

8. Place the used tubes into the container at the side bench marked for this purpose.

Table 17. Haematocrit and buffy coat of sheep blood obtained by height determination from centrifuged blood. The derived value for mean cell volume is also included.

	Sheep Blood
Haematocrit (%)	
Buffy Coat (%)	
Mean Cell Volume (mm^3/RBC)	

D. The Differential White Cell Count

A decrease in the number of white blood cells, **leukopenia**, may involve all cell types, but it is usually the result of a decrease in numbers of only one type, such as neutrophils. Such decreases may be the result of acute or chronic infection, radiation therapy, acute or chronic stress, endocrine disorders, excess alcohol or drug treatment.

An increase in white blood cells is known as **leukocytosis**, and may involve all white cell types or be restricted to one sort. Increases may be caused by **leukemia**, a malignant proliferation of white blood cells in the bone marrow or lymphoid tissues, or by infections, inflammatory or allergic diseases.

Neutrophils increase in bacterial diseases, in non-infectious inflammatory conditions such as rheumatic fever, burns and with stress due to heat, cold, etc. or emotional stimuli. An increase in **eosinophils** is associated with allergic reactions (hay fever, asthma), and parasitic infections. **Basophils** are rarely elevated except in certain kinds of leukemia. **Lymphocytes** increase in viral infections (whooping cough, infectious mononucleosis) and in some chronic bacterial infections.

Equipment:

- prepared microscope slides of human blood smears, normal and pathological.
- clean microscope slides
- slide beaker containing Wright's stain
- slide beaker containing water
- compound microscope with mechanical stage

1. Examine the normal blood smear provided and locate the tapered end, where the smear is thinnest.
2. Examine the slide under medium power, noting the distribution of white blood cells (tiny blue dots). Note that the larger white cells may be more numerous at the edges of the smear. Study the slide under high power and learn to identify the five kinds of white blood cells.
3. Turn to high power. Classify and tabulate each white blood cell you see. Don't waste too much time trying to identify cells, but do make a guess as to the identity of all cells you see. Count the different types of leukocytes by moving back and forth across the field from margin to margin of the smear in a regular pattern. Counted fields should not overlap but it doesn't matter if they don't meet exactly. See Figure 5 for a suggested pathway to move the field of view. Tally a total of **l00 cells.** It is quite possible that you may find no basophils and possibly no eosinophils in a single sample of 100 cells. Record your results (expressed as percent of total) for each white blood cell type in Table 18.

4. Examine one of the pathological smears of leukemia under medium power. Turn to high power (40 power objective lens). Classify and tabulate each white blood cell as described in step 3. Record your results for each white blood cell type in Table 18.
5. If time permits, you may try to produce your own Wright-stained blood smear using sheep blood or your own blood (check with your instructor before attempting to draw blood). To make a blood smear put one drop of blood about one quarter of the way from edge of a clean microscope slide so that it is located at about the location of the narrow end of the smear as shown in Figure 34.
6. Use a second clean microscope slide to smear the blood across the first. The procedures for this are shown in Figure 34. The completed smear should be thin but continuous across the area of the slide.

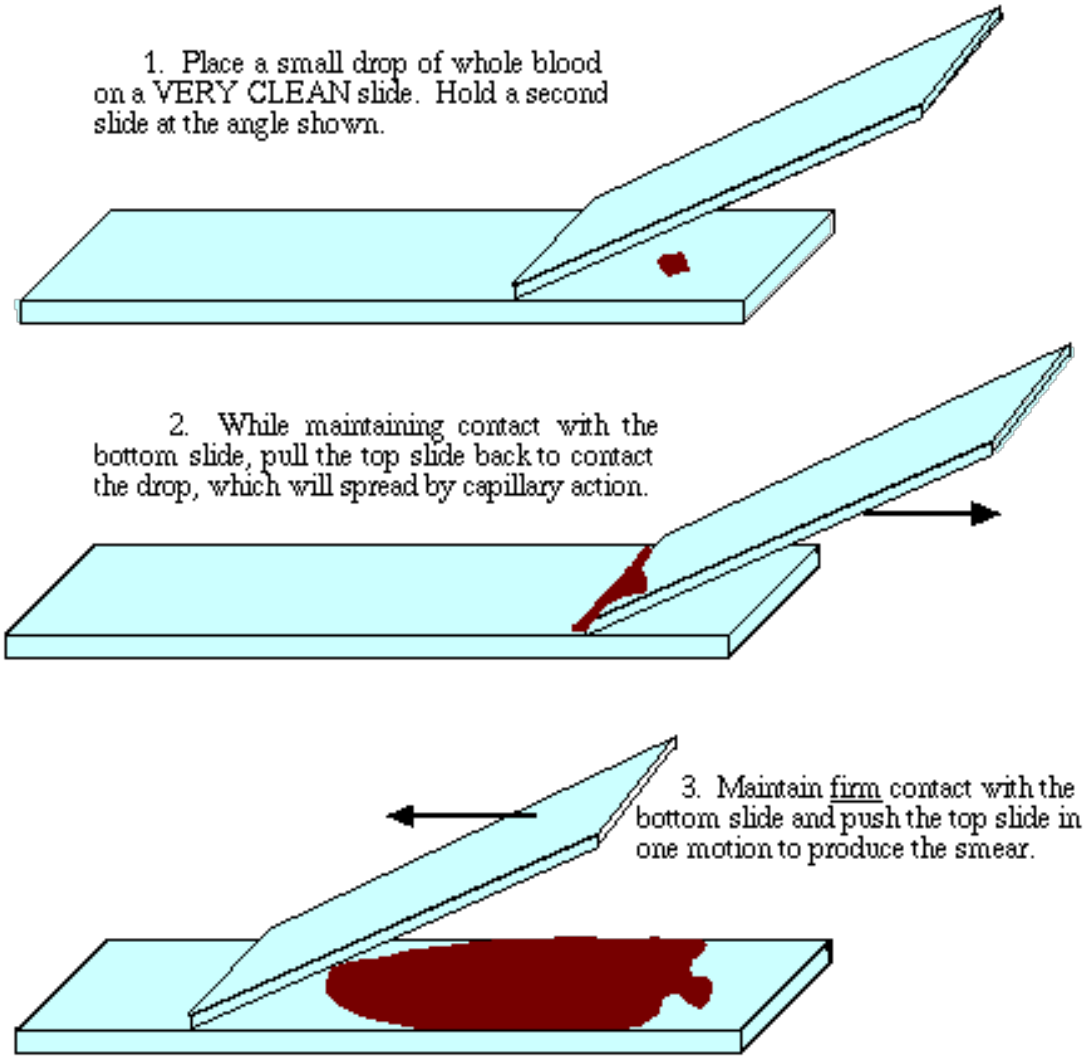

Figure 34. Procedures for making a blood smear slide. (Caprette, 2000).

7. Allow the smear to air dry. This will take several minutes. Once it is dry (and only when it is dry) dip the smear into a slide beaker containing Wright's stain. Leave the slide immersed for about 3 minutes.

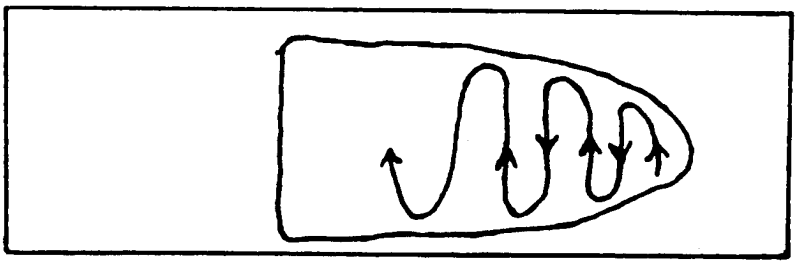

Figure 35. Diagram showing a suggested scanning pattern to carry out a differential white blood cell count. The rounded triangle illustrates the edges of a blood smear and the arrows show the suggested movements of the field of view to systematically count one hundred white blood cells.

8. Remove the slide from the stain and transfer to a slide beaker containing water for another 3 minutes. Remove the slide from the water and allow it to air dry in a vertical support, such as an empty slide tray. The slide should now be ready for viewing.

Table 18. Differential white blood cell counts on normal and pathological blood.

	Neutrophils	Eosinophils	Basophils	Lymphocytes	Monocytes
Normal Blood					
Pathological Blood					

Notes for the Haematology Lab Report

If required by your instructor, this report will follow the format presented to you in the appendix section on formal laboratory reports. There are several important issues to address in the various sections of this particular report.

Introduction

In the introduction to this report, you will need to discuss the components and function of blood. This should include material on immune functions and immune disorders of the blood such as anaemia and leukemia. You should also discuss the theory and practice of analysing blood samples in a clinical environment.

This laboratory report has hypotheses that are fairly self-evident. In all cases the hypotheses should be that blood measurements are within the normal ranges for a healthy individual. For pathological conditions, the hypotheses are that measurements will be outside of these ranges. For specific blood disorders you should specify whether you expect values to be higher or lower than normal.

Results

Provide a **summary table** showing your values for red blood cell count, white blood cell count, haematocrit and mean cell volume for the sheep, human males and human females. Your table should also include the class averages, minimum and maximum values for these values for the sheep, based on pooled class data.

On millimetre graph paper or using a computer, **draw a bar graph** to show the differential white blood cell count (expressed in percentage of total white blood cells) in normal human blood and in blood of patients with pathological blood conditions. Use pooled class data for these values. Each bar should be based on a class average, with error bars from the maximum class value to the minimum class value. For some of the pathological data there may only be one set of data. Indicate your own data as a mark along the error bars for each bar as appropriate to the blood that you counted.

The text section of the results should include explanations (but not interpretations) of the table and graph including descriptions of trends and variation.

Discussion

In this section you will interpret your results and discuss sources of error. Incorporate answers to the following questions into your discussion. Do not list them as a separate part of the lab report.

1. Did your results agree with your hypotheses? Explain your results in light of your hypotheses.

2. Relate your results to the background information in your introduction. Compare class values to criteria values from the literature. Discuss reasons for any differences.

3. Relate your results to the real world. What is the importance of differences in blood cell fractions in health and disease? What are the implications of factors such as sex or age or genetics? Describe and account for differences in these values related to lifestyle differences such as diet, exercise or smoking.

4. What are the implications of environmental factors such as air quality and altitude on these measurements? For example, endurance athletes such as marathon runners sometimes train at high altitudes prior to an event. After such training, their RBC count, haematocrit and haemoglobin concentration increase. Why? What are the advantages of such changes? What role would blood doping play and how long would the effects last?

5. Discuss the effects of pathological conditions such as anaemia, infectious mononucleosis and leukemia on blood values and how they will affect functions such as oxygen transport and immunity. You do not need to mention all possible types of anaemia and leukemia but should include representative diseases such as iron-deficiency anaemia, sickle cell anaemia, acute and chronic leukemias at least.

6. What were the sources of error in this experiment? What were the sources of instrumental error (inaccuracies in measuring devices and other equipment) and procedural error (problems with performance of the experiments)? What role did biological variation play in the results? In all cases, be specific. Avoid vague terms like human error.

Biology 1220

Laboratory Exercise 8: Blood Typing

Matching blood types for transfusions and other procedures such as transplants is an essential part of modern medicine. The procedures are designed to provide information on cell recognition proteins and glycoproteins found on the surface of red blood cells. These proteins are used by the immune system to identify cells that belong to the body. Cells with foreign proteins can be identified as foreign and attacked by immune structures including phagocytic white cells, T cells, natural killer cells, complement and of course antibodies.

The standard blood typing procedures rely on antibody reactions to these surface proteins. There are various groups of identifying proteins used in blood typing. In addition to the well-known blood types of A, B, AB and O, and Rh (Rhesus) positive or negative, there are a number of lesser-known proteins as well. Currently, there are over 30 recognised blood types. Lesser-known blood typing categories include the MNS system which includes over 40 different surface antigens, the Diego blood types, Kidd blood types, Duffy blood types, Kell blood types and H blood types. To identify and deal with this variety of blood types, patients needing transfusions or transplants will have their blood tested in what is known as blood typing and cross matching. Blood typing is used to identify the ABO group and Rh group to which the patient's blood belongs. Rather than trying to identify all of the lesser blood types, the blood is then cross matched. In this procedure a small amount of the patient's blood is mixed with a small amount of the donor's blood. Once the two blood samples are mixed, they are checked for signs of antibody reactions. If no reaction occurs, then the blood types are compatible across the spectrum of various blood types.

The procedures we will use will be standard manual techniques for blood typing.

In this lab activity, you will work with human blood. As a result, caution must be taken to prevent any chance of infection, no matter how slight. Read the following safety procedures carefully. Check with your instructors before handling any human blood or attempting to draw blood.

Safety Procedures

- Handle blood with care as it can transmit infectious diseases.
- All students using human blood must wear examination gloves and safety goggles.
- If you have any open cuts on your hands, or anywhere that blood contamination could occur, do not handle blood.
- Never pipette blood or blood by-products by mouth.
- Carry out your work on paper towels or other protective materials such as dental bibs, to avoid spilling chemicals and blood on the bench.
- If you spill blood, wipe it immediately with the cleaners identified by the laboratory personnel and rinse with tap water.

At the end of the lab:

- Wipe your bench and your microscope to remove any blood stains
- Place any blood contaminated materials in the appropriate biohazard waste receptacles.
- Remove your gloves and goggles and wash your hands.

Experimental Procedures

Equipment:

- Alcohol swab
- Safety blood lancet
- A, B and Rh blood typing solutions
- Blood typing plastic well plates
- Paper towels
- Grease pencil or marker

13. Wash your hands with warm water. This will help to clean them but will also improve circulation to increase blood flow. You may also shake your fingers to help, or let the hand hang down for 30 seconds. Use an alcohol swab to clean the tip of the finger from which you will draw blood. For convenience's sake it is usually best to prick a finger of the hand you don't use for writing. The middle or ring fingers are usually the best choice but choose one that is not calloused.

14. Remove the tip from the lancet provided and use it to prick the end of your finger. Prick the tip slightly lateral to the centre. The skin tends to be softer here and blood flow is often better. Once you have pricked the finger you may need to lightly squeeze or massage it to maintain blood flow.

15. Place one drop of blood on each of the labelled areas of the plastic well plate. Add one drop of the appropriate reagents to each of the 3 blood drops (Anti A to the drop labelled A, Anti B to the drop labelled B, and Anti Rh to that drop). Use clean toothpicks to mix each blood drop with its reagent.

16. Allow the mixtures to sit for a short time period (generally a minute or two may be required). After this time, check each drop for signs of agglutination. This will mean that the blood shows signs of clumping. It should begin to look grainy if there is a positive reaction with the antibodies. Further mixing with a clean toothpick may help if your result seems uncertain. A light box may be available to better view your samples.

17. Identify your blood type based on the agglutination of the three drops. Table 19 shows the potential results and Figure 36 shows an example of blood Type A Positive results.

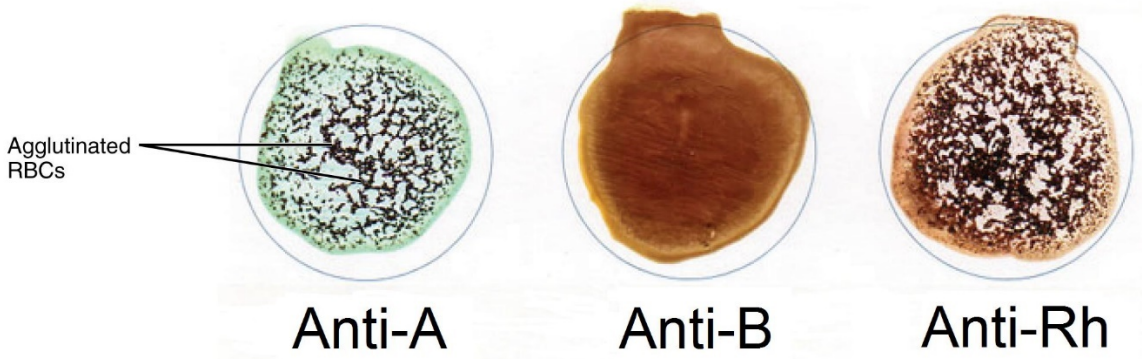

Figure 36. Illustration of Blood Type Reactions. *This picture shows the reactions between blood drops and the antibody reagents used for blood typing. The first and third blood drops have agglutinated, while the middle drop (Blood and Antibodies to B type proteins) has not changed. The results of this illustrated test indicate that the donor of this blood is type A positive since those antibodies have reacted with the blood sample. A person who was O negative would show no reactions in any of the three drops, while someone who was AB positive would have agglutination in all drops. (Image adapted from one on commons.wikimedia.org.)*

Table 19. Agglutination patterns of the common human blood types. *Yes in the table indicates that agglutination (clumping) has occurred for the A, B and Rh proteins respectively on the red blood cells of the donor.*

Blood Type	**Anti-A**	**Anti-B**	**Anti-Rh**
A Positive	Yes	No	Yes
A Negative	Yes	No	No
B Positive	No	Yes	Yes
B Negative	No	Yes	No
AB Positive	Yes	Yes	Yes
AB Negative	Yes	Yes	No
O Positive	No	No	Yes
O Negative	No	No	No

Laboratory Exercise 9: Digestion

In this exercise, you will examine the biochemistry of digestion. In particular, you will look at the breakdown of the common nutrient types found in food, and test for their presence based on their reactions. Work in groups of about 4 for this laboratory exercise. Cleanup your stations when you are done. Rinse test tubes and containers and replace them at the side or back bench at the end of class. Special handling of some reagents will be necessary. Follow lab safety precautions carefully during this lab.

Tests for Fats

A. The Emulsifying Properties of Bile Salts

Bile salts are produced in the liver, stored in the gallbladder and released into the small intestine. They are emulsifiers, chemicals that allow lipids to mix with polar solvents. This is necessary for digestion (a hint for part B below) so that water-soluble enzymes can interact with lipid foodstuffs. This next activity provides a brief demonstration of these emulsifying properties. An emulsion is a dispersion of the oil or other lipids into minuscule droplets dispersed throughout the water.

1. Prepare three test tubes: In the first one, put 3.0 ml olive oil and 3.0 ml distilled water. In the second test tube, put 3.0 ml water, 3.0 ml olive oil and 0.5 ml of bile salts. In the third test tube put 3.0 ml water, 3.0 ml olive oil and 2.0 ml of bile salts. Shake each of the tubes vigorously and note how long it takes for an oil layer to reform. An oil layer is considered to be present when no more bubbles rise to join the layer. If an emulsion forms instead, note how long it takes to form a stable emulsion.

2. Put the tubes in a rack and leave them for about an hour. Do NOT shake them again. Describe the appearance of each test tube after first shaking and changes in the appearance over time. Note generally how long it takes for the oil and water to separate. Record your results in the table below.

Table 20. Effects of Bile Salts on Miscibility of Oil and Water with notes on Observed Changes

Test tube	Time for emulsion or oil layer to form	Appearance changes during one hour	Appearance after one hour	Interpretation of result
1				
2				
3				

B. Digestion of Milk Fats by Pancreatic Lipase

In this test we will detect the presence of fat by testing for fatty acids, the metabolites produced by the action of lipase on lipids. Lipids are typically neutral molecules while fatty acids have a low pH. By testing for pH with a solution such as universal indicator, we can pick up these digestive products.

1. Label five test tubes and add solutions as shown in Table 2. **Add the enzyme last!** From your knowledge of biochemistry, you should be able to deduce the reasons for each of the mixtures of solutions shown below.

Table 21. Materials required for Fat Digestion Tests with Pancreatic Lipase and Bile Salts

Test Tube	Substrate (Cream)	Bile Salts	Distilled Water	Universal Indicator	Pancreatin (Lipase)
1	3.0 ml	pinch	-	3.0 ml	3.0 ml
2	3.0 ml	pinch	3.0 ml	3.0 ml	-
3	3.0 ml	-	-	3.0 ml	3.0 ml
4	-	pinch	3.0 ml	3.0 ml	3.0 ml
5	3.0 ml	pinch	3.0 ml	3.0 ml	3.0 ml

Note: Universal indicator is actually a mixture of different indicators that changes colour for pH values from 4 to 10. Enzymatic digestion of fat (triglyceride) releases fatty acids (e.g., butyric acid) that react with the indicator and change its colour towards red. Pancreatin is a commercial preparation of dried pancreatic enzymes.

Table 22. Colours Produced by Universal Indicator Solution at Differing pH Levels.

pH 4	pH 5	pH 6	pH 7	pH 8	pH 9	pH 10
red	orange	yellow	green	blue	indigo	violet

2. Agitate the tubes to thoroughly mix the contents and make note of the colour of each tube. Place the tubes in a water bath at 37ºC. Incubate for 1 to 1 1/2 hours.

3. Shake the tubes and record their colour in Table 3 at the times noted below. Continue monitoring until no colour change is observed between colour tests. Try to describe the colours both in terms of the actual colour and its translucency (e.g., clear red, milky blue). Interpret your results in Table 4.

Table 23. Colour observations from four mixtures during digestion tests of milk fat by pancreatic lipase

	Incubation times								
Test tube	0 min	5 min	10 min	15 min	30 min	45 min	60 min	75 min	90 min
1									
2									
3									
4									
5									

Table 24. Summary of results of milk fat digestion tests

Test tube	Presence of fatty acids	Cream digestion fast, slow or non-existent	Brief explanation of each result
1			
2			
3			
4			
5			

C. Testing the Nutrient Contents of Unknown Food Stuffs

Grease Test for Lipids

A very simple way to test for the presence of fats and other lipids in foodstuffs is to smear a small amount on a piece of paper towel and allow it to dry. While moisture will evaporate, fats will remain behind as a grease spot. Try this by drawing 7 circles on a piece of paper towel and smearing each of your unknowns plus water and oil (keep the smears thin to speed drying) into the labelled circles. Place the towelling into the incubator for 5 – 10 minutes to dry. Record your results.

Table 25. Results and Interpretation of Results from Grease Testing of Foodstuffs for Lipids

Substance Tested	Grease Spot	Amount of Lipid Present
Water		
Oil		
Unknown 1		
Unknown 2		
Unknown 3		
Unknown 4		
Unknown 5		

Test for Starch

We will test for starch using a simple iodine test. This is a colour reaction, where iodine produces a dark blue colour in the presence of starch. We can do this on a spot plate (a small porcelain dish with a series of small wells on its surface) by placing two or three drops of iodine or IKI, an iodine compound, in each of the wells and then adding several drops of each foodstuff to a separate well.

Iodine also reacts with shorter polysaccharides, which are the products of starch digestion. As the sugar chains get shorter the colour change becomes weaker. In the presence of long dextrins, a purple colour is produced, with medium dextrins, the iodine mixture turns brown, while short dextrins produce a tan colour and finally, maltose produces no colour change, so the iodine stays a yellowish colour. This colour series can sometimes be useful to detect the breakdown of starch or to test for assorted maltose-based polysaccharides, which are the most common complex carbohydrates in our foods.

1. Place a spot plate onto a paper towel and label the towelling to indicate which well will receive each of the foodstuffs. Label one well location for each of the 9 materials listed below. Place two or three drops of iodine into each of the wells you will use. Add a drop or two of each of the 9 materials from the test tubes to the appropriate iodine-containing well and note any colour changes.

2. Record your results in Table 26, interpreting the colour change produced to indicate the presence or absence of starch or other polysaccharides present.

Table 26. Results and Interpretation of Results from Iodine Testing of Foodstuffs for Starch

Substance Tested	Colour Produced	Polysaccharides Present
Water		
Glucose		
Sucrose		
Starch		
Unknown 1		
Unknown 2		
Unknown 3		
Unknown 4		
Unknown 5		

Tests for Sugars

We will use two reactions to test for sugars. The first uses Benedict's reagent to detect the presence of what are known as reducing sugars (as described by oxidation or reduction reactions). Most simple monosaccharides such as glucose and fructose are reducing sugars, as well as some disaccharides such as lactose and maltose. Reducing sugars react with Cu^{+2} ions (blue and soluble) in Benedict's reagent to form Cu^{+}, which combines with O_2 to form Cu_2O (red and insoluble). Actually, the reaction with Benedict's reagent can provide rough estimates of the amount of sugar present as well. No colour change indicates no reducing sugars were present. A greenish precipitate can indicate very low levels of sugar, yellow is a low level, orange is moderate, while a brick red precipitate shows higher levels of reducing sugars.

Non-reducing sugars include most polysaccharides such as starch, glycogen and cellulose, as well as the disaccharide sucrose and even the monosaccharide galactose. These sugars do not react with Cu^{+2}, so no red precipitate will form. They need to be detected by other techniques or by treating the foodstuff with enzymes such as amylase (an enzyme that breaks down starch into its component sugars) or sucrase (cleaves sucrose) before using a Benedict's test.

We will use a second reaction to pick up some of these non-reducing sugars. Seliwanoff's reagent differentiates between aldose and ketose sugars (sugars that react to produce either a ketone or aldehyde hexose when exposed to the reagent). Ketose sugars include sucrose and fructose (glucose will react but takes longer and produces a weaker result). Ketose sugars should result in a bright red or orange colour. Negative results should stay clear or straw coloured. Glucose, if it reacts, should produce a pale pink or peach colour.

Since the most common sugars found in foods are sucrose, fructose, glucose, maltose and lactose, this pair of tests will provide the information necessary to confirm the presence of sugars in food, and will allow some determination of which types of sugar are present.

Part A. Benedict's test for Reducing Sugars.

1. Measure 2 ml of each of your foodstuffs into labelled test tubes.

2. Add 2 ml of Benedict's reagent to each tube.

3. Place the test tubes in a boiling water bath and heat for 5 minutes. Do not allow the tubes to sit for longer than 5 minutes as this may cause further chemical reactions that will confound your results.

4. Record the results in Table 27, interpreting the colour change produced to indicate the presence or absence of reducing sugars.

Table 27. Results and Interpretation of Results from Benedict's Testing of Foodstuffs for Reducing Sugars

Substance Tested	Colour Produced	Reducing Sugars Present
Water		
Glucose		
Sucrose		
Starch		
Unknown 1		
Unknown 2		
Unknown 3		
Unknown 4		
Unknown 5		

Part B. Seliwanoff's test for Ketose Sugars.

1. Measure 1 mL of each of your foodstuffs into labelled test tubes.

2. Add 3 mL of Seliwanoff's reagent to each tube.

3. Place the test tubes in a boiling water bath and heat for 4 minutes. Do not allow the tubes to sit for longer than 5 minutes as this may cause further chemical reactions that will confound your results.

4. Record the results in Table 28, interpreting the colour change produced to indicate the presence or absence of ketose sugars.

Table 28. Results and Interpretation of Results from Seliwanoff's Testing of Foodstuffs for Ketose Sugars

Substance Tested	Colour Produced	Ketose Sugars Present
Water		
Glucose		
Fructose		
Sucrose		
Starch		
Unknown 1		
Unknown 2		
Unknown 3		
Unknown 4		
Unknown 5		

Test for Proteins

There are several widely used tests to detect the presence of proteins in foodstuffs. Unfortunately, most of these techniques involve fairly noxious substances. We will use Biuret reagent to detect proteins. Since this material is toxic (it contains copper and sodium hydroxide), the wastes from this exercise **must not go down the sink**. Pour all remaining solutions involving Biuret reagent into the specially marked bottle at the side of the room. The test tubes from this portion of the lab should not be cleaned after they are empty, but should be placed in the marked tray at the side of the room. This reagent reacts with peptide bonds in proteins to produce a purple colour.

1. Measure 5ml of water, albumin and the five unknowns into separate labelled test tubes.

2. Add 0.5 ml of Biuret reagent to each of the seven test tubes.

3. Place the tubes in a rack and let them sit for three to five. Record your results in the table below.

Table 29. Results and Interpretation of Results from Biuret Testing of Foodstuffs for Protein

Substance Tested	Colour Produced	Proteins Present
Water		
Albumin		
Unknown 1		
Unknown 2		
Unknown 3		
Unknown 4		
Unknown 5		

Biology 1220

Laboratory Exercise 10: Kidney Dissection

In this exercise, you will examine the structure and function of kidneys through dissection of a preserved pig kidney. This is a fairly simple dissection. Work in groups of about 4 for this laboratory exercise.

The excretory system in humans filters the blood and removes nitrogenous wastes, especially urea, for removal from the body. Nephrons in the two kidneys filter the blood. In addition to removing nitrogenous wastes, they serve important functions in homeostasis. They act as monitoring sites to assist in the maintenance of chemical balance in the body. Fluid balance, electrolyte levels and pH are all regulated in this system, with the assistance of the nervous system, endocrine system and liver.

The product of blood filtration is urine, which is a mixture consisting primarily of urea, salt and water, although other substances will be present in small quantities. Some of these other materials include creatine, uric acid, and ions such as bicarbonate, calcium, magnesium, potassium, phosphate, and sulphate ions. Urine is produced in the nephrons of the kidneys where it passes to the collecting ducts, which merge to form the renal pelvis. This interior region of the kidney empties into the ureters, which connect to the urinary bladder. Urine is stored in the bladder until micturition, or urination, when it exits the body through the urethra.

The kidney is supplied with blood by the renal blood vessels (renal arteries and veins). The renal arteries branch off of the abdominal aorta while the renal veins connect directly to the inferior vena cava. The arteries typically lie just posterior to the veins, although the arrangement of vessels for the kidneys is quite variable. A covering membrane known as the renal capsule protects the entire structure. The capsule usually has some adipose tissue. The blood vessels and **ureter** pass through this membrane at the renal **hilum**, an indented portion of the kidney on the medial surface.

Collect your dissecting tools, tray and a preserved kidney.

Begin by an external examination of the kidney. Small amounts of **adipose tissue** may adhere to the **renal capsule**. The **renal blood vessels** and **ureter** will exit the kidney on the medial surface at an indentation that is the **hilum**. The kidney will be covered (depending on the state

of your particular specimen) by the renal capsule. In a few instances, there may be remnants of the **adrenal gland** on the anterior end of the kidney, embedded in the adipose tissue.

Remove the capsule to expose the **renal cortex**, the outer layer of the kidney, where most blood filtration occurs. If they are still attached at the hilum, separate the renal blood vessels from each other and from the ureter. Generally, the tube with the most adipose around it is the ureter. Note any visible differences or similarities among the arteries, veins, and ureter.

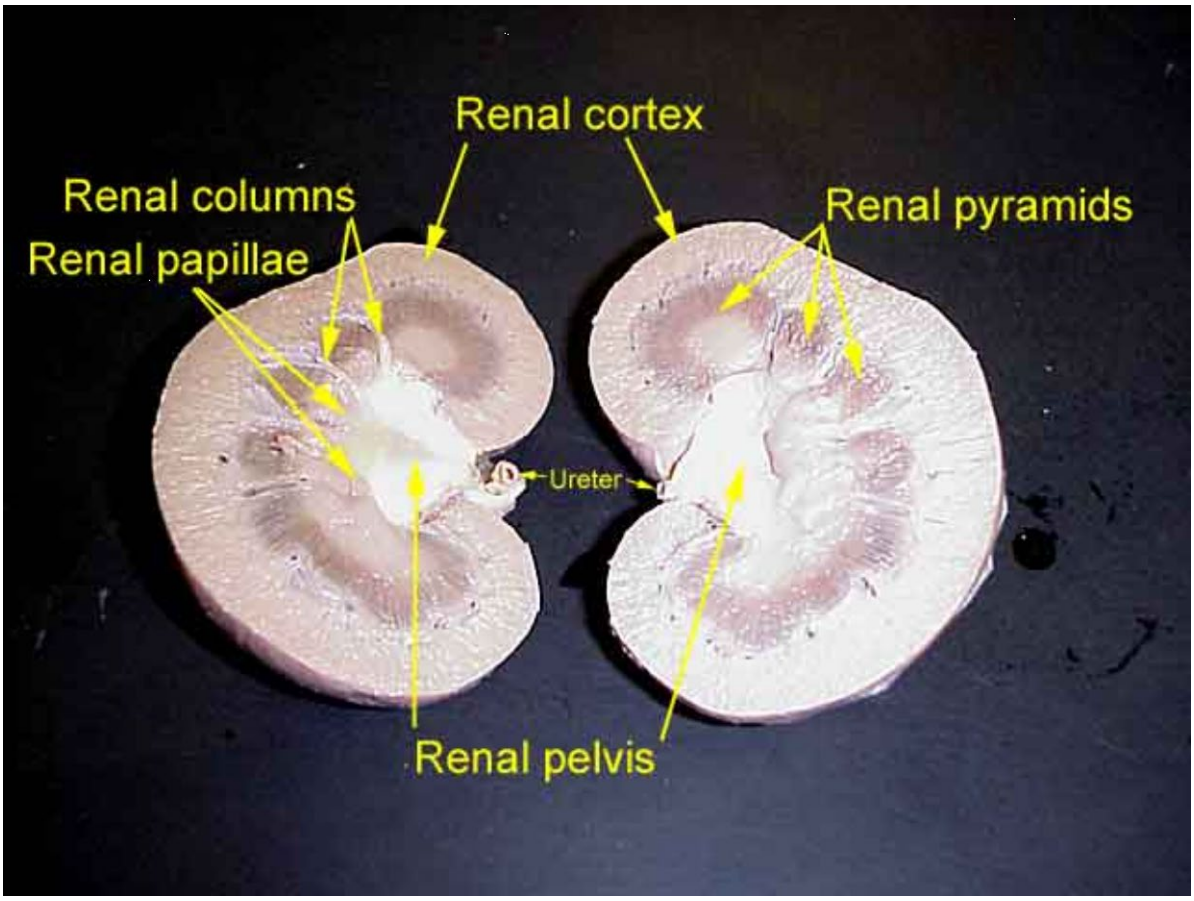

Figure 37. A bisected kidney showing gross anatomical structures. (State University of New York Virtual Anatomy Lab, 2003).

Make a frontal section through the kidney (cut it in half as shown in Figure 37). You should be able to differentiate the outer cortex from the deeper portion known as the **renal medulla** and the central cavity known as the **renal pelvis**. If your kidney has been injected during its preservation, you will see red and blue latex throughout the cortex, from the numerous small blood vessels in this layer.

The medulla is chiefly distinguishable by the presence of the darker **renal pyramids** in this layer. The medullary regions between the pyramids are the **renal columns**. The columns are histologically similar to the cortex and contain arteries feeding the cortex, while the pyramids are darker in colour and contain collecting ducts and loops of Henle from the nephrons. These ducts provide the dark, striated appearance of the pyramids. The nephrons are located throughout the medulla and cortex, although these structures are not usually visible due to their microscopic diameters. The **renal papillae** are the interior tips of the pyramids. These papillae extend into the **calyces**, which are the hollow chambers feeding into the renal pelvis. The primary (large) extensions are the **major calyces** and the smaller extensions are the **minor calyces**. The **pelvis**, of course, drains into the ureter.

Laboratory Exercise 11: Urinalysis

In this exercise, you will examine some of the techniques in urinalysis. This is a very common medical procedure. Health practitioners use information from inspection of urine for diagnosis of many things, including infections, digestive and kidney disorders, parasitic infection, cancer, drug overdose and toxicity, and pregnancy. We have already had a brief exposure to blood analysis in the haematology lab. Today we will look at urine as these two procedures are the most commonly tested bodily products. Other bodily products can also be inspected, such as sputum, faeces, vomit and cerebrospinal fluid, but those tests are less common and are typically used for more limited diagnostic reasons.

There are a variety of test procedures that can be carried out as part of urinalysis. In this lab we will focus on some of the most common approaches including chemical testing and microscopic analysis. Work in groups of about 4 for this laboratory exercise.

Note: In some terms it may be necessary to do this activity as a take home lab. In that situation, you will use a midstream collection technique at home (as described below) to collect your specimen, then carry out the basic observations and chemical testing of the urine. Results only will be brought back to class for review and analysis.

Specimen Collection

Urinalysis for this lab will be done using human specimens, so safety is the first priority, to eliminate any risk of contamination. Wear gloves while handling specimens, and wash down countertops and equipment to remove any drips or spills.

Only volunteers will be providing specimens. If possible, volunteers should not be taking any prescription medications such as antibiotics or have used aspirin or Vitamin C in the last 24 – 48 hours.

The best way to collect a specimen is by what is known as a midstream collection. Go to the washroom and clean the genital area lightly. This is done to prevent contamination of the specimen with surface dirt, chemicals or epithelial cells that can confuse the analysis of the specimen. Begin urinating into the toilet and place the collection cup into the stream after you have begun voiding. Collect about half the cup's volume (you need an absolute minimum of 10 ml) and remove the container from the stream before you finish urinating. Place the lid on the cup, wipe it with a clean paper towel and return to the classroom.

Basic Observations

Before doing anything else, a brief examination of the urine can be useful. What is its colour? Typically, the colour of urine will range from nearly clear to a dark straw yellow. This range of colours is indicative of the concentration of the urine, which we will measure using the chem strips. Its concentration can also be measured quantitatively using a refractometer, an instrument with a built-in prism. Light travelling through the urine is bent and the degree to which it refracts or bends can be measured on a scale and compared to pure water. We won't use the refractometer today, but this technique is widely used.

Colour of urine can also provide other information. There may be small amounts of blood, indicating some damage to the internal tissues. The urine may appear cloudy or turbid due to yeast or bacterial infections or similar problems. There may also be a sparkly appearance due to tiny crystals of calcium or other metals from kidney deposits. While the yellow or straw colour is due to the presence of small amounts of bile pigments, other colouration can also occur. Certain foods such as beets, squash or rhubarb or some drugs (certain antibiotics or ophthalmological test reagents and other medical dyes) can also impart unusual colours to urine.

Odour is fairly mild for typical, healthy urine with a mild ammonia component. Stronger odours may be due to urinary tract infections or other disorders. Certain foods can also impart distinctive odours to the urine including asparagus. Note any specific observations for your urine sample below:

Colour:

Notable appearance features if any (turbidity, sparkling, debris):

Odour:

Other observations:

Chemical testing

In the past, the procedures to test for chemical levels in the urine were quite complex, but advances in technology have greatly eased the requirements. Many tests can now be carried out with a single dip stick that carries multiple reagents and can test for many items at once. We will use a strip that tests for 10 items. Simply dip the strip into a freshly collected urine sample for no more than a second. As you remove the strip from the urine, pull it lightly against the edge of the collection cup to remove any excess fluid. Let the strip react and at one minute (or other time period as specified in instructions with the test strips) after dipping the strip, compare the squares on the strip to the colour charts provided to you.

Record the results in Table 30 below, interpreting the colour change produced to indicate the presence or absence of the material or its level.

Table 30. Results and Interpretation of Results from Chemical Testing of Urine Samples.

Substance Tested	Colour Produced	Interpretation
Specific Gravity		
Urine pH		
Leukocytes		
Nitrite		
Protein		
Glucose		
Ketones		
Urobilinogen		
Bilirubin		
Blood Erythrocytes		

What the tests indicate:

1. **Specific gravity**. This is the density of the urine compared to pure water, which has a specific gravity of 1.000. A reading that is too low can indicate multiple things, including over hydration (drinking too much) or kidney filtration problems. A very high specific gravity may indicate dehydration or nephritis. Normal readings for specific gravity will range from 1.005 to 1.030.
2. **Urine pH**. The readings for pH range from 0 to 14 with 7 being neutral. Lower readings are acidic and those above 7 are basic. The main component of urine, urea, is basic, but the human body tends to produce excess acids for excretion. Readings between 4.8 and 8.0 are common, with an average reading being around 6.0.
3. **Leukocytes**. This should be negative. Presence of white blood cells is often an indication of infection. False positives can occur if the subject is using certain antibiotics or if the urine has a very high specific gravity.
4. **Nitrites**. This test should also be negative. Presence of nitrites in the urine is another indication of a potential bacterial infection. Urine normally contains small amounts of nitrates from the digestion of vegetables, but if some strains of bacteria are numerous enough, they will convert the nitrate into nitrite. This test only indicates the presence of those bacteria who do this chemical conversion, so a negative result does not indicate the subject lacks a bacterial infection.
5. **Protein**. Trace amounts of protein in the urine are normal. We normally excrete up to 150 mg of protein (primarily albumin) over the course of a day, but this should only cause the test to show a trace at any given time. Higher levels of protein can indicate excess protein production in the blood or kidney problems preventing the removal of the protein in the nephrons. Diabetes is one of the most common causes of the nephron problems resulting in excess protein excretion. Extremely high or low specific gravities can interfere with results for this test.
6. **Glucose**. Normally, urine contains little or no sugars. The expected result for this test is either negative or trace levels. The presence of excess glucose in the urine may be an indication of diabetes or other metabolic disorders. Aspirin can interfere with glucose testing in the urine, as can severe dieting.
7. **Ketones**. The expected result for this test is negative. Ketones are a by-product of the digestion of fats, and are normally removed from the blood before it passes through the kidney. Ketones can be found in the urine if the subject is dieting or fasting or is suffering from alcohol toxicity. Aspirin can interfere with this test.
8. **Urobilinogen**. This chemical is a breakdown product from bilirubin. High levels of this material in the urine can be an indication of liver problems or excess destruction of blood cells. The liver processes haemoglobin to produce the bile pigments and then converts some of that material into urobilinogen. The test for this product should be negative.

9. **Bilirubin**. One of the two major bile pigments. Again, we expect a negative result for this test. As with urobilinogen, high levels of bilirubin can indicate liver problems or excess destruction of red blood cells. High levels of ascorbic acid (Vitamin C) in the body can result in false readings for this test.
10. **Blood Erythrocytes**. Normal urine should not contain significant numbers of red blood cells. Values for this test should be 0 -5 cells per microlitre, which would register as negative or trace. Blood in the urine could be due to excess haemolysis, infection, trauma, tumours, menses or many other causes.

Specimen Preparation and Microscopic Examination

Examining a concentrated urine sample can be quite useful for detecting bacteria and other infectious agents, cellular components that have been excreted, and debris and crystals that can be diagnostic of various pathological conditions. Preparation of the specimen for examination requires the use of a centrifuge to separate the sediment containing these materials from the fluids which are of no further interest.

1. Obtain a clean centrifuge tube, label it to identify your specimen and fill it with about 10 ml of urine.
2. Place the tube into the centrifuge as directed. It will be centrifuged for 5 – 10 minutes.
3. Retrieve your tube and carefully pour off the top 9.5 ml of the sample, trying not to disturb the remaining fluid and sediment.
4. Remix the remaining material by gently shaking or tapping the side of the tube or by using the vortexer (stirring machine) as directed by your instructor.
5. Use a dropper or rod to remove one drop of the mixed material and transfer it to a clean glass slide.
6. Place a cover slip on the slide, gently lowering it from one side of the drop to reduce the risk of air bubbles.
7. Examine the slide at low power. You are looking for large objects such as parasites, mucous threads, eggs and casts (precipitations of proteins, gels or cells that form large molded objects in the nephrons). Use a low level of light to make objects such as casts more easily visible. A formal analysis would involve checking 10 different low power fields and reporting the average numbers of each type of object seen from those examinations. For our purposes, examine several fields and sketch your results.
8. Move to high power and re-examine the slide. As before, a formal analysis would involve examination of 10 different fields of view and presentation of the average numbers of objects from those fields. For our purposes, again examine several fields and sketch your results, then record the items in Table 31.

Items to watch for during microscopy:

1. **Red Blood Cells**. Normally, you should only see a very few red blood cells. Typical values are less than 3 cells per high power field of view. Cell numbers higher than 8-10 are abnormal and may indicate injury or disease or menstrual contamination.
2. **White Blood Cells**. Again, only small numbers of leukocytes should be observed. Values higher than 5 cells per high power field may indicate an infection or inflammation.
3. **Epithelial cells**. These cells are one of the main reasons to clean the genital area lightly before collecting a urine specimen. Contamination of the urine from the surrounding tissues is common. Squamous or transitional epithelial cells are likely to be present from the urinary tract and skin and usually have no clinical significance. Other types of cells such as renal tubule cells may indicate a kidney problem.
4. **Bacteria**. Only very small numbers of bacteria should be found in urine. Urine from the bladder is normally bacteria free, but contamination during transit through the urethra is common, so bacteria in small amounts may be found in the sample. Bacteria are extremely small, so finding them takes some practice. They typically range in size from 1 to 5 microns, so they will be less than 1% of the width of a high-power field of view. The shapes of bacteria include cocci (circular), bacilli (straight rods), spirilla (spiral) and vibrios (curved rods. Cocci and bacilli are the most common shapes. If bacteria were found during a clinical analysis, some of the urine could be cultured to grow and isolate the types of bacteria and determine their sensitivity to various antibiotics. Finding multiple types of bacteria may be more indicative of a contaminated specimen than a urinary infection.
5. **Other microorganisms**. Yeast cells may be found in the urine and are almost always indicative of an infection. Large parasites such as worm eggs are very rare but may be found, as is the case for other parasitic creatures such as protists.
6. **Casts**. Casts are formed when debris including cells, proteins and crystals pass through the tubules of the kidneys. Albumin and other proteins can cause these materials to coagulate and form cylinders that conform to the shape of the interiors of the tubules. Cast width can also be valuable in diagnosis. Narrow casts are less than 15 microns wide, medium ones are 20 – 30 microns while broad ones are about 35 microns. Broad casts usually form in the collecting ducts and may indicate severe and long-standing renal disease. There are a number of different types of casts that you might see in a urine specimen. Almost all of them are indicative of a kidney problem, with the possible exception of a small number of hyaline casts.
    a. **Erythrocyte casts**. These will range in colour from nearly clear to brown. They are usually only found if there is glomerular damage.
    b. **Leukocyte casts**. More common than red cell casts and may occur if there is infection or inflammation.
    c. **Epithelial casts**. Very rare but can occur if there is a pathology of the kidney tubules.

d. **Granular casts**. Formed from the breakdown of earlier cellular casts. They can range from coarse to finely grained. Coarse grained casts may sometimes look very dark. Finer grained casts can be grey or yellowish. While these casts usually indicate renal disease, extreme exercise can sometimes result in their formation.

e. **Waxy casts**. Result from degeneration of granular casts. They can appear yellow, grey or colourless. The shapes of waxy casts are sometimes less distinct than other cast types.

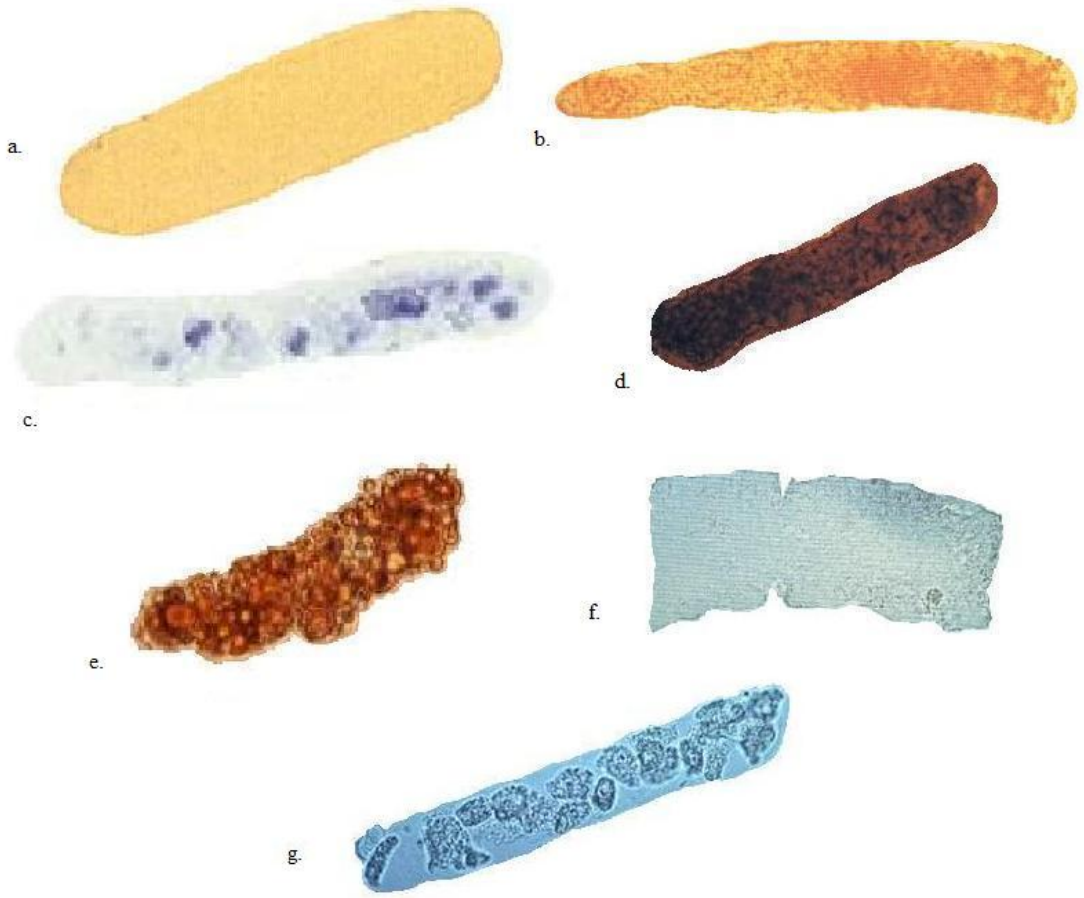

Figure 38. Examples of casts in urine. a. Hyaline Cast. b. Granular Cast. c. Leukocyte Cast. d. Erythrocyte Cast. f. Waxy Cast. g. Epithelial Cast. Magnifications are about 100X.

f. **Fatty casts**. Leakage of lipoproteins or renal toxicity can produce these casts. They will contain fat droplets inside their cylindrical shape. The droplets are frequently a yellow or brown colour.

g. **Hyaline casts**. These are the most common type of cast. They are usually colourless and almost transparent, with smooth cylindrical shapes. Almost any level of renal disease can result in the production of these casts.

7. **Crystals**. Small numbers of crystals in the urine sample are not unusual. The types of crystals will depend on the pH of the urine as crystal formation is dependent on whether the environment is acidic or basic. In basic urine you could find phosphate crystals that can be either rectangular or lack a defined shape, or ammonium crystals that will appear spiky. In acidic urine you can find calcium oxalate crystals, with an envelope shape, rectangular sodium crystals, or crystallised amino acids including hexagonal cystine crystals, spherical leucine crystals or needle-shaped tyrosine. Certain poorly soluble drugs can also crystallise, including sulfonamides and members of the penicillin family.
8. **Assorted Debris**. This can include items ranging from threads to dirt and dust to powder granules and grease deposits, almost always due to contamination of the specimen.

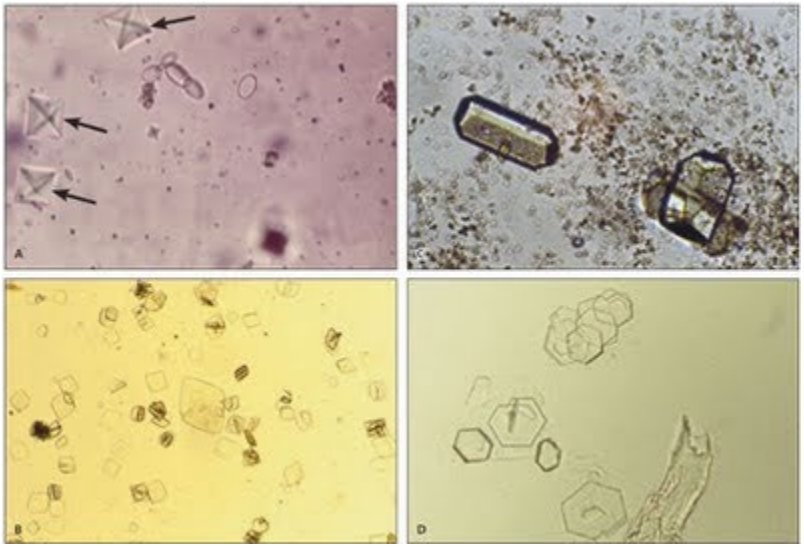

Figure 39. Some crystals that can be found in urine sediments. a. Calcium oxalate. b. Uric Acid. c. Phosphate (rectangular and amorphous). d. Cystine. Magnifications are from 100-400X.

Record items found during microscopy here:

Table 31. Results and Interpretation of Results from Microscopic Examination of Urine Samples.

Item found	Numbers / field (high / low power)	Description
Erythrocytes		
Leukocytes		
Epithelial cells		
Bacteria		
Other microorganisms		
Casts		
Crystals		
Other		

Clean Up:

- Wash all reusable equipment with soap and warm water, discarding the specimen cups and tubes. Place used microscope slides and cover slips in the sharps disposal containers.
- Return equipment to where you found it.

Biology 1220

Laboratory Exercise 12: Foetal Pig Dissection

This lab is designed to give you an overview of the organ systems that we have examined throughout this pair of courses. We will do only a cursory examination of the muscular and skeletal systems where the orientation of structures in these systems appears different than that in humans. Remember, however, that despite the apparent differences, most of the bone and muscle groups are anatomically identical in pigs and humans.

Work in groups of about 4, using a dissecting microscope in addition to basic dissection materials if necessary. Other resources will include your textbook and colouring book, as well as the concise pig guide and the laboratory anatomy manuals for the pig. These latter two guides are available at the front of the room. An anatomy manual will be necessary to provide detailed diagrams of the structures of the pig.

General notes on dissection

For this dissection you will need:

4 blunt probes	one or two sharp probes
a dissecting tray	6 – 12 dissecting pins
a pair of sharp-tipped dissecting scissors	one or two pairs of tweezers
a scalpel	bone cutters
dissecting microscope (optional)	flesh hooks

As usual, the scalpel should be avoided as much as possible. Aside from its potential to injure the dissector, it causes severe damage to surrounding tissues on the specimen.

As with our previous dissections, you should start with the external features. Avoid the temptation to immediately start cutting. It is easier to locate important anatomical landmarks on an intact structure. When you cut the specimen (again, scissors are often preferred to scalpels), cut smoothly and decisively but only cut material that you need to remove or open. Tentative cutting will result in a ragged dissection that makes identification difficult. Hacking a specimen apart will destroy important components

before you can work with them. If you use scissors keep the tips of the scissors as shallow as possible to minimize damage to underlying tissues.

Surface Anatomy of the Pig

Begin with an examination of your pig for distinctive surface landmarks. Place the animal on its side in your dissecting tray. The age of your pig can be roughly determined from its length. Measure the pig following the curve of the spine from the tip of its nose to the base of its tail. A full-term foetus of 16 to 17 weeks should be 30 to 35 cm long. An animal of about 15 weeks will have an average length of about 26 cm, while a 22 cm specimen suggests the pig had a gestation age of only 14 weeks.

Locate the following external features:

Nostrils (nares)	**Eyes** (Do they open?)
Eyelids (Are there eyelashes?)	**Nictitating membrane** (third eyelid)
Pinna (ear flap)	**Auditory meatus** (entrance to ear canal)
Hooves (How many digits?)	**Vibrissae** (sensory whiskers on the chin)
Ankle	**Knee**
Wrist	**Elbow**
Nipples (How many?)	**Umbilical cord**

Determine the sex of your pig in the obvious way. Females have a projection, the **urogenital papilla**, located ventrally to the anal opening. The **urogenital opening** lies at the base of this small papilla. Males possess a **scrotal sac** below the **anus**. This will be easily visible in larger, more mature specimens, but should be visible as rounded protrusions even in young foetal pigs. The penis will not be externally visible as it is still internalised. The urogenital opening is the opening to the penis and will be visible with close examination. It is located on the abdominal surface just posterior to the umbilical cord. Compare your animal with those of other groups to ensure you have seen both sexes.

Hold open the mouth of your pig, to locate the **teeth** and **tongue**. The number of visible teeth will vary depending on the age of the specimen, but you are likely to find a pair of **incisors** and a pair of **canines**. You should be able to distinguish the **hard** and **soft palates** on the roof of the mouth. If you use your scalpel to enlarge the mouth with incisions at either corner, you should be able to open the mouth widely enough to expose the throat and see the **epiglottis** covering the **glottis**. The epiglottis will appear as a small curved piece of tissue in the pharynx. Looking towards the anterior surfaces, you should be able to make out the **nasopharynx**, the opening to the sinuses.

Internal Anatomy of the Pig

Place the animal with the ventral side up. Use flesh hooks to anchor the limbs to the sides of the tray and hold the body in a convenient orientation. Refer to Figure 18 for the suggested incisions you will need to expose the inner structures of your pig. The incisions are numbered and should be made in the same sequence as their number. Do not make all the incisions at once. You will make these incisions as you work through the various regions of the body.

Start with incision 1, which is a horizontal cut just posterior to the front limbs. Start shallow, then deepen the cut, to expose the ribs. Since the skeleton of the foetal pig has not fully ossified, you may well be able to cut through the rib cage with your dissecting scissors. If you have difficulty, carefully use a pair of bone cutters to cut the ribs. Insert a blunt probe into the thoracic cavity and use it to locate the position of the **diaphragm**. Once you have located this structure, make your second incision just posterior to the diaphragm.

Open up the chest cavity with a sagittal incision (3) just lateral to the midline. Making this cut just off centre will reduce the risk of damaging the heart when you cut through the ribcage. Again, cut through the ribs using either a pair of dissecting scissors or with the bone cutters. Expose the structures in the neck region with a medial incision (4) and horizontal cuts (5) anterior to the front limbs.

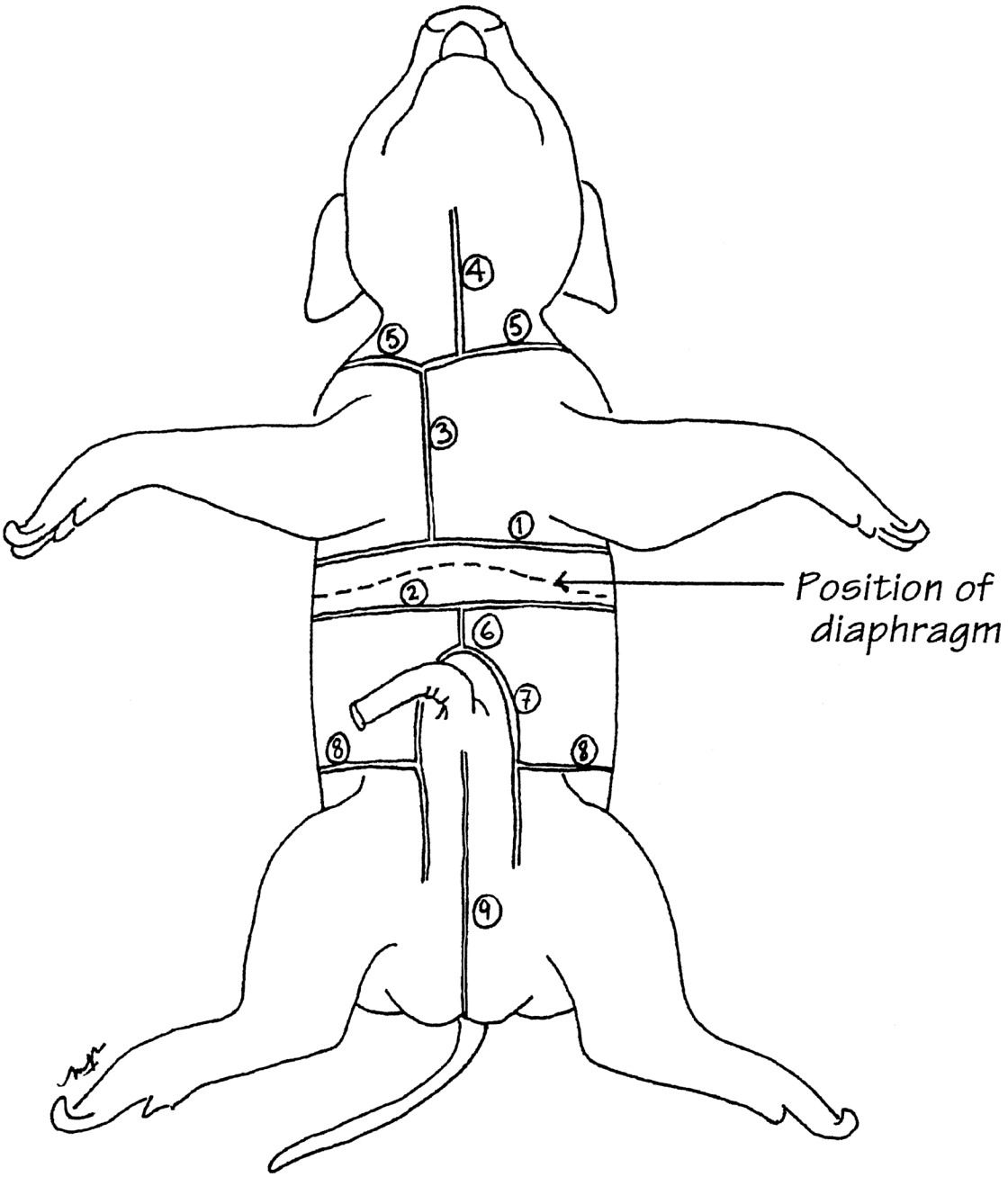

Figure 40. A sequenced list of the incisions necessary for internal examination and dissection of a foetal pig.

1. Neck Region

Peel back the skin in the neck region. It is usually easier to pull this back with your hands or by using a blunt probe to separate the skin from the underlying muscles. As you peel it back you are severing the **superficial fascia** that connect these structures. Once the skin has been pulled back, the **masseter** muscles should be visible just medial to the ears. These are used to elevate the lower jaw.

At the anterior end of your incision, the medial muscle extending between the sides of the mandible is the **mylohyoid,** whose contraction lifts the floor of the mouth. Proceeding posteriorly from this sheet of muscle will be the **sternohyoid** muscles, which act on the tongue and hyoid bone. The **sternomastoids** angle out laterally and anteriorly towards the base of the jaw, starting from the medial region of the clavicle. These muscles are used to flex the head.

Cut through the muscles as necessary to expose the 3 pairs of **salivary glands**. These glands should be found in locations nearly identical to those of the rat, which you dissected last term. The **parotids** lie laterally near the ears. The **sublinguals** lie lateral to the trachea at about the level of the cranial tip of the shoulders. Finally, the **submandibulars**, which are usually the most visible pair of salivary glands, lie just posterior to the sublinguals on either side of the thyroid gland.

Medially, you will expose the **trachea** and **larynx**. Lying on top of the trachea will be the round, dark red **thyroid** gland. Wrapped around the side of the thyroid, or possibly located just posterior to the thyroid, you will find the thymus gland, which will be a lighter pink to beige colour. **Lymph nodes** will appear as small whitish structures of variable size throughout the neck region.

Blood vessels you will find in this region will include the **external jugular veins**, which will collect blood from the **maxillary veins** and **linguofacial veins** branched over the jaw structures. The **internal jugular veins** will lie deep to the external jugulars. The **common carotid arteries** will also be deep to the jugulars. Since our specimens should have been doubly latex injected before preservation, the arteries should be pink and the veins blue. The **subclavian arteries and veins** will run out towards the limbs.

2. Chest Cavity

If you peel back the skin from the rib cage, you will expose the **external oblique muscles**. Inside the chest cavity you will find the **lungs**. Coming from the lungs will be the **bronchi**, which will merge into the **trachea**. If you are lucky, you may be able to find the **vagus nerve**, which will be a thin white thread, running alongside the trachea.

On top of the lungs will lay the **pericardial sac** surrounding the **heart**. Identify the **chambers** of the heart as well as the **aorta**, **superior and inferior vena cava**, **pulmonary arteries and veins**, and **coronary arteries**. The **oesophagus** will extend from the throat to the diaphragm and will lie behind the trachea. The **hiatal** opening should be visible as the passage point for the oesophagus into the abdomen.

3. Abdominal Cavity

Make incisions 6 and 7 as shown on Figure 18, to open up the abdominal cavity, but leave the umbilicus intact. Make lateral incisions (8) to allow you to peel back the abdominal musculature and incision 9 to expose the structures in the pelvic region.

Identify the following structures:

Liver (How many lobes?)	**Gallbladder and bile duct**
Hepatic Portal Vein	**Hepatic Artery**
Stomach	**Spleen**
Pancreas and pancreatic ducts	**Duodenum, Jejunum and Ileum**
Mesenteries	**Mesenteric Arteries and Veins**
Umbilical cord	**Umbilical Artery and Vein**
Caecum	**Spiral Colon**
Ascending and Descending Colon	**Rectum**

Cut the duodenum at its anterior end and gently tease out the small intestines. You should be able to distinguish the duodenum from the posterior sections of the small intestine based on the position of the duodenum, which is typically just the first section of small intestine before it first folds on itself. The ileum and jejunum are difficult to differentiate by external examination. Measure the length of the small intestine.

The caecum is fairly small in pigs and is the short blind sac at the junction of the small and large intestines. The spiral colon is not found in humans. It is a tightly coiled portion of the colon, but has the exact same function (reabsorption of water and salts) as the rest of the colon. Contrast the structure of the large intestine of the pig to that seen in the human models. The rectum may not be easy to find until you have examined the excretory and reproductive structures.

Once the small intestine has been pulled out of the way, you will be able to see the deeper structures of the abdomen. The bean-shaped **kidneys** will lie just posterior to the rib cage on either side of the spinal column. They will probably be covered by the transparent **peritoneum**. The **renal arteries and veins** will connect the kidneys to the aorta and vena cava, respectively. The **ureters** will appear as thin white threads running towards the umbilicus, where you will find the **urinary bladder** between the umbilical blood vessels. The **urethra** connects the bladder to the penis or urogenital papilla. The **iliac arteries and veins** will be located in this posterior portion of the cavity, extending out towards the hind limbs.

We examined the reproductive system last term, so we will make do with just a quick examination of these structures. The **rectum** will lie deep to these structures so you should examine it last. Make sure that you see examples of the structures from both sexes.

A. Male Reproductive System

Open up one of the scrotal sacs with a sagittal incision through the skin, muscle (**cremaster**) and visceral membranes (**tunica vaginalis**) to expose the contents. The structures of the scrotal sac will connect with the abdominal portions of the reproductive and excretory tracts via the **inguinal canal**. This opening in the musculature and membranes of the abdominal cavity is subject to herniation, just as is the case with the hiatal opening in the diaphragm.

Locate and identify these structures:

Testis	**Epididymis**
Vas deferens	**Urethra**
Prostate Gland	**Cowper's Gland** (bulbourethral)
Seminal Vesicle	**Penis**
Preputial gland	

B. Female Reproductive System

The majority of the components of the female reproductive system will lie in the dorsal portion of the abdominal cavity.

Identify the following structures:

Oviducts (Fallopian tubes)	**Ovaries**
Urethra	**Uterus** (with uterine horns)
Vagina	

4. Other Body Regions

If time permits you may wish to examine the nervous system, although it is a bit of a challenge to expose. Remove the skin from the head and look for a thin spot in the skull. You may need to use your scalpel to scrape the bone to make a thin spot. Use a pair of scissors to make and expand a hole through the skull to expose the brain. If all else fails you can use the bone cutters, but because of their size, they are likely to damage the brain. Identify the **meninges, cerebrum, cerebellum, medulla and pons**. Similarly, you may wish to remove the skin from a forelimb and hindlimb to examine the muscles of the appendages and girdles.

Once you have identified all of the structures of this lab exercise, dispose of the remaining material as directed by your instructors. Rinse your instruments and place them in the container next to the sink at the back or side of the room. Rinse your dissecting tray and place it upside down (so it can drain) beside the sink.

Appendices

Assignments, Learning Objectives and Other Materials

Including Laboratory Safety

Biology 1120: Drug Effects Research Essay

In this report you will write a short (maximum 1200 words) discussion of the effects of one drug/medication on human physiology. Your report should be fully and accurately cited, using **at least** three reliable sources. Reliable sources include textbooks and refereed journals, but not internet sources (except refereed electronic journals), newspapers, or personal communications. While less reliable sources such as unrefereed web sites can not be used to count towards your minimum number of references, they can be used in addition to your reliable sources. Do not use them as the primary source of information, however; stick to your refereed sources for the majority of your information. The report should be typed (or neatly hand printed, if word processing is just not possible), double-spaced and single sided.

Topics your essay should cover include the uses of the drug and its intended effects. If you are researching a drug that is used illegally, include the purpose for which it was first developed, if that is known. Describe the mode of action of the drug. How does it affect the body? Describe any adverse effects known for the drug and any contraindications, or pre-existing conditions which might result in problems if the drug is used. Discuss short-term and long-term effects of the drug. Does it cause permanent change to the body and how? Discuss known interactions with other drugs or substances.

You will be marking each other's essays (your instructor may also mark the essays and may reserve the right to override any marks that they feel are unjustified based on their own review of the essays). The purpose of this part of the exercise is to expose you to each other's writing so that you can help each other improve and see styles that might provide you with ideas for your own writing. An even more important component of this marking is to expose you to additional research on medications than your own paper. You will each mark two other papers from the class. A marking guide is provided on the following pages.

Note that this is an essay rather than a lab report. You should follow the rules for citing and referencing in the accompanying appendix, but the essay will not have the sections of a lab report.

Potential essay topics:

Get instructor approval before choosing a topic from this list or other topics. Note that these are often categories of medications rather than single drugs. In your essay you should choose one particular drug out of the set for that topic. This will allow you to concentrate on one set of effects.

1. Local anaesthetics
2. General anaesthetics
3. Blood pressure medications
4. Statin drugs (cholesterol control)
5. Female birth control pills
6. Acid reflux medications
7. NSAID medications (aspirin, etc.)
8. Acetaminophen
9. Narcotic pain killers
10. Antihistamines
11. Nicotine
12. Marijuana
13. Alcohol
14. Cocaine
15. Heroin
16. Echinacea
17. Prozac
18. Hypericum (St. John's Wort)
19. Tricyclic antidepressants
20. SSRI antidepressants
21. MDMA (Ecstasy)
22. Amphetamines
23. Barbiturates
24. Caffeine
25. Viagra
26. Estrogen replacement
27. Antibacterial medications
28. Antifungal medications
29. Glucosamine
30. Testosterone
31. Antiasthmatics
32. Antiepileptics
33. Oral corticosteroids
34. Cardiac glycosides

Marking Guide for Drug Effects Research Essay

General Information (30)

For each of the following topics give marks as follows: outstanding (5), good (4), average (3.5), pass (2.5), inadequate (2), not good (1), missing (0). Refer to the earlier description of topics to help judge the content of this section.

Intended drug effects	
Mode of action	
Adverse effects	
Contraindications/pre-existing conditions	
Short-term and long-term effects	
Interactions	

Style (8)

Give marks as described below. Take off extra marks for poorly written material or any evidence of copying, plagiarism

4 marks: 1 mark each for correct grammar, spelling, length, good organisation of material	
2 marks for appropriate language (their own words – not merely repeating material from references)	
2 marks for overall presentation and appearance	

References (12)

Citations in essay (3). All information cited (3), half information cited (1.5), very little cited (0.5), no citations (0)	
Citation format as in handout (2). Take off 0.5 for each minor error such as spelling, underlining, etc., -1 for major errors such as mistakes in names, dates.	
All references in list at end of essay are cited in essay (1). Take off 0.5 for each reference not cited.	
All citations in essay are referenced at end of essay (1). Take off 0.5 for each citation not referenced.	
Reference list at end of essay (3). 1 mark per appropriate source. Unrefereed websites, encyclopaedias, etc. do not count toward this material	
References format (2). Take off 0.5 for each minor error such as spelling, underlining, etc., take off 1 for major errors such as mistakes in names, dates.	

Biology 1220: Pathology Research Essay

In this report you will write a short (maximum 1200 words) discussion of the effects of one pathology (disease or abnormality of body structures) on human anatomy and physiology. Your report should be fully and accurately cited, using **at least** three reliable sources. Reliable sources include textbooks and refereed journals, but not internet sources (except refereed electronic journals), newspapers, or personal communications. While less reliable sources such as unrefereed web sites can not be used to count towards your minimum number of references, they can be used in addition to your reliable sources. Do not use them as the primary source of information, however; stick to your refereed sources for the majority of your information. The report should be typed, double-spaced and single sided.

Topics your essay should cover include the cause of the pathology and its likely effects. Describe the way in which the problem develops. Is it acute or chronic? Describe its symptomology. How does it affect the body? Describe any treatments or methods of alleviating the pathology or making its symptoms manageable. Discuss short-term and long-term prognoses for victims of this disorder. Does it cause permanent change to the body and how? Discuss known risk factors for this disorder such as age, sex, race, infection, trauma and such.

You will be marking each other's essays (your instructor may also mark the essays and may reserve the right to override any marks that they feel are unjustified based on their own review of the essays). The purpose of this part of the exercise is to expose you to each other's writing so that you can help each other improve and see styles that might provide you with ideas for your own writing. An even more important component of this marking is to expose you to additional research on diseases and disorders than your own paper. You will each mark two other papers from the class. A marking guide is provided on the following pages.

Note that this is an essay rather than a lab report. You should follow the rules for citing and referencing in the accompanying appendix, but the essay will not have the sections of a lab report.

Potential essay topics (get approval before choosing a topic from this list or other topics):

1. Down Syndrome
2. Cystic fibrosis
3. Neurofibromatosis
4. Duchenne muscular dystrophy
5. Multiple sclerosis
6. Sickle cell anaemia
7. Endometriosis
8. Atherosclerosis
9. Macular degeneration
10. Asbestosis
11. Emphysema
12. Rheumatoid Arthritis
13. Frostbite
14. Gout
15. Filariasis
16. Type 2 diabetes mellitus
17. Alcoholic cirrhosis
18. Systemic lupus erythematosus
19. Poliomyelitis
20. Severe combined immunodeficiencies (SCID)
21. Glioblastoma
22. Hepatitis B
23. Kaposi sarcoma
24. Peptic ulcers
25. Basal cell carcinoma
26. Cushing's syndrome
27. Parkinson disease
28. Glaucoma
29. Tinnitus
30. Alzheimer's disease
31. Amyotrophic lateral sclerosis (ALS)
32. Myasthenia gravis
33. Spina bifida
34. Tuberous sclerosis
35. Graves' disease
36. Pernicious anaemia
37. Burkitt lymphoma
38. Myocardial ischemia
39. Mitral valve prolapse
40. Tetralogy of Fallot
41. Kidney stones
42. Tay-Sachs disorder

Marking Guide for Pathology Research Essay

General Information (30)

For each of the following topics give marks as follows: outstanding (5), good (4), average (3.5), pass (2.5), inadequate (2), not good (1), missing (0). Refer to the earlier description of topics to help judge the content of this section.

General description of pathology	
Underlying causes of disorder including risk factors	
Short term symptoms and effects of disorder	
Long term effects of disorder	
Treatment (if any) for disorder or symptoms of disorder	
Interactions with other conditions	

Style (8)

Give marks as described below. Take off extra marks for poorly written material or any evidence of copying, plagiarism

4 marks: 1 mark each for correct grammar, spelling, length, good organisation of material	
2 marks for appropriate language (their own words – not merely repeating material from references)	
2 marks for overall presentation and appearance	

References (12)

Citations in essay (3). All information cited (3), half information cited (1.5), very little cited (0.5), no citations (0)	
Citation format as in handout (2). Take off 0.5 for each minor error such as spelling, underlining, etc., -1 for major errors such as mistakes in names, dates.	
All references in list at end of essay are cited in essay (1). Take off 0.5 for each reference not cited.	
All citations in essay are referenced at end of essay (1). Take off 0.5 for each citation not referenced.	
Reference list at end of essay (3). 1 mark per appropriate source. Unrefereed websites, encyclopaedias, etc. do not count toward this material	
References format (2). Take off 0.5 for each minor error such as spelling, underlining, etc., take off 1 for major errors such as mistakes in names, dates.	

Writing A Scientific Report

Scientific reports are brief summaries of what researchers set out to do, how they did it, what they found out, what they thought about what they found out, and how they related their study to the rest of the world.

A scientific report includes the following sections: Cover page, Abstract, Introduction, Materials and Methods, Results, Discussion, Reference List.

1. Cover Page:

Includes:

title of report,
your name,
name(s) of your partner(s),
instructor's name,
course name,
date.

2. Abstract:

An abstract is a brief summary (no more than 200 words) written after you have finished the report. It includes three items:

the purpose,
summary of the method,
and a summary of your results.

3. Introduction:

The introduction includes your purpose, background information, and your hypotheses. State the purpose of your investigation. While writing the purpose keep in mind the questions that drive the investigation. Present background information relevant to the

research topic. Present relevant theory about tested variables and processes. Make sure that key terms are defined. Cite references within your report as described in the accompanying handout.

Develop a hypothesis or hypotheses. A hypothesis is a prediction of the experiment results supported by a rationale linked to the theory. Using a format of "**if**...**then**...**because**…" will ensure that you include all the elements of a good hypothesis. Typically the components will take the following form: "**if** ...independent variable... **then**… dependent variable… because… theory or rationale." For example: "if light levels are increased, then plants will produce more oxygen, because light provides the energy for photosynthesis, a by-product of which is oxygen."

4. Materials and Methods:

Explain to your reader how the experiment was carried out. The reader should be able to repeat the experiment. Materials and Methods should not be copied from the manual. Instead, refer to the experiment protocol in the format suggested in the citation handout. Indicate and describe any changes made to the original protocol (new procedure, omitted section, modification to experimental settings, etc.) If applicable, state any methods by which you analysed your results.

5. Results:

In this section you present your data analysis by using graphs and tables. Present your data in graphs, tables or illustrations, clearly titled and labelled. As a matter of style, titles for tables are presented at the top of the table. Titles for figures go at the bottom. It's arbitrary, certainly, but that is the standard for biological reports. Summarise your results by describing in sentences the trends or main tendency the graph/table/illustration shows (1 or 2 sentences). **If, and only if required**, the complete class data table or "raw data" should be submitted in an Appendix, *not* in the Results section. Avoid any explanation or analysis of your results such as reviewing your hypotheses. This should be kept for your discussion.

6. Discussion:

This is one of the most important sections of your report. Here you get to explain what you have discovered during this experiment and link your observations to what you have learned in class and to the real world. Furthermore, you can elaborate and speculate on hypotheses for future research. Discuss whether or not your results support your experimental hypothesis. If you have more than one hypothesis, discuss them all separately. Relate your results to theory and background information theory. Compare your personal results with the class average and range.

List all known and potential sources of error and discuss how they may have affected your results. Be specific. Human error is not valid as it is too vague a term. Discuss your opinions, ideas, speculations, and questions. Propose ways to improve your study, new hypotheses and new experiments. End your discussion with one or two conclusive sentences which suggest possible improvement of the experiment and/ or suggest new studies. Be creative. New scientific ideas emerge from this section of the report.

7. Reference List:

All the references you used must be cited in your text. Your reader may need to refer to this literature. Therefore, you must list and properly format all the literature used for your lab write up. See the citations handout for information on formatting these references.

Important Tips:

- Write it in the first or second person, active voice (I found this; we discovered that).
- Write concisely in paragraph form (one subject per paragraph).
- Leave letter format margins (3cm).
- Double space your writing.
- Paginate your report
- Type your report and use spell and grammar checks before printing the final version.
- Use one side of the page only
- Always keep a backup copy.

Checklist:

Title Page

☐ title,

☐ your name and partner's name,

☐ instructor name,

☐ course name,

☐ date,

Abstract

You have mentioned in the text your:

☐ Purpose,
☐ Summary of the method,
☐ Summary of your results.

Introduction

☐ purpose statement

☐ Background information

☐ hypotheses

(one hypothesis per dependent variable)

Materials and Methods:

☐ Refer to the materials and methods section of the lab manual.

☐ Indicate any changes to materials and methods.

Results:

☐ One graph / table per experiment.

Each graph / table must have:

☐ a complete, descriptive title,

☐ legend,

☐ axes labelled and reasonably calibrated,

☐ 1-2 sentences briefly describing results indicated by graph.

Discussion:

☐ discuss results as they relate to hypotheses.

☐ discuss results as they relate to theory.

☐ discuss variability of results.

☐ point out sources of mechanical or experimental error, and their effects.

☐ Indicate how the experiment could have been improved.
☐ conclusive sentence(s).

References:

☐ Use suggested format

How to Cite Literature and List References

There are a number of variations on the way to cite literature in scientific publications. For this course, use the following protocols, which are based on the **Harvard** style. This approach is the most common style for scientific reporting. Another common style used is the Vancouver style, which is even more concise.

Note that in scientific reporting, MLA and APA styles are **NOT** typically used. Those styles are usually found only in fields of the humanities or some of the social sciences. Harvard Style is similar to APA (which came after Harvard and was based on the Harvard style).

There are a few major differences between humanities-style citations and those in science. First, in scientific reporting, the source of material is given typically by citing the author of the work and the year that work was published (Author, Year). Second, direct quotes are extremely rare in science. Instead, material is paraphrased, but the source of the information is provided. Third, footnotes are even rarer than direct quotes. Basically, they aren't seen in scientific reports.

Citing Literature

In all written reports, you **MUST** provide the source of your information for any idea that is not your own original work. Every time you provide descriptions of structures, functions or any other material that you did not think of for the very first time, you must credit the person or work from which you obtained the material. The good news is that crediting the source of information is a simple process. All that is required to cite any published work is to add the name of the author and the year the work was published right in the sentence where you use their ideas. This applies to written material and to pictorial information.

Be sure that when you use information from other researchers, that you do not use their words verbatim. In science, direct copying of words is not considered legitimate even if the source is cited. Copying material without putting it in your own words is **plagiarism** and carries heavy penalties. For this course, plagiarism will result in a failing grade for the assignment, and may carry more serious penalties up to expulsion from the college. This can be easily avoided by citing the author properly, and by using their ideas but not their words. Some excellent information on plagiarism, citing and paraphrasing can be found at www.plagiarism.org (iParadigms, October 8, 2003, electronic communication).

There are a very few situations where direct quotes can occur. Basically, they should only be used if the exact wording of the original material is critical to convey some aspect of the

material, such as a famous phrase or passage. Otherwise, put the material in your own words. Do not quote material just because you like the way the author put something or because you don't want to bother rewriting it. For our purposes, direct quotes are very rare. Check with your instructor if you think you need to quote something directly.

Citation Formats

If you are citing a work with a single author, the simplest way to handle the citation is to end the sentence with the citation including the author and the year of publication:

> The plasma membrane consists of a phospholipid bilayer with embedded proteins (Saladin, 2007).

Alternatively, you can incorporate the citation directly into the sentence:

> Saladin (2007) describes the plasma membrane as a phospholipid bilayer with embedded proteins.

If the work has two authors list both, citing the senior author first, that is the author whose name appears first on the book or journal article:

> The cell membrane consists of a phospholipid bilayer with various proteins projecting through, known as intrinsic proteins (Raven and Johnson, 2002).

For works with more than two authors, just list the senior author, followed by *et al.* This is a Latin term, short for et alia, which literally means and all the others. Note that *et al.* should be in italic font for the citation, or underlined if you do not have a word processor that produces italic font.

> The phospholipid bilayer is an important component of the cell membrane (Campbell *et al.,* 2003).

If you are citing multiple publications written by the same author in the same year, differentiate them by labelling them with a letter. The first one that you cite will include an "a" after the year and the second one a "b" and so on. Make sure that your references section also includes these notations so that readers can tell which work you mean.

> The amygdala is involved in emotional regulation (Ray *et al*., 1987a). The development of the amygdala can be affected by prolonged exposure to stress factors (Ray *et al*., 1987b).

> The semipalmated sandpiper is a scarce migrant through western British Columbia (Kaufman, 2000a).

For written publications where the author is unknown, list a corporate entity or organisation if you know them, or use anonymous if you do not.

> There are five species of the pacific salmon, genus *Onchorhynchus*, found in the lower mainland of British Columbia (Department of Fisheries and Oceans, 1998).

> Cardiac muscle is easily damaged by prolonged restriction of blood flow through the coronary arteries (Anonymous, 2006).

Refereed websites, that is electronic journal articles or electronic editions of books, should be cited just as you would a hardcopy publication.

If you are citing **unrefereed** websites the approach to crediting them differs, since websites can change so easily. For these sources, it is important to include the day that you accessed the information, so that readers of your report will be aware of the potential for change, and can track down what information was available at the time you referenced this material. You don't need to put the **access date** into the main body of the text, but must include it in the information about the citation that you include **in your reference list**. If you do not know the author of the page, include the corporate entity that put the information on the web, or cite it as anonymous, if there is no indication of authorship:

> Using other people's words, without crediting them, is considered plagiarism (I Paradigms, 2017).

> Many people have tried to determine the meaning of life (Anonymous, 2017).

Note that for both of the citations of online sources above, the reference list information for that citation would include the date when you accessed or viewed the website.

When citing material, you should always check with the original material if you can. Using secondary citations (ones where you cite a source that you have only seen as a source in another paper) is dangerous as the citation you are reading may not accurately reflect the content and intentions of the original authors. If you have no other option but to use a secondary citation, make sure it is made clear that this is the case.

> There is not necessarily a link between high biodiversity and high environmental quality (Livingston, 1975, cited in Green, 1979).

Creating A References Section

Throughout your report, you have provided information about the works you have referenced by providing the author and year. These citations don't provide a reader with enough information to find the original material. The references section provides a more detailed set of information for each work you cited in your report. Note that a references section is different from a bibliography that would include every article you looked at. Scientific reports **only** list the material that you actually used **and cited** in writing your report.

The references section should be a single list in alphabetic order. Each entry should be single spaced, with the first line flush to the left-hand margin and subsequent lines in each entry indented. A blank line should be left between entries. The examples that follow show you what this format looks like.

When referencing a book, include (in order), the complete list of authors, the year of publication, the title of the book, the publisher of the book and the city in which it was published. The list of authors should be in the same order that you found them on the title page of the book. Do not use et al. or other shortcuts in the reference list. You must provide the **full list of authors** here, no matter how long. Put the surname of the author first, followed by their initials (for our purposes, use just the initials and not the full first name). The title of the book should be italicized, or underlined if you are not using a word processor with italic fonts. Electronic editions of books follow the exact same format as their hard copy equivalents.

Saladin, K.S. 2004. *Anatomy and Physiology: The Unity of Form and Function, 3rd edition.* McGraw-Hill, Boston.

Seeley, R.R., Stephens, T.D., and Tate, P. 2003. *Anatomy and Physiology, 6th Edition*. McGraw-Hill, New York.

Journal articles should have a similar format but now you must include the title of the article (this does not get put into italics) as well as the **full title** of the journal (italicized). Along with

the title of the journal you should include the **volume number and page numbers** for the article you are referencing. Note that in the following reference, the Latin name for a species is also italicized.

Zanette, L. and Ratcliffe, L.M. 1994. Social rank influences conspicuous behaviour of black-capped chickadees, *Parus atricapillus*. *Animal Behaviour* 48: 119 – 127.

Electronic versions of journal articles have citations identical to regular journal articles unless they are **only** available online. In the case of articles that are only available online you should include the URL for the article and the date that you accessed it.

Han, S.O. and New, P.B. 1998. Variation in nitrogen fixing ability among natural isolates of *Azospirillum*. *Microbial Ecology* 36: 193 – 201. http://link.springer.delink/service/journals/00248/papers/36n2p193.html. Accessed September 15, 2003.

Unrefereed internet articles are always difficult. Provide as much information as you can from the following: author's name (if known), date of publication or last revision, title of document, title of complete work (if relevant), URL, date of access. If you don't know the author's name, use a corporate name if possible, or anonymous, otherwise.

Anonymous. 2003 October 8. *WRZL Weblog*. http://www.meaningofthelife.com. Accessed October 8, 2003

Mitra Biology Resources on the Web. 2012. *Histology.* http://biology.mitrasites.com/histology.html. Accessed June 4, 2012.

Another situation you are likely to run into is a chapter in an edited book. These groups of articles by different authors are fairly common scientific publications. Cite and reference them using the chapter authors as the prime reference.

Straley, G.B. and Douglas, G.W. 1994. Rare and endangered vascular plants – an update. In: Harding, L.E. and McCullum, E., editors. *Biodiversity in British Columbia: Our Changing Environment.* Environment Canada, Ottawa.

Here is what a reference list might look like using the references above:

<u>References</u>

Anonymous. 2003 October 8. *WRZL Weblog*. http://www.meaningofthelife.com. Accessed October 8, 2003

Han, S.O. and New, P.B. 1998. Variation in nitrogen fixing ability among natural isolates of *Azospirillum*. *Microbial Ecology* 36: 193 – 201. http://link.springer.delink/service/ journals/00248/papers/36n2p193.html. Accessed September 15, 2003.

Mitra Biology Resources on the Web. 2012. *Histology.* http://biology.mitrasites.com/histology.html. Accessed June 4, 2012.

Saladin, K.S. 2004. *Anatomy and Physiology: The Unity of Form and Function, 3rd edition.* McGraw-Hill, Boston.

Seeley, R.R., Stephens, T.D., and Tate, P. 2003. *Anatomy and Physiology, 6th Edition*. McGraw-Hill, New York.

Straley, G.B. and Douglas, G.W. 1994. Rare and endangered vascular plants – an update. In: Harding, L.E. and McCullum, E., editors. *Biodiversity in British Columbia: Our Changing Environment.* Environment Canada, Ottawa.

Zanette, L. and Ratcliffe, L.M. 1994. Social rank influences conspicuous behaviour of black-capped chickadees, *Parus atricapillus*. *Animal Behaviour* 48: 119 – 127.

Other situations may arise than the ones I have described here. If you are unsure, check with your instructor, or ask one of the librarians for help. Be sure to let them know you are writing a scientific report using the Harvard style, as the styles differ for other publications. One item I have not dealt with in this section is the use of personal communications. Generally, you should avoid them in favour of published material.

As a final note, you should know that there are many variations on the Harvard style. Each journal and publisher will use a slightly different version. One journal might separate each component of a citation by periods, while others might use semi-colons. One might put journal page numbers in parentheses, while others do not. This is common in all citation styles. For your assignments for this course, use the format shown here, rather than other variations.

Biology 1120 Learning Objectives – Chemistry, Cytology, Histology, Orientation

Define the following terms and give example(s) of groups where they are found:

axial	appendicular	supine
prone	anatomical position	viscera
isotope	pH	oxidation
reduction	triglyceride	dehydration synthesis
hydrolysis	anion	cation
polymer	monomer	fusiform
matrix	ground substance	osmotic pressure
chaperone	ATP	prokaryote
dominant	recessive	codominant
pleiotropy	sex-linkage	polygenic
incomplete dominance	autosome	sex chromosome
heterozygous	homozygous	tissue
differentiation	atrophy	necrosis

1. Contrast anatomy and physiology.
2. Describe similarities and differences among the 3 major sectional planes.
3. Provide at least 5 examples of opposing directional terms for anatomical orientation. Explain each pair.
4. Discuss hierarchical organization of structure in biology and give examples of structures at different level (e.g., cells, tissues, systems).
5. Discuss means by which humans maintain homeostasis. How do humans differ from some other organisms in their approach to homeostasis?
6. Compare the quadrant and region approaches to abdominal orientation? What are the boundaries between the quadrants and regions?
7. Describe terminology for anatomical location ranging from cephalic to plantar regions.
8. Describe the major body cavities and give examples of the structures found in them, including important membranes.
9. List eleven major organ systems in humans.
10. Contrast atoms, ions and molecules.
11. Describe major types of chemical bonds and the differences among them.

12. Discuss the octet rule and its importance to chemistry.
13. Discuss the importance of polar and hydrophobic structures to biological processes.
14. Describe the basic organization and structure of carbohydrates. Provide examples of each class of carbohydrate and their uses in living organisms.
15. Describe the basic organization and structure of lipids, proteins and nucleic acids. Provide examples of each class of these substances and their uses in living organisms.
16. Discuss the cell theory.
17. Describe the major functions cells must carry out in order to survive, then discuss the ways that cellular organelles and components fulfill these requirements.
18. Discuss the structure and function of the plasma membrane.
19. Contrast diffusion and osmosis.
20. Contrast selectively permeable and semipermeable.
21. Discuss major modes of membrane transport including energy expenditures and gradient impacts
22. Describe the organization of DNA and RNA in eukaryotic cells including the roles that each play in cell function.
23. Discuss differences in function among the three major categories of RNA and their use in protein synthesis.
24. Describe the process of cell division.
25. Discuss the characteristics and importance of the genetic code.
26. Contrast genes, alleles and traits.
27. Contrast inheritance and expression with penetrance.
28. Describe the basic principles of Mendelian genetics.
29. Discuss non-Mendelian effects and their relationship to basic genetics.
30. Contrast genotypes and phenotypes.
31. For each of the tissue types and subtypes describe major characteristics, functions, locations in the body, and important relationships with other tissue types.
32. Contrast simple, stratified and pseudostratified.
33. Contrast exocrine and endocrine glands.
34. Describe the 3 major structural types of exocrine glands.
35. Describe 3 different methods of exocrine secretion.
36. List the components and describe the functions of the 4 major types of membranes found in the body.

Biology 1120 Learning Objectives – Nervous System and Senses

Define the following terms and give example(s) of groups where they are found:

cell body	neurilemma	dendrite
axon	mesencephalon	prosencephalon
rhombencephalon	metencephalon	diencephalon
telencephalon	myelencephalon	decussation
ganglion	salutatory	refractory
regeneration tube	anion	cation
monoamine	excitatory	inhibitory
neuromodulator	fasciculus	ramus
commissure	afferent	efferent
soma	ventricle	habituation
facilitation	gyrus	sulcus
electroencephalogram	neuropeptide	REM sleep
pituitary gland	pineal gland	modality
spinal gating	rhodopsin	hemidecussation

1. Compare and contrast the structure and function of the three functional categories of neurons.
2. Describe the structure and function of the six types of glial cells, including their location within the nervous system.
3. Describe the biochemical processes involved in the generation and propagation of an action potential including the importance of the different stages of an excitation event. How and why does myelination affect this process?
4. Describe the arrangement and functions of the meninges.
5. Describe the anatomical and functional divisions of the nervous system, including the sympathetic and parasympathetic systems, as well as the enteric nervous system.
6. Contrast the anatomy (structure and location) and physiology (function and regulation) of grey matter and white matter.
7. Discuss major categories of psychotropic (mind affecting) drugs and their activity in the nervous system.
8. Describe the processes and structures involved in synaptic transmission.
9. Contrast axonal transmission and synaptic transmission including consideration of summation and integration versus the all-or-none law.
10. Compare and contrast the different types of chemical synapses
11. Contrast electrical and chemical synapses. Where is each found and what are their advantages and disadvantages?

12. Compare the four major types of neuronal circuits.
13. Describe the role of neuronal circuits in memory.
14. Compare and contrast short term and long-term memory in terms of the processes involved and the purpose of memory in behavioural functioning (daily life).
15. Provide examples from each of the four major categories of neurotransmitters.
16. Contrast the different means by which neurotransmitters are removed from the synaptic cleft.
17. Describe the process of presynaptic inhibition. What role does this process play in neural functioning?
18. Describe the anatomy of the spinal cord.
19. Contrast the roles and structure of descending and ascending tracts in the nervous system.
20. Describe the anatomy of a nerve including associated tissues.
21. Describe the arrangement of the spinal nerves, including important plexuses.
22. Discuss the role of reflexes. What are the characteristics of a reflex?
23. Describe the role of cerebrospinal fluid. How and where is it produced?
24. Describe the anatomy and physiology of the major components of the brain, including cerebral lobes.
25. Discuss the components and role of the reticular formation and the reticular activating system. How are these items related?
26. Identify important anatomical landmarks on the surface and in the interior of the brain.
27. Discuss the interrelationships of components of the brain. How would damage to one component affect other brain structures?
28. Discuss the role of the limbic system.
29. Discuss the function of sleep paralysis.
30. Discuss the physiology of higher brain functions such as emotions, cognition and language.
31. Discuss the importance of cerebral asymmetry and lateralisation.
32. Identify the twelve cranial nerves and describe their functions.
33. Describe the main categories of sensory receptors (using stimulus type and origin and receptor location).
34. Contrast tonic and phasic receptors.
35. Contrast sensory reception and sensory perception.
36. Describe the anatomical structures and physiological processes involved in the special senses.
37. Describe neural processing within the eye.
38. Describe common problems in vision and ways we can correct for them.
39. Contrast the roles of the different photoreceptors.
40. Describe the generation of stereoscopic vision.
41. List 5 senses other than the special senses.
42. Contrast taste and smell.
43. Describe problems in hearing and how we can correct for them.
44. Contrast hearing and equilibrium in terms of the structures involved and the role of the two related processes

Biology 1120 Learning Objectives – Endocrine System, Reproduction and Development

Define the following terms and give example(s) of groups where they are found:

hormone	pheromone	target structure
paracrine signalling	second messenger	protein kinase
enzyme cascade	eicosanoid	Mullerian ducts
gamete	zygote	GNRH
gonad	sustentacular cell	cremaster muscle
dartos muscle	P.I.D.	tunica albuginea
tunica vaginalis	broad ligament	mesosalpinx
pap smear	Mullerian Inhibiting Factor	gubernaculum
vas deferens	endometrium	myometrium
clitoris	prepuce	vestibule
capacitation	polar body	fertilization membrane
morula	blastula	foetus
ectopic pregnancy	organogenesis	congenital abnormality

1. Discuss the source, target, effects and regulation for the hormones of the endocrine system.
2. Describe the two predominant mechanisms of action for hormones. Which hormones use each of these mechanisms? What are the major classes of hormones?
3. Contrast the 3 main methods of endocrine regulation (neural signalling, feedback loops and antagonistic control).
4. Describe neuroendocrine reflexes.
5. Describe the anatomy and physiology of the hypothalamus and pituitary.
6. Describe several endocrine disorders.
7. Contrast endocrine and exocrine gland structure and function.
8. Describe the embryonic development and differentiation of the male and female reproductive systems.
9. Contrast the processes of spermatogenesis and spermiogenesis with oogenesis. Include the organs involved, the time frames required and the hormonal regulation.
10. Describe the anatomy and physiology of the testes and the ovaries. Compare the function of the testicular interstitial cells and the ovarian follicle cells.
11. Describe the accessory structures of the male and female reproductive systems.

12. Describe the processes and structures involved in the female menstrual cycle. What factors can influence the normal functioning of this cycle?
13. Describe the role of the uterus and predictable structural and functional changes in this organ related to normal menstrual cycling versus pregnancy and childbirth.
14. Discuss the differing roles played by sperm in fertilization and sperm competition.
15. Describe the components of semen including their purposes and their sources.
16. Describe the processes involved in male and female puberty.
17. Contrast meiosis in male and female gamete production.
18. Describe the physiological processes in intercourse.
19. Describe the structure of the sperm and the roles of the components.
20. Describe thermal regulation in the scrotal sac.
21. Describe the anatomy and physiology of the breasts.
22. Discuss menopause.
23. Describe the hormonal processes involved in pregnancy and childbirth.
24. Describe labour and childbirth.
25. Prepare a timetable of human prenatal development.
26. Discuss the following aspects of development: fertilization, cleavage, gastrulation, morphogenesis, differentiation, induction, growth, tissue specialization, senescence, death.
27. List the primary germ layers and their fate in development of adult structures.
28. Describe the structure of an embryo and its associated structures at the blastula stage.
29. Describe the structure and function of the human placenta.
30. Discuss the function and fates of the extraembryonic membranes.
31. Discuss theories of senescence.

Biology 1220 Learning Objectives – Integumentary, Muscular and Skeletal Systems

Define the following terms and give example(s) of groups where they are found:

fasciculus	fibre	sarcolemma
sarcoplasmic reticulum	sarcomere	tubule system
acetylcholinesterase	motor unit	tone
twitch	treppe	tetanus
tendon	ligament	aponeurosis
periosteum	lacunae	canaliculi
medullary cavity	nutrient foramina	epiphysis
epiphyseal plate	articular cartilage	diaphysis
endosteum	Sharpey fibres	unipennate
bipennate	multipennate	fusiform
digastric	deltoid	parallel
convergent	circular	teres
bicipital	belly	trabeculae
canaliculus	lacuna	scoliosis
sesamoid	bursa	meniscus

1. Describe the layers of the skin and discuss the functional importance of the layers.
2. Contrast the differing shapes and modes of secretion for glands.
3. Describe the structure of hair and contrast the different physiological types of hair.
4. Describe the structure of nails.
5. Describe the hierarchical organisation of a muscle (i.e., fasciculi, fibres, etc.) including the types of membranes surrounding the differing muscle layers.
6. Discuss the relationship between the visible appearance of skeletal muscle tissue and the underlying cellular structure of muscle fibres. Include the anatomical and physiological meaning of the different bands and zones visible under a microscope.
7. Describe the fine structure events at the cellular and biochemical level that produce skeletal muscle contraction.
8. Contrast skeletal muscle contraction with that found in cardiac and smooth muscle.
9. Describe the process by which motor signals are passed to muscle tissue.
10. Contrast the structure and function of red and white muscle fibres.

11. Describe the functions, locations, insertions and origins of the muscles from the muscle lab.
12. Compare the three classes of levers.
13. Describe the different categories of movements and actions of both muscles and bones.
14. Contrast the structure and function of spongy bone and compact bone.
15. Contrast the roles of osteogenic cells, osteocytes, osteoblasts and osteoclasts.
16. Describe the four basic bone shapes.
17. Contrast red and yellow bone marrow.
18. Describe the structure and function of the different components of a long bone.
19. Discuss similarities and differences between intramembranous and endochondral ossification.
20. Discuss ectopic ossification.
21. Describe how a broken bone heals.
22. Discuss the regulation of bone remodelling including the hormones and other factors involved.
23. Distinguish between the axial and appendicular skeleton.
24. Describe the types of joints, both in terms of their structures and their actions.
25. Describe the bones and joints from the lists in your skeletal structure lab.
26. Describe the anatomy and physiology of a synovial joint.

Biology 1220 Learning Objectives – Respiratory, Cardiovascular and Lymphatic Systems, Immunity

Define/describe/identify:

immunoglobulin	haematocrit	buffy coat	antigen
complement	antibiotic	inflammation	bile pigments
Purkinje fibres	pacemaker	sinoatrial node	intrinsic
respiratory pigment	heme	foetal haemoglobin	vitamin K
portal vein	elastic fibres	anaemia	arteriosclerosis
diastole	systole	epiglottis	atherosclerosis
larynx	tidal volume	residual volume	cilia
pulmonary	diffusion	diaphragm	negative pressure
bicarbonate	aldosterone	angiotensin	plasma proteins
osmotic pressure	electrolyte	albumin	megakaryocytoblast
haemopoiesis	agglutination	conjugated bilirubin	myocardial infarction
bundle of His	stroke volume	cardiac output	varicosity
transcytosis	edema	cisterna chyli	dendritic cells
phagocytosis	perforins	complement	hyperemia
diapedesis	interleukin	MHC	anaphylaxis

1. Trace the flow of air from the environment to absorption by the blood, describing the roles of the structures along this route.
2. List the four steps in respiration from the external environment to use of oxygen for energy.
3. Explain negative pressure. How is it created and what role does it play in respiration?
4. Explain how CO_2 and O_2 are exchanged in the lungs and tissues and transported in the blood.
5. Explain why mouth to mouth resuscitation works, including a discussion of respiratory efficiency.
6. Discuss the importance of the differing respiratory volumes in rest and exercise.
7. Describe the feedback systems for regulating respiratory rates.
8. Discuss the processes of pulmonary ventilation.
9. Discuss the functions of the respiratory and circulatory systems.

10. Trace the path of blood from a chamber of the heart to an extremity and back to the same chamber of the heart.
11. Name the major arteries and veins and describe their locations and functions.
12. Describe the structure of arteries, veins, capillaries and lymph vessels. Discuss the contribution of each to circulation and the role that their structures play in fulfilling this role.
13. Explain the significance of the numbers obtained during a blood pressure reading and the cause of the sounds heard with a stethoscope. How is blood pressure regulated?
14. Describe the cardiac cycle.
15. Explain the origin of the heartbeat and describe the factors that can change the heart rate.
16. Explain how blood is returned to the heart.
17. Describe the process of signal transmission in cardiac muscle tissue and contrast this with transmission in neurons and other forms of muscle.
18. Label a diagram of the heart and describe its structure, including the roles of valves, muscles and internal support structures.
19. Describe the factors measured by an electrocardiogram.
20. Describe blood:
    a. Cells - morphology, functions, proportions and origins.
    b. Plasma - constituents, functions and proportions.
    c. Platelets – origins and role in clotting mechanisms.
21. Describe erythropoiesis and the recycling of haemoglobin.
22. Discuss blood typing and the importance of blood groups.
23. Discuss blood pathologies, including their causes, symptoms and histological diagnosis.
24. Describe the structure and organisation of the lymphatic system.
25. Describe the constituents of lymph and tissue fluids.
26. Discuss a generalised immune response in terms of the stages and structures involved.
27. Contrast the roles of the differing types of T cells in the immune response.
28. Explain how B cells are activated and produce antibodies against specific antigens.
29. Describe the causes and effects of allergies, tissue rejection, autoimmune disorders and immunodeficiencies.
30. Distinguish between active and passive immunity.
31. Discuss vaccines, their differences and their role in disease prevention.
32. Describe the process of cell-mediated immunity and contrast it with humoral immunity.
33. Explain how antibodies react with antigens and the fate of the antibody-antigen complex.

Biology 1220 Learning Objectives – Digestion, Nutrition, Metabolism, Excretion and Homeostasis

Explain the following terms:

cristae	oxidative phosphorylation	electron carriers
potential energy	kinetic energy	vitamin
osmosis	essential	basal metabolic rate
body mass index	atrial natriuretic peptide	erythropoietin
basal metabolic rate	trace minerals	co-enzyme
chief cell	villus	mesentery
microvillus	appendix	caecum
bile pigments	glycogen	blood sugar
deamination	detoxification	urea
bile	bile salts	plasma protein
bicarbonate	ADH	dialysis
glomerulus	Bowman's capsule	Loop of Henle
active transport	renin	angiotensin
aldosterone	vitamin K	portal vein
hiatus	enteric nervous system	peritoneum
lacteal	chylomicron	crypts of Lieberkühn
Meissner's plexus	plexus of Auerbach	pharyngeal arches
sphincter	appendix	gluconeogenesis
transamination	dialysis	buffer systems
micturition	vermiform appendix	uvula

1. Describe the structure and function of the 4 layers in the digestive tract and how these layers differ throughout the tract.
2. Describe the structure, function, specialization and development of teeth.
3. Discuss functions and specializations of the salivary glands.
4. Describe the process of swallowing.
5. Describe the anatomy and roles of the stomach in digestion and regulation of digestion.
6. Discuss the specializations of the stomach that compensate for HCl presence.
7. Describe the duodenal contents in terms of sources and functions.

8. Describe peristalsis and the regulation of the movement of substances through the digestive tract.
9. Describe the pH changes that occur during digestion and their importance.
10. Describe the structure and at least 9 functions of the liver.
11. List the enzymes and other substances involved in the digestive process.
12. Contrast the functions of the small and large intestines, including specializations of the subsections of each of the two intestinal types.
13. Describe the formation and components of feces.
14. Describe differences in absorption and transport for the major nutrient types.
15. Discuss metabolism of the major nutrient types.
16. Discuss the physiology of hunger and starvation.
17. Discuss bacterial digestion and its importance to human digestion.
18. Discuss fluid production and absorption in the digestive tract.
19. Describe several high-energy molecules produced in cell energetic reactions.
20. Describe the raw materials and end products of cell respiration.
21. Compare and contrast aerobic and anaerobic cellular respiration in terms of energy produced, products used and resulting, and role in living organisms.
22. Briefly describe how ATP is synthesized in cell energetics (the chemiosmotic pump).
23. Describe the stages of cell respiration (glycolysis, transition reaction, Krebs cycle, electron transport chain).
24. Describe the different effects for nutrition of simple and complex carbohydrates, saturated and unsaturated fatty acids.
25. Describe several diseases of nutritional deficiencies.
26. Discuss the effects and risks of over- and under-nutrition.
27. Describe the roles and sources of water-soluble and fat-soluble vitamins.
28. Contrast calories, Calories, kilocalories and kilojoules.
29. State the uses for several minerals in the diet.
30. Describe the parts of the excretory system.
31. Discuss the role of hormones and other regulatory mechanisms in kidney function and the body's chemical homeostasis.
32. Describe the anatomy of the kidney and bladder.
33. Describe the main functions of the nephron.
34. Describe urine formation, including the importance of osmotic and other gradients.
35. Contrast cortical and juxtamedullary nephrons.
36. Contrast the structure and roles of the proximal and distal convoluted tubules.
37. Discuss diuretics.
38. Discuss regulation of fluid balance, electrolyte levels and pH in the body.
39. Describe acidosis and alkalosis.

Biology 1120/1220

Laboratory Safety: Guidelines and Procedures

General Principles:

The lab is a busy space which is often crowded. Anything that causes distraction, impairs movement or can spill or fall can produce a dangerous situation. We all need to work to minimise these dangers.

1. Keep the aisles and edges of the tables clear. Put **bags and books** under the tables or well back from the edges. Try not to block the aisles with chairs or equipment. **Power cords** should not dangle across passageways or hang down to the ground.

2. Food and drink do not mix with chemicals, preservatives and electronics. Whenever a lab is occurring you must **put away any food or drink**.

3. **Keep your workspace clean** and tidy. Scrambled gear is dangerous but can also result in incorrect procedures and bad data. Spilled materials can be hazardous. The benches should be clean before you start and you should clean them at the end of the lab exercise.

4. **Follow the instructions** provided by your instructors and lab demonstrators. They are the experts in the procedures we will use so follow their instructions. The lab is not a place to try to wing it and hope for the best.

5. Avoid distractions. **Cell phones, tablets and computers** that are not directly required for laboratory procedures should be turned off during the lab.

Safety Equipment:

All the labs are equipped with **eyewash stations**. While proper procedures should mean you will never need to use these, if an accident happens, and you need to flush chemicals out of your eyes, place your face so that your eyes are bathed by the faucets. Keep your eyes under the streams of water for a full five minutes for mildly irritating materials and at least 20 minutes for moderate to severe irritants.

Decontamination showers are located in room 3275 and 3252. The flushing times when using these are the same as for the eyewash stations.

Fire extinguishers are also in all labs. Make sure you know their location.

Gloves may be worn for dissections and some chemical procedures. Nitrile gloves are available in the labs and do not produce allergic reactions, like the older latex gloves, so are safe to use at any time. Gloves **must** be worn whenever human materials (blood or urine or other tissues) are being used, to prevent any possible spread of harmful pathogens.

Safety Glasses must be worn for chemistry procedures and dissections to prevent any possible eye damage. Students with prescription glasses should choose glasses or goggles that can be worn over their own glasses. Prescription eyeglasses alone are not adequate protection. You will be required to bring your own safety glasses to class. They are available for a reasonable price from the bookstore.

Safety Procedures for Human Tissues (Blood, Urine or Epithelial Cells)

Handle any human tissues with care as they can transmit infectious diseases.

All students using human blood must wear examination gloves and safety glasses.

If you have any open cuts on your hands, or other body locations that could come in contact with human blood or other tissues and materials, do not handle blood or urine.

Carry out your work on paper towels or other protective coverings such as dental bibs, to avoid spilling materials on the bench.

If you spill any products wipe them up immediately with the cleaners identified by the laboratory personnel and rinse with tap water.

At the end of the lab:

Wipe your bench and your microscope to remove any stains.

Place any contaminated materials in the appropriate biohazard waste receptacles.

Remove your gloves and glasses and wash your hands.

Do's and Don'ts for the Lab

Do:

Wear safety garb such as safety glasses and or gloves whenever directed to by lab personnel.

Wear clothing that provides adequate protection: sandals and open-toed shoes are not a good choice for lab activities.

Know where safety equipment and emergency exits are located.

Prepare for the labs ahead of time. Reading through procedures early will ensure that you know what you are doing and reduce confusion and the risk of accidents.

Exercise caution when working with chemicals or sharp materials.

Keep your workstations clean and tidy to reduce the risk of spills or accidents.

Use common sense. Think things through before you act.

Don't:

Eat or drink when labs are underway.

Taste or place any materials we work with in your mouth (even for the food lab).

Pour any materials down the sinks without permission.

Use any equipment until you have been shown how to operate it safely.

Leave hot materials unattended.